Subacute combined degeneration of the spinal cord in vitamin B_{12} and copper deficiency

Rainer Schimana, Heinz Ober, Oliver Neuhaus

Department of Neurology, SRH Kliniken Landkreis Sigmaringen GmbH, Sigmaringen, Germany

Correspondence to
Dr Oliver Neuhaus, o.neuhaus@klksig.de

Accepted 7 December 2017

DESCRIPTION

A 67-year-old man with a medical history of pancreatoduodenectomy (Whipple procedure) in September 2015 due to a pancreatic cancer was admitted to our department of neurology 1 year later with a progressively disturbed gait. He reported weakness and numbness of both legs. Clinical examination revealed a spastic sensomotoric tetraparesis with ataxia and bladder dysfunction. MRI showed longitudinal myelopathy exactly limited to the posterior tracts (fasciculus gracilis and fasciculus cuneatus) indicating a metabolic origin (subacute combined degeneration of the spinal cord; figure 1A,B).

Consistently and according to the medical history of the Whipple procedure, a moderate vitamin B_{12} deficiency (274 ng/L, reference value 210–910 ng/L) was detected with respective decrease in holotranscobalamin (18 pmol/L, reference value >50 pmol/L) and increase in methylmalonic acid (99.9 ng/mL, reference value 9–32 ng/mL). A mild anaemia was detected with a haemoglobin level of 12.5 g/dL. Parenteral vitamin B_{12} substitution was initiated, normalising the laboratory data.

Unexpectedly, the clinical state deteriorated rapidly within few weeks. This clinical observation was confirmed by MRI showing progressive myelopathy still limited to the posterior tracts but longitudinally extending from the dens tip to the inferior cervical cord (figure 1C). Brain MRI was normal. Further investigation revealed a severe copper deficiency probably due to the previous upper gastrointestinal surgery (serum copper level 0.3 µg/mL, reference value 0.7–1.5 µg/mL). The caeruloplasmin level was accordingly decreased (7 mg/dL, reference value 20–60 mg/dL). The patient has been using a zinc-containing denture adhesive in a dosage of at least 50 mg weekly for 10 years. The serum zinc level was elevated (23.7 µmol/L, reference value 11.1–19.5 µmol/L). The copper deficiency may also be induced by the use of denture cream.[1] Furthermore, there was a drug history of high-dose proton pump inhibitors over 2 years.[2] Other potential causes of copper deficiency such as Wilson's disease, alcoholism or Menkes disease were excluded.

Motor electroneurography was normal. However, a severe sensory polyneuropathy was detected; electromyography could not be done because of lack of cooperation. The somatosensory-evoked potentials were significantly delayed both in arms and legs; under vitamin B_{12} and copper substitution therapy they improved.

Although under substitution the myelopathy remained stable in MRI, the patient subsequently lost the ability to walk. A third look did not show other reasons for the deterioration.

The precise pathophysiology of copper deficiency-induced myelopathy is unclear. It has been hypothesised that oxidative damage as a result of diminished superoxide dismutase activity leads to demyelination and axonal degeneration in the central nervous system.[3]

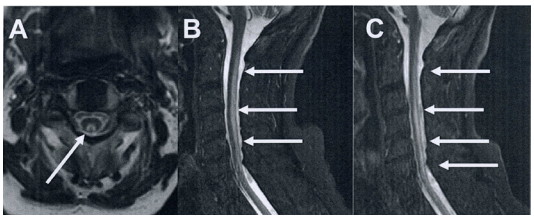

Figure 1 (A) Axial T2-weighted and (B) sagittal short T1 inversion recovery (STIR) MRI of the cervical spine showing longitudinal myelopathy exactly limited to the posterior tracts (fasciculus gracilis and fasciculus cuneatus, arrows). (C) Sagittal STIR MRI of the cervical spine 4 months later.

Learning points

- Common cause of posterior tract myelopathy is subacute combined degeneration of the spinal cord induced by vitamin B_{12} deficiency.
- Occasionally, copper deficiency can also cause posterior tract myelopathy.
- Upper gastrointestinal surgery can be responsible for both deficiencies.
- Zinc-containing denture adhesives or high-dose proton pump inhibitor intake can cause copper deficiency.
- Both vitamin B_{12} deficiency and copper deficiency can be treated by respective substitutions.

Contributors All authors were involved in clinical care and investigative workup of the patient. RS conceived and designed the study, developed and wrote the manuscript. HO and ON revised the manuscript for intellectual content.

Competing interests None declared.

Patient consent Obtained.

Provenance and peer review Not commissioned; externally peer reviewed.

© BMJ Publishing Group Ltd (unless otherwise stated in the text of the article) 2017. All rights reserved. No commercial use is permitted unless otherwise expressly granted.

To cite: Schimana R, Ober H, Neuhaus O. *BMJ Case Rep* Published Online First: [*please include* Day Month Year]. doi:10.1136/bcr-2017-222446

BMJ Case Reports: first published as 10.1136/bcr-2017-222446 on 20 December 2017. Downloaded from http://casereports.bmj.com/ on 20 April 2024 by guest. Protected by copyright.

REFERENCES

1 Doherty K, Connor M, Cruickshank R. Zinc-containing denture adhesive: a potential source of excess zinc resulting in copper deficiency myelopathy. *Br Dent J* 2011;210:523–5.
2 Plantone D, Renna R, Primiano G, *et al*. PPIs as possible risk factor for copper deficiency myelopathy. *J Neurol Sci* 2015;349:258–9.
3 Jaiser SR, Winston GP. Copper deficiency myelopathy. *J Neurol* 2010;257:869–81.

Copyright 2017 BMJ Publishing Group. All rights reserved. For permission to reuse any of this content visit http://group.bmj.com/group/rights-licensing/permissions.
BMJ Case Report Fellows may re-use this article for personal use and teaching without any further permission.

Become a Fellow of BMJ Case Reports today and you can:
- Submit as many cases as you like
- Enjoy fast sympathetic peer review and rapid publication of accepted articles
- Access all the published articles
- Re-use any of the published material for personal use and teaching without further permission

For information on Institutional Fellowships contact consortiasales@bmjgroup.com

Visit casereports.bmj.com for more articles like this and to become a Fellow

BMJ Case Reports: first published as 10.1136/bcr-2017-222446 on 20 December 2017. Downloaded from http://casereports.bmj.com/ on 20 April 2024 by guest. Protected by copyright.