

## CASE REPORT

## An airway traffic jam: a plastic traffic cone masquerading as bronchial carcinoma

Nicholas Denny,<sup>1</sup> Usman Maqsood,<sup>2</sup> Stephen Fowler,<sup>1</sup> Mohammed Munavvar<sup>2</sup>

<sup>1</sup>Department of Respiratory Medicine, Wythenshawe Hospital, Manchester, UK  
<sup>2</sup>Department of Respiratory Medicine, Royal Preston Hospital, Preston, UK

**Correspondence to**  
 Dr Nicholas Denny,  
 scat3660@doctors.org.uk

Accepted 23 August 2017

**SUMMARY**

Tracheobronchial foreign body (TFB) aspiration is a common occurrence in children compared with adults. Long-standing cases of TFB aspiration during childhood presenting in an adult have rarely been reported. We report the unique case of an endobronchial Playmobil traffic cone that went undetected for 40 years and presented as a suspected bronchogenic carcinoma. This was subsequently removed successfully with flexible bronchoscopy. To our knowledge this is the first case of a TFB that was overlooked this length of time.

**BACKGROUND**

Tracheobronchial foreign body (TFB) aspiration is a common occurrence in children compared with adults but the diagnosis is less likely to be delayed.<sup>1</sup> This may be because of parental attention and because TFBs often obstruct proximal airways in children leading to more identifiable choking symptoms.<sup>1</sup> However, smaller radiolucent foreign bodies may be overlooked in children due to misdiagnosis or as they are initially asymptomatic.<sup>2</sup>

Undiagnosed TFB can mimic a number of conditions in children including recurrent croup and asthma and cause others such as bronchiectasis and pneumonia.<sup>2-3</sup> In adults, overlooked TFB aspiration can occasionally mimic a bronchogenic carcinoma.<sup>4-6</sup> Long-standing cases of TFB aspiration for more than 20 years have rarely been reported<sup>4-7-9</sup> but in only one of these did TFB aspiration occur in childhood.<sup>8</sup>

We report the unique case of an endobronchial Playmobil traffic cone that went undetected for 40 years and presented as a suspected bronchogenic carcinoma. To our knowledge this is the first reported case of a TFB that was overlooked for 40 years.

**CASE PRESENTATION**

A 47-year-old handyman was referred to our respiratory clinic with a yearlong history of a cough productive of white-yellow sputum and malaise. Two months prior he had been diagnosed with right-sided community acquired pneumonia and his symptoms had improved following a course of amoxicillin and clarithromycin. He was an ex-smoker with a 30 pack-year history and had no known asbestos exposure. On examination there was no clubbing, lymphadenopathy or wasting.

Chest examination revealed slightly reduced air entry globally but no added sounds.

**INVESTIGATIONS**

Biochemical analyses were within normal limits and spirometry demonstrated a mild restrictive deficit. A chest X-ray showed consolidation in the right lower zone with a right pleural effusion (figure 1). In light of the persistent consolidation and smoking history, a contrast-enhanced CT chest was carried out. This demonstrated patchy dense consolidation in the right middle and lower lobes, considerable volume loss, bronchiectasis in the right lower lobe and associated pleural thickening (figure 2).

Significant subcarinal, right hilar and paratracheal lymphadenopathy was noted. Appearances were suggestive of malignancy and therefore an urgent bronchoscopy was arranged. White light bronchoscopy identified a mustard coloured foreign body in the apical segment of the right lower lobe with surrounding inflammation. There was no other evidence of endobronchial disease and bronchial washings were negative for neoplastic cells and showed no significant growth.

**DIFFERENTIAL DIAGNOSIS**

The main differential diagnoses in this case of persistent right lower lobe pneumonia were malignant obstruction, foreign body or other benign obstructing pathology, recurrent silent aspiration or antibiotic resistance.

**TREATMENT**

Our centre in Preston has extensive experience in the use of flexible bronchoscopy under conscious sedation. Originally, because the cause of the bronchial obstruction was not clear, flexible bronchoscopy under conscious sedation was carried out with diagnostic intent. A foreign body partially obstructing the right lower lobe bronchus was identified and was successfully removed with biopsy forceps. On closer inspection, this turned out to be a traffic cone from a Playmobil set (figure 3). Had this not been successful, a rigid bronchoscopy would have been carried out.

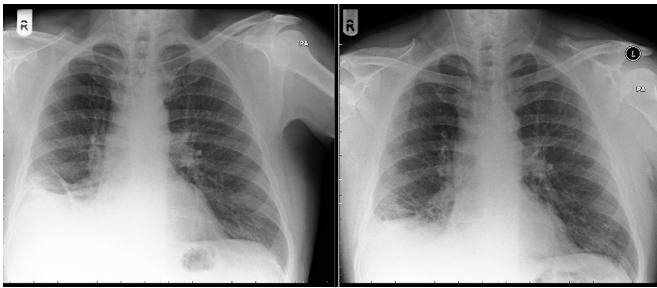
**OUTCOME AND FOLLOW-UP**

Following the procedure, the patient reported that he regularly played with and even swallowed pieces of Playmobil during his childhood. He recalled being given this Playmobil set for his seventh birthday and believes he aspirated the toy traffic cone soon after. Four months after removal of the tiny traffic cone, his productive cough had almost entirely settled and a chest X-ray only showed minor



CrossMark

**To cite:** Denny N, Maqsood U, Fowler S, et al. *BMJ Case Rep* Published Online First: [please include Day Month Year]. doi:10.1136/bcr-2017-220514

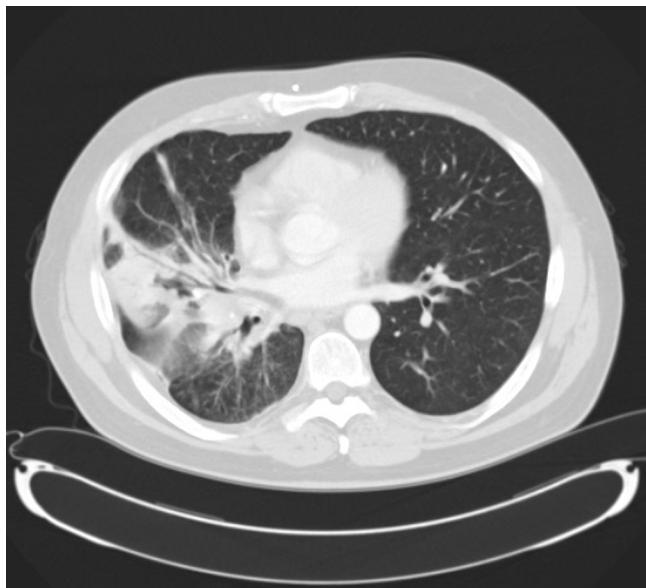

**Figure 1** Chest X-rays 2 weeks before and 4 months after removal of the toy cone.

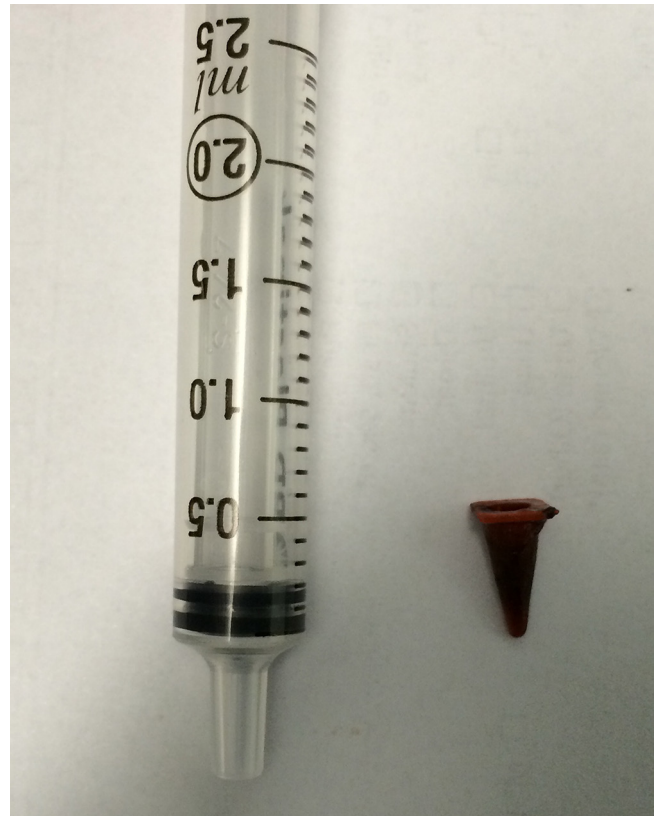
residual consolidation (figure 1). After removal our patient still had residual focal bronchiectasis but this can occur in approximately 20% of patients with a chronic TFB.<sup>2</sup> On a positive note, his symptoms improved markedly and he finally found his long-lost Playmobil traffic cone in the very last place he would look.

**DISCUSSION**

The diagnosis of TFB in children appears to be delayed for more than 1 week in a small but significant proportion of children.<sup>1,2</sup> However, a case in which the onset of symptoms occurs so long after initial aspiration is unheard of in the literature. In our case, the chronic cough and persistent right lower zone consolidation raised concerns about a proximal obstructing mass; most likely a bronchogenic carcinoma with our patient’s history of smoking. Yet this obstruction had not caused any symptoms until the preceding year. This may be because aspiration occurred at such a young age that the patient’s airway was able to remodel and adapt to the presence of this foreign body. For example, during childhood it may have been absorbed into the mucosal lining of the bronchus which developed around it. Subsequently, the cumulative effect of smoking and infection later in adulthood, led to right middle and lower lobe obstruction that presented as persistent consolidation. Therefore, any obstructive pathology caused by the cone may only have presented over a relatively short period, prior to which it



**Figure 2** Axial slice of contrast-enhanced CT chest showing middle and right lower lobe consolidation.



**Figure 3** Toy cone from a child's play set compared with a 2.5 mL syringe to illustrate size.

was clinically silent. Approximately 1%–5% of bronchoscopies for atypical chronic respiratory symptoms in children find a hitherto undetected TFB.<sup>2,10</sup> There are a number of reasons for a TFB to remain undiagnosed in a child, including asymptomatic aspiration, normal examination, normal chest X-ray and misdiagnosis.

Several case series have found that a normal examination and normal chest X-ray occur in less than 10% of cases.<sup>1,11</sup> Therefore, it is unusual for a symptomatic TFB to be overlooked in a child and, in the 1% of undetected cases, the median delay in diagnosis is only 3 months.<sup>2</sup> Only one reported case had remained undetected for more than 20 years.<sup>8</sup> In contrast, TFBs are more frequently overlooked in adults leading to a longer delay in diagnosis<sup>1</sup> and three cases of a delay of more than 20 years have been

**Learning points**

- ▶ It is unusual that such a long-standing foreign body failed to stimulate a stronger local inflammatory reaction but we believe this failure to mount a response to the Playmobil cone contributed to the long asymptomatic period experienced by our patient.
- ▶ In most long-standing cases, inflammation and granulation tissue encase the tracheobronchial foreign body.<sup>7,8</sup> As a result, removal of these foreign bodies required rigid bronchoscopy or lobectomy.
- ▶ In contrast, in our case, flexible bronchoscopy and biopsy forceps were sufficient to extract the plastic toy cone. Flexible bronchoscopy is now the first line option for investigation and removal of such objects.<sup>12,13</sup>

reported.<sup>4 7 9</sup> Therefore, our patient is unique in enduring a TFB for more than 40 years and because this event occurred when he was only 7 years old.

**Contributors** ND, SF and MM planned and drafted the article, UM obtained consent and ND, UM, SF and MM were involved in the critical revision and approval of the final version to be published.

**Competing interests** None declared.

**Patient consent** Obtained.

**Provenance and peer review** Not commissioned; externally peer reviewed.

© BMJ Publishing Group Ltd (unless otherwise stated in the text of the article) 2017. All rights reserved. No commercial use is permitted unless otherwise expressly granted.

## REFERENCES

- 1 Baharloo F, Veyckemans F, Francis C, *et al.* Tracheobronchial foreign bodies: presentation and management in children and adults. *Chest* 1999;115:1357–62.
- 2 Karakoc F, Cakir E, Ersu R, *et al.* Late diagnosis of foreign body aspiration in children with chronic respiratory symptoms. *Int J Pediatr Otorhinolaryngol* 2007;71:241–6.
- 3 Maguire A, Gopalakaje S, Eastham K. All that wheezes is not asthma: a 6-year-old with foreign body aspiration and no suggestive history. *BMJ Case Rep* 2012;2012:bcr2012006640.
- 4 Debeljak A, Sorli J, Music E, *et al.* Bronchoscopic removal of foreign bodies in adults: experience with 62 patients from 1974–1998. *Eur Respir J* 1999;14:792–5.
- 5 Jawad A, Majid A, Maskey A, *et al.* Pill aspiration presenting as an endobronchial tumor. *J Bronchology Interv Pulmonol* 2014;21:162–5.
- 6 Ripley DP, Henderson AK. A case of bronchial aspiration: the importance of early diagnosis and clinical suspicion. *Prim Care Resp J* 2007;16:191–3.
- 7 Kogure Y, Oki M, Saka H. Endobronchial foreign body removed by rigid bronchoscopy after 39 years. *Interact Cardiovasc Thorac Surg* 2010;11:866–8.
- 8 Kamiyoshihara M, Ibe T, Takeyoshi I. Inhaled foreign body overlooked for 25 years in an adult. *Gen Thorac Cardiovasc Surg* 2008;56:191–4.
- 9 Al-Majed SA, Ashour M, Al-Mobeireek AF, *et al.* Overlooked inhaled foreign bodies: late sequelae and the likelihood of recovery. *Respir Med* 1997;91:293–6.
- 10 Wood RE, Gauderer MW. Flexible fiberoptic bronchoscopy in the management of tracheobronchial foreign bodies in children: the value of a combined approach with open tube bronchoscopy. *J Pediatr Surg* 1984;19:693–8.
- 11 Boufersaoui A, Smati L, Benhalla KN, *et al.* Foreign body aspiration in children: experience from 2624 patients. *Int J Pediatr Otorhinolaryngol* 2013;77:1683–8.
- 12 Ramos MB, Fernández-Villar A, Rivo JE, *et al.* Extraction of airway foreign bodies in adults: experience from 1987–2008. *Interact Cardiovasc Thorac Surg* 2009;9:402–5.
- 13 Mise K, Jurcev Savicevic A, Pavlov N, *et al.* Removal of tracheobronchial foreign bodies in adults using flexible bronchoscopy: experience 1995–2006. *Surg Endosc* 2009;23:1360–4.

Copyright 2017 BMJ Publishing Group. All rights reserved. For permission to reuse any of this content visit <http://group.bmj.com/group/rights-licensing/permissions>.

BMJ Case Report Fellows may re-use this article for personal use and teaching without any further permission.

Become a Fellow of BMJ Case Reports today and you can:

- ▶ Submit as many cases as you like
- ▶ Enjoy fast sympathetic peer review and rapid publication of accepted articles
- ▶ Access all the published articles
- ▶ Re-use any of the published material for personal use and teaching without further permission

For information on Institutional Fellowships contact [consortiasales@bmjgroup.com](mailto:consortiasales@bmjgroup.com)

Visit [casereports.bmj.com](http://casereports.bmj.com) for more articles like this and to become a Fellow