



OPEN ACCESS

## CASE REPORT

# Regression of a glioblastoma multiforme: spontaneous versus a potential antineoplastic effect of dexamethasone and levetiracetam

Prakash Peddi,<sup>1</sup> Nisha Elizabeth Ajit,<sup>2</sup> Gary Von Burton,<sup>3</sup> Hazem El-Osta<sup>1</sup>

<sup>1</sup>Louisiana State University Health Sciences Center Shreveport School of Medicine, Shreveport, Louisiana, USA  
<sup>2</sup>Department of Internal Medicine, Louisiana State University Health Sciences Center Shreveport School of Medicine, Shreveport, Louisiana, USA

<sup>3</sup>Department of Hematology and Oncology, Louisiana State University Health Sciences Center Shreveport School of Medicine, Shreveport, Louisiana, USA

**Correspondence to**

Dr Prakash Peddi,  
ppeddi@lsuhsc.edu

Accepted 4 December 2016

**SUMMARY**

Patients with grade IV astrocytoma or glioblastoma multiforme (GBM) have a median survival of <12 months, increased to 14.6 months by maximal safe resection with radiation and temozolamide. In the absence of chemotherapy, radiotherapy or chemoradiotherapy, spontaneous regression of GBM or regression while only being on dexamethasone (DEX) and levetiracetam (LEV) have seldom been reported. Here, we present a case of a patient who had significant regression of the GBM with DEX and LEV alone. In this study, we hypothesise a plausible antineoplastic role of DEX and/or LEV in GBM and highlight molecular, preclinical and clinical studies supporting this role.

**BACKGROUND**

Patient with GBM has a poor prognosis despite aggressive therapy. This case describes an outlier in the survival curve, doing well currently. A detailed insight into his story offers us plausible explanations for the regression of this tumour. Spontaneous regression of the tumour versus a combined antineoplastic effect of antiepileptic drugs (AEDs) and dexamethasone (DEX) are the leading hypothesis. This case reviews preclinical and retrospective data, which support our hypothesis, and also emphasizes that further clinical studies are a prerequisite for validation and for developing treatment protocols in a tumour with a poor prognosis.

**CASE PRESENTATION**

A 55-year-old man was admitted on March 2014 for acute-onset lethargy and confusion. His medical history includes biopsy-proven right frontal lobe grade II astrocytoma, diagnosed in April 2000. After undergoing definite radiation, he achieved a long-term remission. In May 2009, MRI of the brain demonstrated a new heterogeneous mass in the right frontal and temporal lobe with minimal mass effect over right anterior horn. As the patient declined surgery, he was empirically treated with oral temozolamide (TMZ) at 150 mg/m<sup>2</sup> (days 1–5 and repeated every 28 days) from August 2009 to December 2011. As patient stopped taking TMZ secondary to fatigue, he was kept on observation until January 2013. In January 2013, MRI of the brain (figure 1A) revealed new findings concerning for glioblastoma multiforme (GBM). Patient declined surgery again and was lost to follow-up

until March 2014, when he presented with this acute clinical presentation.

MRI of the brain revealed a large bi-frontal solid expansive mass with vasogenic oedema (figure 1B). Patient was immediately started on intravenous DEX (4 mg intravenously every 6 hours for 7 days followed by oral dosing of 4 mg two times per day) and levetiracetam (LEV) 500 mg orally two times per day for seizure prophylaxis. Brain biopsy revealed anaplastic fibrillar astrocytes with high mitosis and infiltrating into the adjacent brain parenchyma with associated satellitosis and with large areas of necrosis. Patient was diagnosed with WHO grade IV astrocytoma or GBM (figure 1C). Over the next 2-month period, patient's cognition gradually improved with resolution of delirium and speech problems, while he remained on oral DEX and LEV. Brain MRI on day 57 revealed mild improvement (figure 1D). On day 99, brain MRI showed further reduction of frontal, parasagittal mass size (figure 1E). On day 120, he was started on concurrent TMZ and radiation followed by the maintenance of TMZ. At the time of writing this manuscript, patient continues to do well with brain MRI showing no signs of recurrence (figure 1F).

**DISCUSSION**

GBM is the most aggressive and lethal primary brain tumour and carries a dismal prognosis.<sup>1 2</sup> Maximal safe resection followed by adjuvant concurrent chemoradiotherapy with oral TMZ remains the treatment of choice.<sup>3</sup> While rare cases of long-term survival with GBM have been described,<sup>4</sup> spontaneous regression in GBM setting has never been published. Continuous regression of GBM was noted in our patient while on DEX and LEV, without any cancer-targeted therapy, suggesting that the response may be secondary to DEX and/or LEV.

DEX's inherent role in altering the natural course of GBM by itself or in congruence with chemotherapy and radiation is unknown.<sup>5</sup> In contrary, high-dose DEX (>4.1 mg/day) was proposed to mitigate the effects of chemotherapy resulting in lower overall survival (OS) in patients with GBM.<sup>6</sup>

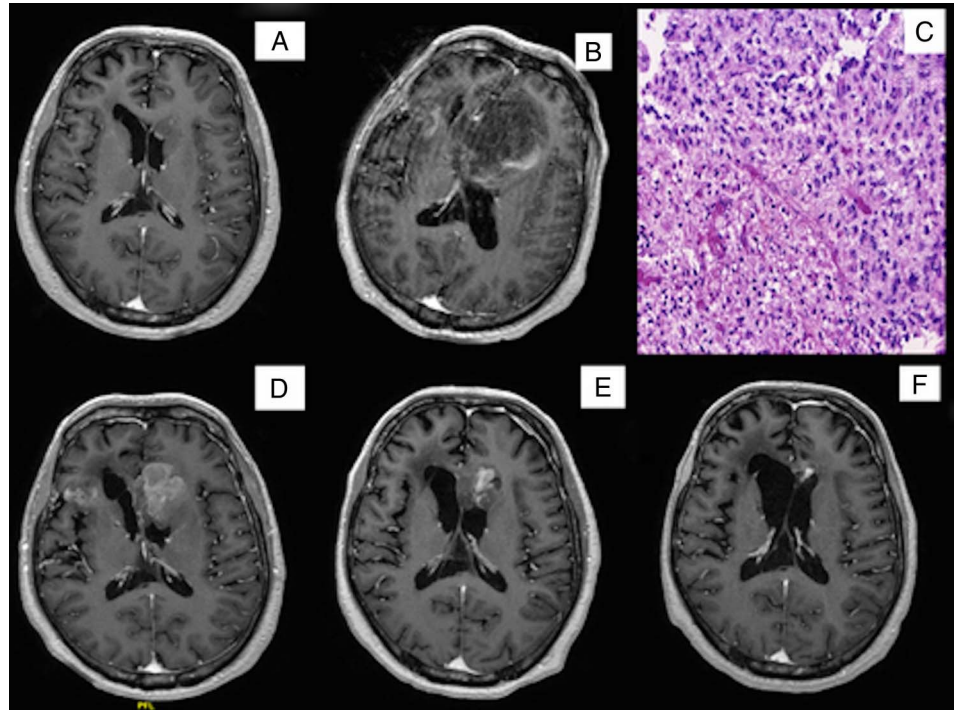
Most of the understanding of DEX antineoplastic effects in GBM comes from in vitro studies. Takahashi *et al*<sup>7</sup> demonstrated that DEX inhibits adrenomedullin (AM) induced by inflammatory cytokines interferon- $\gamma$ , tumour necrosis factor- $\alpha$  and interleukin-1 in human GBM cell line T98G. Hypoxia and inflammatory cytokines induce AM, which in turn increases vascular endothelial growth



CrossMark

**To cite:** Peddi P, Ajit NE, Burton GV, *et al*. *BMJ Case Rep* Published online: [please include Day Month Year] doi:10.1136/bcr-2016-217393

**Figure 1** (A) MRI brain T1 with contrast demonstrating features concerning for GBM. (B) MRI brain T1 with contrast demonstrating a large bi-frontal solid expansive mass with vasogenic oedema. (C) H&E staining of frontal lobe mass from (B) showing WHO grade IV astrocytoma. (D and E) MRI brain T1 with contrast at days 57 and 99 demonstrating a decrease in size of frontal and parasagittal mass. (F) MRI brain T1 day 810 reveals further improvement in the lesions. GBM, glioblastoma multiforme.



**Table 1** Pertinent findings of molecular profiling of the recurrent tumour performed by Caris Molecular Intelligence (CARIS)

Test	Method	Result
BRCA 1	NGS	Exon 3/E33K; mutated variant of unknown significance
BRCA2	NGS	Exon 17/A263v; mutated variant of unknown significance
ERCC1	IHC	Negative
IDH1	NGS	Mutated Exon 4/R132H
MGMT	Pyro Seq	Methylated
1p19q	FISH	Positive
FGFR1	NGS	Mutated, variant of unknown significance; Exon 4 E126K
FGFR2	NGS	Mutation negative
PD-L1	IHC	Negative
TP53	NGS	Mutated; Exon 8/P2785
EGFR	NGS	Mutation negative
EGFR VIII	FA	Absent
NRAS/KRAS/HRAS	NGS	Mutation negative
Her2/Neu (ERBB2)	NGS	Mutation negative
PIK3CA	NGS	Mutation negative

EGFR, epithelial growth factor receptor; ERBB, epidermal growth factor receptor; ERCC, excision repair cross-complementing; FGFR, fibroblast growth factor receptor; FA, Fragment Analysis; FISH, fluorescence in situ hybridization; IDH, isocitrate dehydrogenase; IHC, Immunohistochemistry; MGMT, O<sup>6</sup> methylguanine-DNA methyltransferase; NGS, Next-Generation sequencing; NRAS/KRAS/HRAS, N-rat sarcoma gene; K-rat sarcoma gene; H-rat sarcoma gene; PD-L1, programmed death ligand 1; PIK3CA, Phosphoinositide 3-kinase oncogene; TP53, tumour protein 53.

factor (VEGF) production.<sup>8–11</sup> Increased VEGF worsens the vicious cycle of more hypoxia and more AM, thereby potentiating angiogenesis, tumour proliferation, invasion and metastasis.<sup>7 12</sup> Along with above mechanisms, DEX, via the

glucocorticoid receptor pathway, is shown to directly inhibit VEGF production in glioblastoma cells.<sup>13</sup> There is also growing body of evidence that DEX inhibits glioma cell proliferation in vitro and tumour growth in vivo.<sup>4</sup> Its capability to inhibit neural stem cells by decreasing cyclin D1 level has been also demonstrated.<sup>14–16</sup>

Inhibition of migration and invasion in various glioma cell lines (C6, U251, U373 and A172) by DEX has been shown by Bauman *et al.*<sup>17</sup> In U87MG glioma cells, DEX reduces matrix metalloproteinase-2 secretion and thereby tumour invasion.<sup>18</sup> DEX direct cytotoxic effect on glioblastoma cell lines (A172, T98G and 86HG39) has been described.<sup>11</sup>

Recent preclinical and clinical studies elucidating antitumorous efficacy of AEDs in brain tumours demonstrate encouraging results. Valproic acid (VPA) was shown to cause growth arrest and apoptosis in medulloblastoma cell lines by regulating expression of p21Cip1, cyclin-dependent Kinase 4 (CDK4) and *c-myc* proteins through histone hyperacetylation.<sup>19</sup> Van Nifterik *et al.*<sup>20</sup> demonstrated increased cytotoxicity in human glioma cells subjected to TMZ and  $\gamma$ -radiation in the presence of VPA. Data from EORTC 26981-22981 and NCIC CE.3 clinical trial database have revealed that the OS of patients who were receiving VPA alone appeared to increase survival benefit from TMZ and radiation compared to those who were on enzyme-inducing AEDs only (HR: 0.39, 95% CI 0.24 to 0.63) or those not receiving any AED (HR: 0.67, 95% CI 0.49 to 0.93).<sup>21</sup>

On the other hand, Bobustuc *et al.*<sup>22</sup> demonstrated that LEV increased histone deacetylase 1 (HDAC1) transcription and recruited HDAC1/mSin3A compressor complex to the p53-binding site in the O<sup>6</sup> methylguanine-DNA methyltransferase (MGMT) promoter, consequently silencing MGMT and enhancing the anticancer effects of TMZ. In a single institutional retrospective study, Kim *et al.*<sup>23</sup> noticed that the median progression-free survival (PFS) and OS for patients who received LEV in combination with TMZ was significantly prolonged compared to those who did not receive LEV (PFS 9.4 vs 6.7 months,  $p=0.010$ ; OS 25.7 vs 16.7 months,  $p=0.027$ ).

Tumour molecular profiling using Caris Life Sciences (Phoenix, Arizona, USA) revealed a deficiency of the DNA repair system at multiple levels (table 1): BRCA1/2 mutation, along with MGMT gene silencing by methylation, isocitrate dehydrogenase 1 (IDH1) mutation and 1p/19q codeletion, known for their correlation with improved sensitivity to chemotherapy and other genotoxic stress, were present. It is possible that the impaired DNA repair system has conferred an improved sensitivity to DEX and LEV. This observation needs to be proven through cell lines model harbouring defect at different levels in their DNA repair system and from large clinical database. Although DEX and LEV's role in GBM regression is supported by few preclinical and retrospective clinical data, randomised clinical trials are still lacking. Further efforts are needed to define the antineoplastic role of DEX and LEV in GBM.

### Learning points

- ▶ Secondary glioblastoma multiforme (GBM) progress from astrocytoma and have a better prognosis than primary GBM.
- ▶ Patients with tumours having O<sup>6</sup> methylguanine-DNA methyltransferase promoter methylation respond better to alkylating agents such as temozolamide, translating to longer survival.
- ▶ Dexamethasone and levetiracetam have been shown in in vitro studies and retrospective studies to play a role in directly inhibiting tumour proliferation and increasing sensitivity to chemotherapy.
- ▶ Randomised control trials can validate the role of antiepileptic drugs and dexamethasone in the treatment of GBM

**Contributors** PP and NEA conceived and designed the manuscript, and also drafted the manuscript.

**Competing interests** None declared.

**Patient consent** Obtained.

**Provenance and peer review** Not commissioned; externally peer reviewed.

**Open Access** This is an Open Access article distributed in accordance with the Creative Commons Attribution Non Commercial (CC BY-NC 4.0) license, which permits others to distribute, remix, adapt, build upon this work non-commercially, and license their derivative works on different terms, provided the original work is properly cited and the use is non-commercial. See: <http://creativecommons.org/licenses/by-nc/4.0/>

### REFERENCES

- 1 Holland EC. Glioblastoma multiforme: the terminator. *Proc Natl Acad Sci USA* 2000;97:6242–4.
- 2 Friedmann-Morvinski D, Bushong EA, Ke E, *et al.* Dedifferentiation of neurons and astrocytes by oncogenes can induce gliomas in mice. *Science* 2012;338:1080–4.
- 3 Stupp R, Hegi ME, Mason WP, *et al.* Effects of radiotherapy with concomitant and adjuvant temozolomide versus radiotherapy alone on survival in glioblastoma in a randomised phase III study: 5-year analysis of the EORTC-NCIC trial. *Lancet Oncol* 2009;10:459–66.
- 4 Piette C, Deprez M, Roger T, *et al.* The dexamethasone-induced inhibition of proliferation, migration, and invasion in glioma cell lines is antagonized by macrophage migration inhibitory factor (MIF) and can be enhanced by specific MIF inhibitors. *J Biol Chem* 2009;284:32483–92.
- 5 Galicich JH, French LA. Use of dexamethasone in the treatment of cerebral edema resulting from brain tumors and brain surgery. *Am Pract Dig Treat* 1961;12:169–74.
- 6 Fukushima S, Narita Y, Miyakita Y, *et al.* A case of more than 20 years survival with glioblastoma, and development of cavernous angioma as a delayed complication of radiotherapy. *Neuropathology* 2013;33:576–81.
- 7 Takahashi K, Udono-Fujimori R, Totsune K, *et al.* Suppression of cytokine-induced expression of adrenomedullin and endothelin-1 by dexamethasone in T98G human glioblastoma cells. *Peptides* 2003;24:1053–62.
- 8 Shweiki D, Itin A, Soffer D, *et al.* Vascular endothelial growth factor induced by hypoxia may mediate hypoxia-initiated angiogenesis. *Nature* 1992;359:843–5.
- 9 Jain RK. Normalizing tumor microenvironment to treat cancer: bench to bedside to biomarkers. *J Clin Oncol* 2013;31:2205–18.
- 10 Bagnato A, Spinella F. Emerging role of endothelin-1 in tumor angiogenesis. *Trends Endocrinol Metab* 2003;14:44–50.
- 11 Kaup B, Schindler I, Knüpfel H, *et al.* Time-dependent inhibition of glioblastoma cell proliferation by dexamethasone. *J Neurooncol* 2001;51:105–10.
- 12 Li F, Yang R, Zhang X, *et al.* Silencing of hypoxia-inducible adrenomedullin using RNA interference attenuates hepatocellular carcinoma cell growth in vivo. *Mol Med Rep* 2014;10:1295–302.
- 13 Heiss JD, Papavassiliou E, Merrill MJ, *et al.* Mechanism of dexamethasone suppression of brain tumor-associated vascular permeability in rats. Involvement of the glucocorticoid receptor and vascular permeability factor. *J Clin Invest* 1996;98:1400–8.
- 14 Sundberg M. Glucocorticoid hormones decrease proliferation of embryonic neural stem cells through ubiquitin-mediated degradation of cyclin D1. *J Neurosci* 2006;26:5402–10.
- 15 Kim JB, Ju JY, Kim JH, *et al.* Dexamethasone inhibits proliferation of adult hippocampal neurogenesis in vivo and in vitro. *Brain Res* 2004;1027:1–10.
- 16 Sabolek M, Herborg A, Schwarz J, *et al.* Dexamethasone blocks astroglial differentiation from neural precursor cells. *Neuroreport* 2006;17:1719–23.
- 17 Bauman GS, MacDonald W, Moore E, *et al.* Effects of radiation on a model of malignant glioma invasion. *J Neurooncol* 1999;44:223–31.
- 18 Lin YM, Jan HJ, Lee CC, *et al.* Dexamethasone reduced invasiveness of human malignant glioblastoma cells through a MAPK phosphatase-1 (MKP-1) dependent mechanism. *Eur J Pharmacol* 2008;593:1–9.
- 19 Li XN. Valproic acid induces growth arrest, apoptosis, and senescence in medulloblastomas by increasing histone hyperacetylation and regulating expression of p21Cip1, CDK4, and CMYC. *Mol Cancer Ther* 2005;4:1912–22.
- 20 Van Nifflerik KA, Van den Berg J, Slotman BJ, *et al.* Valproic acid sensitizes human glioma cells for temozolomide and  $\gamma$ -radiation. *J Neurooncol* 2012;107:61–7.
- 21 Weller M, Gorlia T, Cairncross JG, *et al.* Prolonged survival with valproic acid use in the EORTC/NCIC temozolomide trial for glioblastoma. *Neurology* 2011;77:1156–64.
- 22 Bobustuc GC, Baker CH, Limaye A, *et al.* Levetiracetam enhances p53-mediated MGMT inhibition and sensitizes glioblastoma cells to temozolomide. *Neuro Oncol* 2010;12:917–27.
- 23 Kim YH, Kim T, Joo JD, *et al.* Survival benefit of levetiracetam in patients treated with concomitant chemoradiotherapy and adjuvant chemotherapy with temozolomide for glioblastoma multiforme. *Cancer* 2015;121:2926–32.

Copyright 2016 BMJ Publishing Group. All rights reserved. For permission to reuse any of this content visit <http://group.bmj.com/group/rights-licensing/permissions>.  
BMJ Case Report Fellows may re-use this article for personal use and teaching without any further permission.

Become a Fellow of BMJ Case Reports today and you can:

- ▶ Submit as many cases as you like
- ▶ Enjoy fast sympathetic peer review and rapid publication of accepted articles
- ▶ Access all the published articles
- ▶ Re-use any of the published material for personal use and teaching without further permission

For information on Institutional Fellowships contact [consortiasales@bmjgroup.com](mailto:consortiasales@bmjgroup.com)

Visit [casereports.bmj.com](http://casereports.bmj.com) for more articles like this and to become a Fellow