



EDITOR'S  
CHOICE

# Oral mucosal manifestations of chronic eosinophilic leukaemia with FIP1L1-PDGFR $\alpha$

Kenji Tsuda,<sup>1</sup> Tetsuya Tanimoto,<sup>2</sup> Kazuhito Hayakawa,<sup>1</sup> Tsunehiko Komatsu<sup>1</sup>

<sup>1</sup>Teikyo University Chiba Medical Center, Ichihara, Japan  
<sup>2</sup>Navitas Clinic, Tachikawa, Japan

**Correspondence to**  
Dr Kenji Tsuda,  
thedod3@hotmail.com

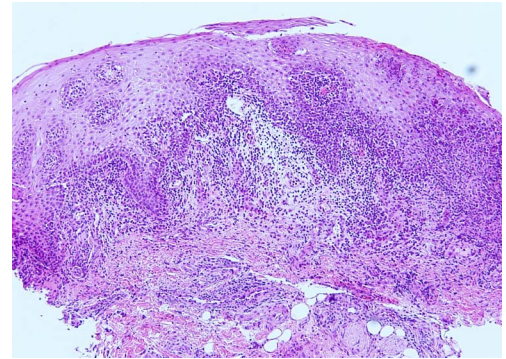
Accepted 28 December 2015

## DESCRIPTION

A 55-year-old man was referred to our dermatology department with a 5-month history of nasal bleeding, crusted erosions on the lips ([figure 1](#)) and painful oral mucosal ulcerations unresponsive to systemic acyclovir therapy prescribed by a family physician. He was unable to swallow due to agonising pain, and lost 20 kg. The patient was initially suspected of paraneoplastic pemphigus (PNP). Histological examination of the lip and oral mucosa showed non-specific mixed cellular infiltrates without predominance of eosinophils and no subepidermal blistering ([figure 2](#)). Direct immunofluorescence revealed C3 deposits at the basement membrane, but indirect immunofluorescence and ELISA for antibodies against envoplakin and periplakin were negative; there was no conclusive evidence of PNP.

The patient was referred to our haematology department because his white cell count (WCC) increased to 65 100/ $\mu$ L with 20% eosinophils. We obtained a positive result of the FIP1L1-PDGFR $\alpha$  fusion gene as a result of a cryptic deletion at 4q12 by fluorescence in situ hybridisation. The patient was diagnosed with chronic eosinophilic leukaemia (CEL) with FIP1L1-PDGFR $\alpha$ . Prednisolone 1 mg/kg was not effective, however, the tyrosine kinase inhibitor, imatinib, normalised the patient's eosinophil count within 3 days. The oral mucosal lesions completely disappeared within 3 weeks.

Aphthous stomatitis is commonly seen in daily clinical practice, but oral ulcers sometimes present as a manifestation of systemic diseases, such as sexually transmitted diseases, Stevens-Jonson



**Figure 2** H&E staining of a biopsy specimen of the lip. The pathological examination showed non-specific mixed cellular infiltrates without predominance of eosinophils and no subepidermal blistering.

syndrome, Behçet's disease and autoimmune bullous dermatoses including PNP. Clinicians should notice that CEL could be an alternative diagnosis in patients with refractory oral mucosal ulcerations. Differentials of WCC and cytogenetic examinations in addition to biopsy are mandatory to initiate imatinib promptly.

## Learning points

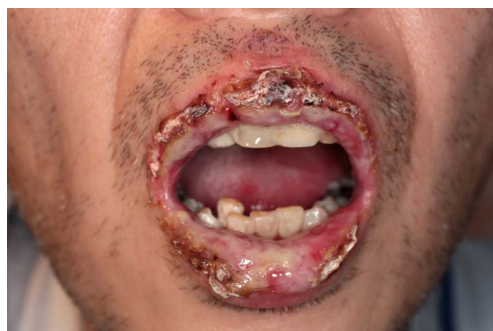- ▶ Chronic eosinophilic leukaemia with FIP1L1-PDGFR $\alpha$  can present with severe oral mucosal ulcerations similar to paraneoplastic pemphigus.
- ▶ Because biopsy of the ulceration is non-specific, differentials of white cell count and cytogenetic examinations are mandatory to differentiate chronic eosinophilic leukaemia with FIP1L1-PDGFR $\alpha$  from other systemic diseases.

**Contributors** KT drafted the article. TT contributed to critical revision of the article. KH and TK approved the article.

**Competing interests** None declared.

**Patient consent** Obtained.

**Provenance and peer review** Not commissioned; externally peer reviewed.



**Figure 1** Crusted erosions on the lips.



CrossMark

**To cite:** Tsuda K, Tanimoto T, Hayakawa K, et al. *BMJ Case Rep* Published online: [please include Day Month Year] doi:10.1136/bcr-2015-213266

Copyright 2016 BMJ Publishing Group. All rights reserved. For permission to reuse any of this content visit <http://group.bmj.com/group/rights-licensing/permissions>.  
BMJ Case Report Fellows may re-use this article for personal use and teaching without any further permission.

Become a Fellow of BMJ Case Reports today and you can:

- ▶ Submit as many cases as you like
- ▶ Enjoy fast sympathetic peer review and rapid publication of accepted articles
- ▶ Access all the published articles
- ▶ Re-use any of the published material for personal use and teaching without further permission

For information on Institutional Fellowships contact [consortiasales@bmjgroup.com](mailto:consortiasales@bmjgroup.com)

Visit [casereports.bmj.com](http://casereports.bmj.com) for more articles like this and to become a Fellow