BMJ Case Reports

Images in...

Non-contiguous spinal tuberculosis

Deepwant Singh, Bhathiya Wijeyekoon

Department of Rheumatology, East and North Herts NHS Trust, Stevenage, Hertfordshire, UK

Correspondence to Dr Bhathiya Wijeyekoon, j.wijeyekoon@nhs.net

DESCRIPTION

A 26-year-old-man of Indian descent was referred to our rheumatology unit with 6 months of lower-back pain. He had lived in the UK for 5 years, travelling intermittently to holiday in India. His general practitioner detected a C-reactive protein of 55 mg/l and erythrocyte sedimentation rate of 95 mm/h and referred with a possible 'spondylo-arthritis'.

The patient gave a history of back pain with stiffness throughout the day. He admitted to fever, sweats and significant weight loss but denied having a cough.

On examination, he had slight limitation of lumbar-spine-flexion with no focal spinal-tenderness or clinical-sacroilitis. Straight-leg-raise was 80° bilaterally. Resisted hip-flexion caused exacerbation of lower-back pain. Power and knee-jerks were normal but ankle-jerks were reduced.

Chest-radiograph (figure 1) was normal and lumbar-spine x-ray (figure 2) revealed a fifth lumbar-spine pars-defect only. Renal, liver and bone profile was normal. Three early-morning-urine samples, blood cultures and HIV-serology were negative.

Fevers, sweats, weight loss and reduced ankle-jerks are considered atypical for a spondylo-arthritis. Malignancy or indolent spinal infection form important differential diagnoses. An urgent MRI-spine (figure 3) revealed multiple spinal-lesions and a para-spinal-abscess eroding the sacrum. Subsequent CT demonstrated a left sixth-rib-lesion, the biopsy and histology of which revealed non-caseous-granulomas and negative acid-fast-bacilli stain. Culture of this specimen yielded *Mycobacterium tuberculosis* after 4 weeks.

About 23% of patients with spinal-tuberculosis (TB) may have normal spinal-plain-radiographs.[1] Our case highlights the need for early spinal MRI in patients with suspected spinal TB, even when plain radiographs appear normal. TB-spondylitis frequently involves multiple-adjacent spinal-vertebrae; non-contiguous vertebral involvement, as seen here, is relatively uncommon.[2] Confusion with metastatic malignancy is possible; hence a tissue diagnosis is still essential.[2]

Figure 1 Chest radiograph was normal with no focal parenchymal lung pathology.

Figure 2 Lumbar spine x-ray demonstrating a fifth lumbar spine pars defect (white arrow).

BMJ Case Reports: first published as 10.1136/bcr-2012-007382 on 9 November 2012. Downloaded from http://casereports.bmj.com/ on 19 April 2024 by guest. Protected by copyright.

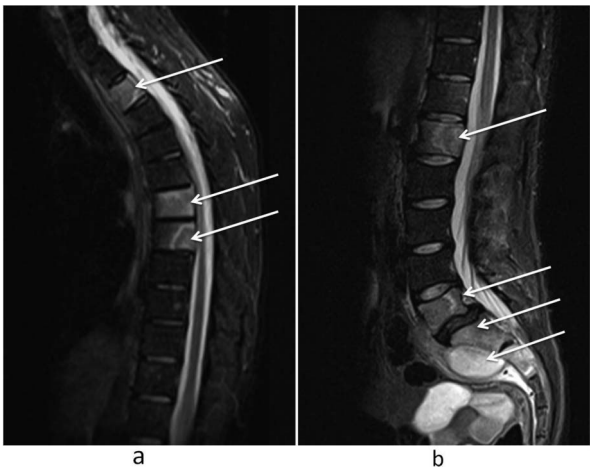

Figure 3 Sagittal MRI view of (A) thoraco-lumbar spine, (B) lumbo-sacral spine, demonstrating contiguous and non-contiguous spinal lesions as well as a 5.8×3.7 cm presacral abscess (white arrows).

Learning points

- In suspected cases of spinal tuberculosis (TB), early spinal imaging with MR is required, even if plain radiographs appear normal.
- A tissue diagnosis should be obtained whenever possible to exclude other pathologies (malignancy/infection) and to determine sensitivity to antituberculous treatment.
- Non-contiguous TB spondylitis is relatively uncommon but can be present even when plain radiographs appear normal, thus emphasising the need to MRI the whole spine.

Competing interests None.

Patient consent Obtained.

REFERENCES

1. **Owolabi LF**, Nagoda MM, Samaila AA, *et al*. Spinal tuberculosis in adults: a study of 87 cases in Northwestern Nigeria. *Neurol Asia* 2010;**15**:239–44.
2. **Polley P**, Dunn R. Noncontiguous spinal tuberculosis: incidence and management. *Eur Spine J* 2009;**18**:1096–101.

Copyright 2012 BMJ Publishing Group. All rights reserved. For permission to reuse any of this content visit http://group.bmj.com/group/rights-licensing/permissions.
BMJ Case Report Fellows may re-use this article for personal use and teaching without any further permission.

Please cite this article as follows (you will need to access the article online to obtain the date of publication).

Singh D, Wijeyekoon B. Non-contiguous spinal tuberculosis. *BMJ Case Reports* 2012;10.1136/bcr-2012-007382, Published XXX

Become a Fellow of BMJ Case Reports today and you can:
- Submit as many cases as you like
- Enjoy fast sympathetic peer review and rapid publication of accepted articles
- Access all the published articles
- Re-use any of the published material for personal use and teaching without further permission

For information on Institutional Fellowships contact consortiasales@bmjgroup.com

Visit casereports.bmj.com for more articles like this and to become a Fellow

BMJ Case Reports: first published as 10.1136/bcr-2012-007382 on 9 November 2012. Downloaded from http://casereports.bmj.com/ on 19 April 2024 by guest. Protected by copyright.