BMJ Case Reports

Images in...

The BOOP trojan horse in Wegener's granulomatosis: a reminder to pathologists and clinicians

Andleeb Abrari,[1] Vandana Bakshi[2]

[1]Histopathology, Max Super Specialty Hospital, New Delhi, India;
[2]ENT, Private Practice, New Delhi, India

Correspondence to Andleeb Abrari, abrariand@gmail.com

DESCRIPTION

The histologic sine qua non sought for a diagnosis of Wegener's granulomatosis (WG) are vasculitis, (geographic) necrosis and granulomas in the appropriate clinico serologic context.

That these pathognomons may be altogether absent, leading to misdiagnosis and mistreatment, should be remembered, as illustrated by this case.[1]

The patient was a 30-year-old woman beleaguered with intermittent cough and dyspnoea on exertion, and insignificant physical findings, at presentation, and nodulolinear, pulmonary infiltrates on imaging. Transbronchial lung biopsy, significantly, was bereft of necrosis, granulomas, neutrophlic microabscesses or vasculitis; instead depicting histology classic for BOOP (figure 1).

The patient was started on steroids, but remained clinically obdurate and developed stridor. Direct laryngoscopy revealed an excoriated mucosal lesion in the epiglottis; histology of which revealed active vasculitis, neutrophilic fragmentation and necrosis (figure 2). Immunofluorescent test for cytoplasmic antineutrophil cytoplasmic antibodies performed, based on histology, returned high positive and a diagnosis of Wegener's was made.

Travis *et al* (1991) describe the histologic manifestations of pulmonic Wegener's, dichotomised as major and minor. The three major pathologic manifestations of classical WG included parenchymal necrosis, vasculitis and granulomatous inflammation accompanied by an inflammatory infiltrate composed of a mixture of neutrophils, lymphocytes, plasma cells, histiocytes and eosinophils. The minor histologies included interstitial fibrosis, alveolar haemorrhage, tissue eosinophils, organising intraluminal fibrosis, endogenous lipoid pneumonia, lymphoid aggregates and a variety of bronchial/bronchiolar lesions including acute and chronic bronchiolitis, follicular bronchiolitis and bronchiolitis obliterans. They found the minor manifestations

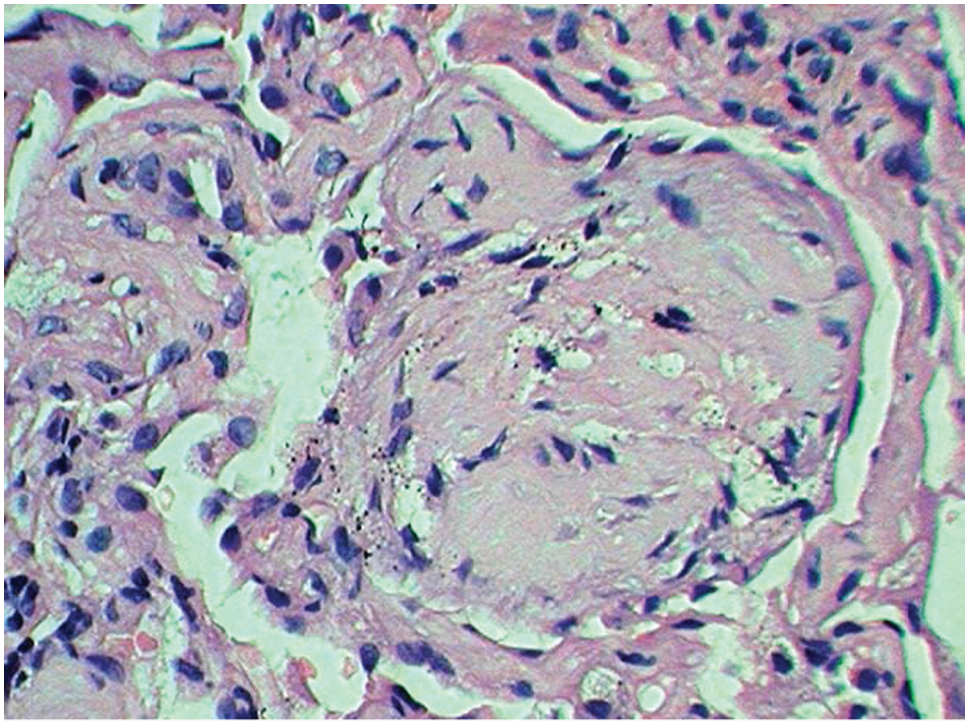

Figure 1 Transbronchial lung biopsy (H&E, ×40) fibrous plug occluding an alveolus (arrow), and a degree of fibrous interstitial expansion, diagnostic of BOOP. No necrotising vasculitis was discerned in the biopsy.

BMJ Case Reports: first published as 10.1136/bcr.11.2010.3483 on 24 February 2011. Downloaded from http://casereports.bmj.com/ on 26 April 2024 by guest. Protected by copyright.

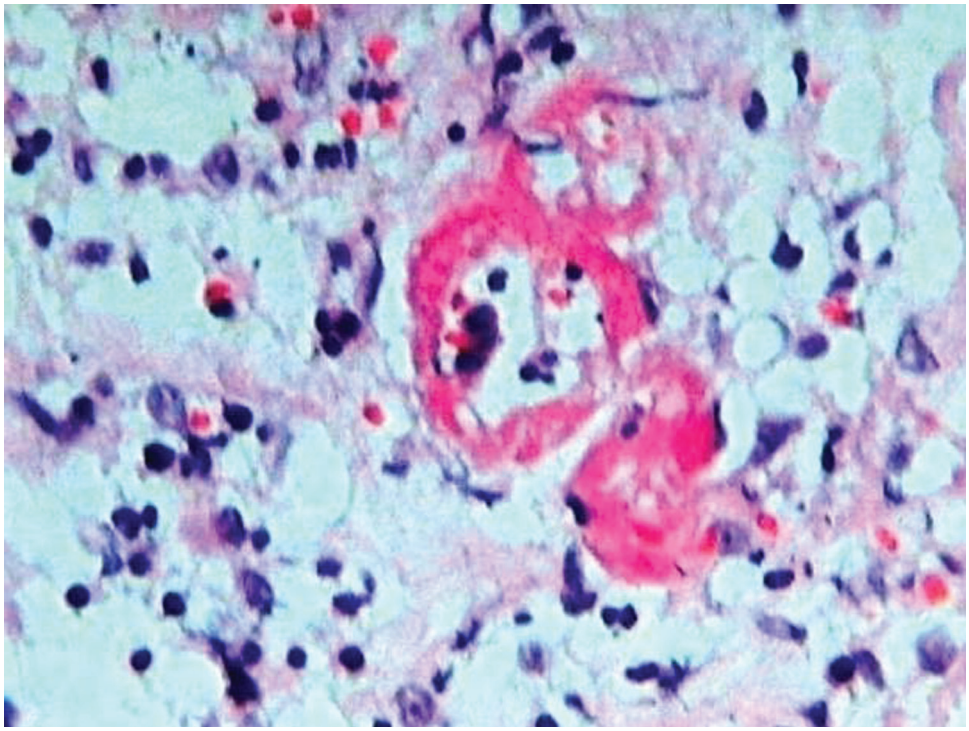

Figure 2 Larynx biopsy (H&E, ×40) necrotising vasculitis (arrow), neutrophilic fragmentation and oedema. Parenchymal necrosis and small granulomas were present elsewhere.

most commonly associated with classical WG lesions, and when the association was present – these were usually inconspicuous and not useful as primary diagnostic criteria. These authors found the minor lesions representing the dominant or major finding in a proportion of cases.[2]

It is this latter category that can be the most confounding at the instance of initial histologic assessment.

Competing interests None.

Patient consent Obtained.

REFERENCES

1. **Uner AH,** Rozum-Slota B, Katzenstein AL. Bronchiolitis obliterans-organizing pneumonia (BOOP)-like variant of Wegener's granulomatosis. A clinicopathologic study of 16 cases. *Am J Surg Pathol* 1996;**20**:794–801.
2. **Travis WD,** Hoffman GS, Leavitt RY, *et al*. Surgical pathology of the lung in Wegener's granulomatosis. Review of 87 open lung biopsies from 67 patients. *Am J Surg Pathol* 1991;**15**:315–33.

This pdf has been created automatically from the final edited text and images.

Copyright 2011 BMJ Publishing Group. All rights reserved. For permission to reuse any of this content visit
http://group.bmj.com/group/rights-licensing/permissions.
BMJ Case Report Fellows may re-use this article for personal use and teaching without any further permission.

Please cite this article as follows (you will need to access the article online to obtain the date of publication).

Abrari A, Bakshi V. The BOOP trojan horse in Wegener's granulomatosis: a reminder to pathologists and clinicians . *BMJ Case Reports* 2011; 10.1136/bcr.11.2010.3483, date of publication

Become a Fellow of BMJ Case Reports today and you can:
- ► Submit as many cases as you like
- ► Enjoy fast sympathetic peer review and rapid publication of accepted articles
- ► Access all the published articles
- ► Re-use any of the published material for personal use and teaching without further permission

For information on Institutional Fellowships contact consortiasales@bmjgroup.com

Visit casereports.bmj.com for more articles like this and to become a Fellow

BMJ Case Reports: first published as 10.1136/bcr.11.2010.3483 on 24 February 2011. Downloaded from http://casereports.bmj.com/ on 26 April 2024 by guest. Protected by copyright.