BMJ Case Reports

Images in...

Tracheal fistula associated with bevacizumab 20 months after mediastinal radiation

Hideto Yamada, Wataru Shigemori, Yasushi Ryujin, Hiroshi Wada, Tetsuya Oguma, Makoto Osawa, Taishi Nagao, Yasutaka Nakano

Department of Internal Medicine, Division of Respiratory Medicine, Shiga University of Medical Science, Seta Tsukinowa-cho, Otsu, Japan

Correspondence to Hideto Yamada, otedih@belle.shiga-med.ac.jp

DESCRIPTION

We report a case of a 60-year-old woman who developed a tracheal fistula 20 months after mediastinal radiation while being treated with bevacizumab. She presented with a large right-sided mediastinal mass given a diagnosis of stage IIIB adenocarcinoma. She was treated with definitive thoracic radiation (figure 1) and a concurrent chemotherapy, including both cisplatin and docetaxel. Eleven months after chemoradiotherapy she developed progressive disease with enlargement of the mass and pleural effusion ipsilateral to the site of the mass. She was treated with pemetrexed as a second-line chemotherapy. Seven months later, she developed progressive disease with bilateral pleural effusion. She received a third-line systemic chemotherapy with carboplatin, paclitaxel and bevacizumab (15 mg/kg) every 3 weeks. After three cycles, she developed dry cough and fever. Three weeks after her third cycle, she was obtunded with respiratory failure associated with hypercapnia. CT scan showed destruction of the right tracheal wall (figure 2). Non-invasive positive pressure ventilation was used to improve respiratory failure but she and her family would not agree to further attempts, including intubation, stent placement nor surgical repair. She died of respiratory failure several days later.

When administered in combination with thoracic radiation, bevacizumab has been associated with tracheo-

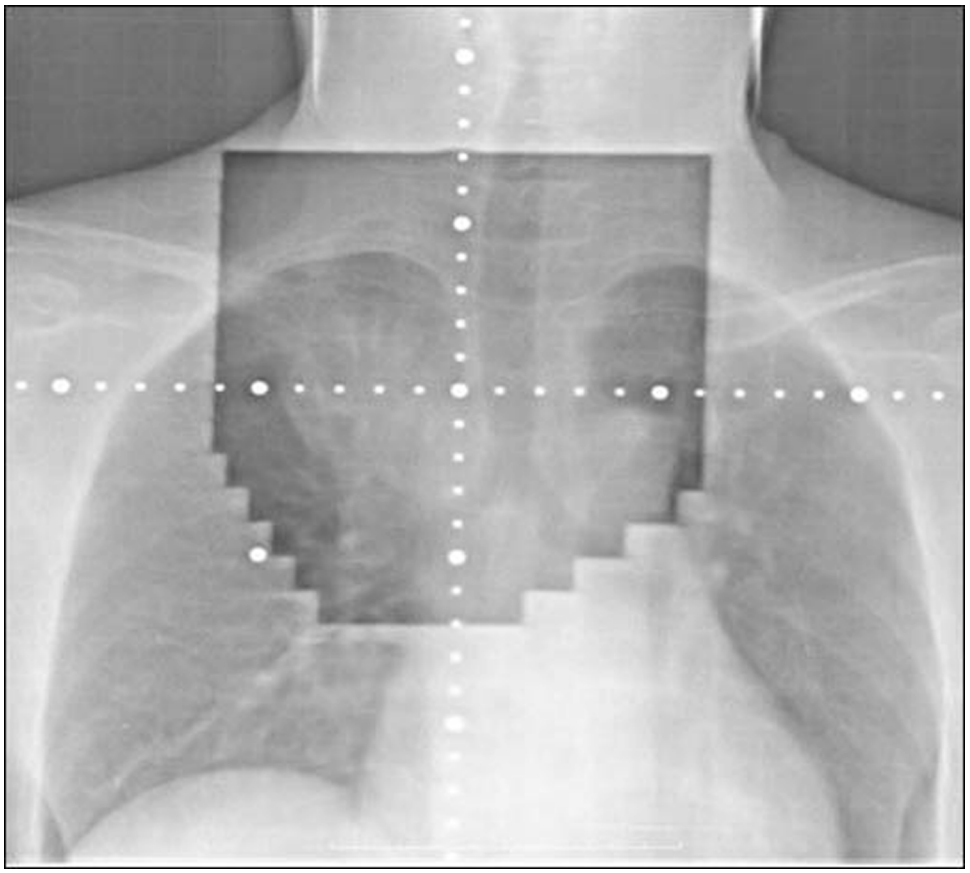

Figure 1 Portal radiograph used for irradiation of adenocarcinoma of the lung, adjacent to the mediastinum, in the right upper lobe with a total dose of 60 Gy.

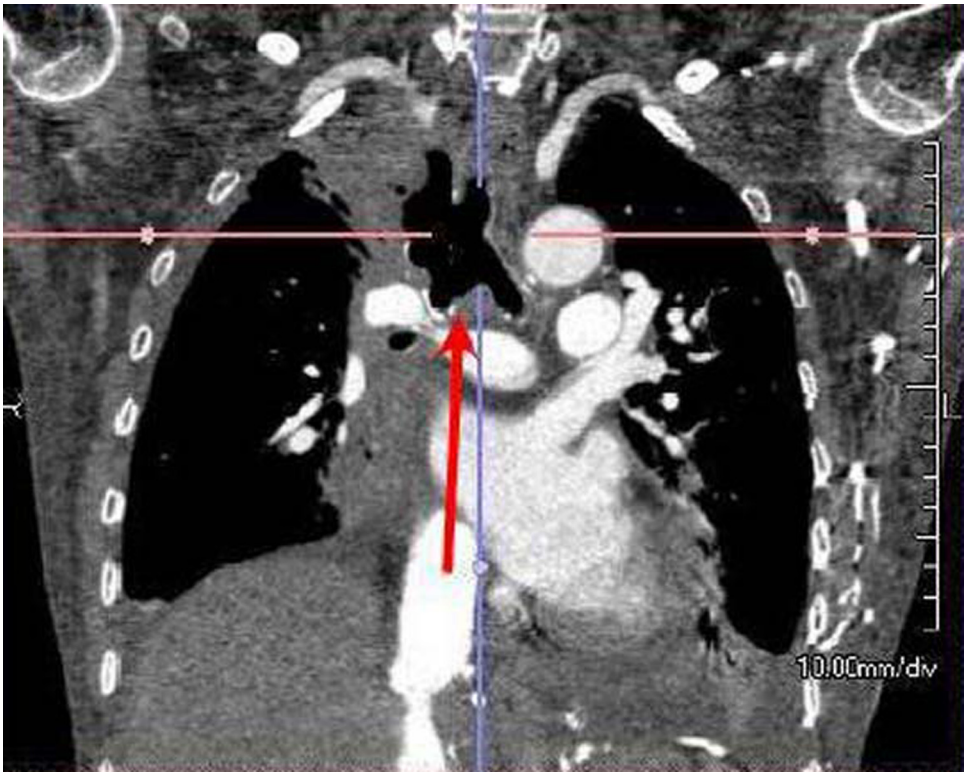

Figure 2 CT scan showed that the right tracheal wall was destructed after the patient received three cycles of third-line systemic chemotherapy, including bevacizumab (red arrow).

oesophageal fistula.[1] Delayed tracheo-oesophageal fistulae have also been reported in patients treated with bevacizumab even months after chemoradiotherapy.[2 3] Thus, physicians should be cautious about the formation of life-threatening fistula in patients with lung cancer treated with bevacizumab after a high dose of mediastinal radiation.

Competing interests None.

Patient consent Obtained.

REFERENCES

1. **Spigel DR,** Hainsworth JD, Yardley DA, *et al*. Tracheoesophageal fistula formation in patients with lung cancer treated with chemoradiation and bevacizumab. *J Clin Oncol* 2010;**28**:43–8.
2. **Gore E,** Currey A, Choong N. Tracheoesophageal fistula associated with bevacizumab 21 months after completion of radiation therapy. *J Thorac Oncol* 2009;**4**:1590–1.
3. **Goodgame B,** Veeramachaneni N, Patterson A, *et al*. Tracheo-esophageal fistula with bevacizumab after mediastinal radiation. *J Thorac Oncol* 2008;**3**:1080–1.