



OPEN ACCESS

# Management of an acute intracranial emergency in pregnancy

Petronella Brokkelkamp <sup>1</sup>, Jelle H Baalman,<sup>1</sup> Maarten J Driesse,<sup>2</sup> Kuan H Kho <sup>2,3</sup>

<sup>1</sup>Obstetrics and Gynaecology, Medisch Spectrum Twente, Enschede, The Netherlands  
<sup>2</sup>Neurosurgery, Medisch Spectrum Twente, Enschede, The Netherlands  
<sup>3</sup>Clinical Neurophysiology Group, University of Twente Faculty of Science and Technology, Enschede, The Netherlands

**Correspondence to**  
 Kuan H Kho; k.kho@mst.nl

Accepted 23 February 2024

## SUMMARY

We report a case of a mid-20s primigravida at 37 weeks' gestation who presented with severe headache and acute neurological deterioration. The CT brain scan showed hydrocephalus caused by a colloid cyst in the third ventricle. The patient underwent emergency placement of an external ventricular drain for decompression of acute hydrocephalus. Four hours later, labour commenced spontaneously, and in view of her neurological status, a decision was taken to perform a caesarean section under general anaesthetics. Four days postpartum, the patient underwent an endoscopic removal of the cyst. Intracranial emergencies during pregnancy are rare and challenging to manage. The mortality rate can be significant. Diagnostic and surgical intervention should not be delayed because of pregnancy. An individualised treatment approach is required with multidisciplinary input. The collaborative efforts of our multidisciplinary team resulted in prompt diagnosis and surgical treatment in this case that resulted in both a healthy mother and child.

## BACKGROUND

A colloid cyst is a rare benign tumour located in the third ventricle. The estimated incidence is 0.9 per 1 million.<sup>1</sup> It is an epithelial-lined cyst filled with mucus. These cysts tend to grow slowly over time and may cause obstructive hydrocephalus by blocking the foramen of Monro. The most common symptoms secondary to hydrocephalus include headache, blurred vision and dizziness. Acute hydrocephalus may lead to sudden death.<sup>2</sup> Development of colloid cysts is not increased in pregnancy. When symptomatic, they are usually present from ages 20 years to 50 years, which coincides with women's reproductive age.<sup>2</sup> Intracranial emergencies during pregnancy are rare, have a high mortality rate for both mother and child and as such pose major challenges in management.<sup>3</sup> A multidisciplinary team of neurosurgeons, obstetricians and anesthesiologists must work together to reduce both maternal and fetal mortality. We present a case of a pregnant patient with an acute hydrocephalus caused by a colloid cyst, in whom multidisciplinary management resulted in a healthy mother and child.

## CASE PRESENTATION

A mid-20s primigravida at 37 weeks and 3 days of gestation presented to the emergency department with a severe headache. 18 months prior to admission, she started to experience headaches attributed to migraine every 3 months for which

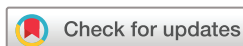she took paracetamol. Usually, this headache disappeared after a couple of hours of sleep. During the year before the hospital admission, she experienced symptoms of fatigue and double vision, for which she visited an ophthalmologist. Slightly impaired vision was found, and she began wearing glasses. During her pregnancy, she had two episodes of headaches. Her pregnancy so far had been uncomplicated.

At the time of presentation, the patient reported a headache that was more severe than ever before. The headache was initially bifrontal but progressed to holocranial in 3–4 hours, accompanied by nausea but no vomiting. Her vision was normal, and she had no epigastric or abdominal pain. She reported normal movement of the fetus. On physical examination, she was normotensive with a blood pressure of 130/80 mm Hg, and her pulse rate was 61 beats per minute. There were no signs of oedema in her hands or legs. The patellar reflexes were normal. She had a low temperature of 35.8°. Fetal heart rate was 130 beats per minute. We wanted to rule out or confirm pre-eclampsia and HELLP (Haemolysis, Elevated Liver enzymes, Low Platelets; currently regarded as a variant of severe preeclampsia) syndrome by taking a blood and urine sample from the patient. While monitoring the vitals of the patient and fetus, we consulted a neurologist to evaluate the patient's headache.

An hour after admission, she suddenly started vomiting and had a sudden drop in consciousness. Her airway was unobstructed; she was breathing normally with an oxygen saturation of 99%. She was haemodynamically stable, with a blood pressure of 128/80 mm Hg and a heart rate of 74 beats per minute. Her temperature was 36.1°. Neurological examination showed a comatose patient with anisocoric (dilated) pupils, non-responsive to light and a Glasgow Coma Scale (GCS) of 8 (E1M4V3). To rule out or confirm a potential intracranial pathology, we consulted a neurosurgeon and ordered an emergency CT scan of the brain.

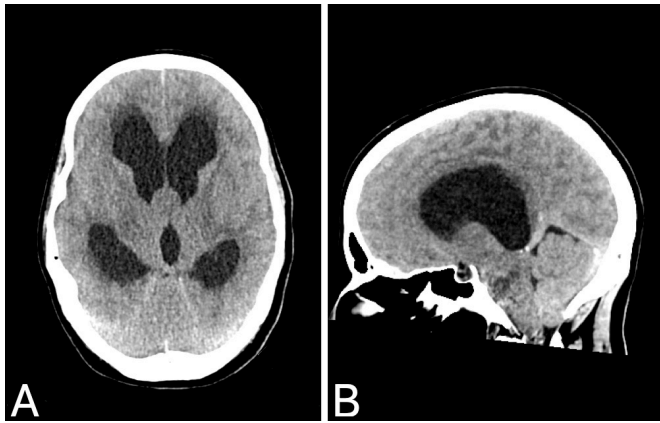
## INVESTIGATIONS

An emergency CT scan of the brain showed a severe obstructive hydrocephalus, attributed to a colloid cyst at the foramen of Monro (figure 1). A blood test showed mild thrombocytopenia ( $110 \times 10^9/L$ ; reference range  $150\text{--}400 \times 10^9/L$ ) and leucocytosis ( $17.4 \times 10^9/L$ ; reference range  $4\text{--}10 \times 10^9/L$ ). Electrolytes, kidney function and liver functions were all within normal ranges (table 1). The urinary protein-to-creatinine ratio was 42.6 mg/mmol creatinine.



© BMJ Publishing Group Limited 2024. Re-use permitted under CC BY-NC. No commercial re-use. See rights and permissions. Published by BMJ.

**To cite:** Brokkelkamp P, Baalman JH, Driesse MJ, et al. *BMJ Case Rep* 2024;**17**:e258066. doi:10.1136/bcr-2023-258066



**Figure 1** CT scan of the brain at admission demonstrating enlarged ventricles and the obstruction at the level of the foramen of Monro (A, transversal; B, sagittal).

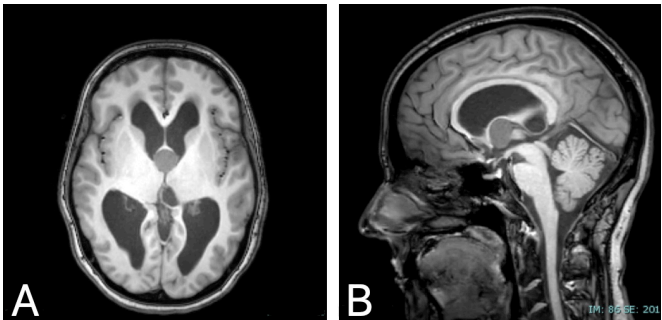
DIFFERENTIAL DIAGNOSIS

In the case of a pregnant patient with a sudden drop in consciousness, pre-eclampsia or HELLP syndrome is thought of as the most common diagnosis. The differential diagnosis of loss of consciousness may also be sought in a cardiac or neurological origin. To rule out cerebral causes such as strokes, mass lesions or hydrocephalus, a CT scan of the brain can be made. Other possible causes of loss of consciousness may be epilepsy, traumatic brain injury, cardiac arrest or cardiac arrhythmia, shock or hypoglycaemia.

In a life-threatening event, a structured assessment with the Airway, Breathing, Circulation, Disability, Exposure (ABCDE) approach is the best method for initial assessment and stabilisation of the patient. In our case, the patient was respiratory and haemodynamically stable. The patient had a regular pulse and no hypertension. This ruled out cardiac arrest, arrhythmia and shock. Neurological assessment (disability, D) showed a drop in consciousness, without symptoms of an eclamptic insult. Anisocoric dilated pupils, non-responsive to light suggested a potential acute intracranial emergency. The CT scan of the brain showed acute hydrocephalus, prompting an acute neurosurgical intervention.

TREATMENT

The CT results prompted an acute neurosurgical intervention, that is, the placement of an external ventricular drain (EVD). A gynaecologist was present at the surgery to perform an emergency caesarean section in case of failed intubation or haemodynamic instability of the mother. During the



**Figure 2** MRI scan of the brain after external ventricular shunt placement. The diagnosis of a colloid cyst is confirmed (A, T1 transversal; B, T1 sagittal).

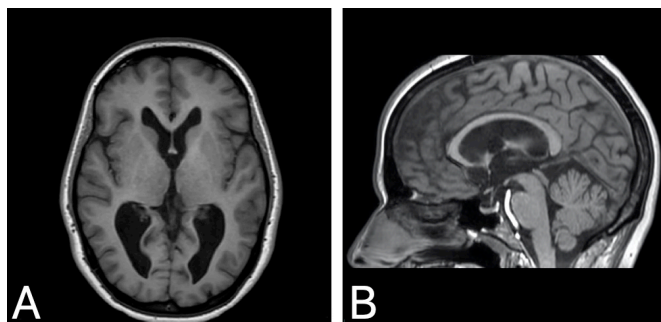
neurosurgery, the patient was in a supine position. The fetal heart rate was monitored before and after surgery. The emergency procedure confirmed high intracranial pressure (ICP) (>50 cm H<sub>2</sub>O).

The placement of the EVD was successful, and no caesarean section was necessary. Then, the patient was transferred to the intensive care unit as planned. She was haemodynamically stable. After the surgery, her consciousness improved to a GCS of 12 (E2M5V4). She reported continued blurred vision. Within hours of the placement of the EVD, the patient went into spontaneous labour. Her cervix was 3 cm dilated during the initial examination. Because of the patient’s low conscious state, it was considered that she would not be able to cooperate with a safe vaginal birth. We performed a caesarean section under general anaesthesia, where a healthy child was born, weighing 3075 g with Apgar scores of 5/8/10 at 1 min, 5 min and 10 min.

After the caesarean section, her consciousness was restored with a GCS of 15 (E4M6V5). She complained about blurred vision and experienced severe antegrade amnesia. By the next morning, her vision was completely restored. She has no recollection of the events of the previous day.

An MRI confirmed the diagnosis of hydrocephalus caused by an obstructive colloid cyst (figure 2). One day after the placement of the EVD and caesarean section, the patient developed hypertension with a blood pressure of 142/94 mm Hg. The blood test showed a drop in thrombocytes ( $87\times10^9/L$ ; reference range  $150\text{--}400\times10^9/L$ ). The liver functions remained within the normal range (aspartate aminotransferase 20 U/L, reference range <40, and alanine aminotransferase 13 U/L, reference range <45). There was no sign of haemolysis (lactate dehydrogenase 212 U/L; reference range <250). HELLP syndrome was ruled out given the normal liver function and no signs of haemolysis. Pre-eclampsia was not a likely diagnosis, but given the hypertension, low platelets and slightly elevated protein-to-creatin ratio, it was not entirely excludible. In addition, hypertension can occur during an intracranial emergency. To prevent a possible eclamptic insult, magnesium sulfate can be given intravenously. It is relatively safe to give, although the patient should be monitored closely for signs of overdosing. We administered magnesium sulfate intravenously per the following protocol: one loading dose of 4 g administered in 20 min via a syringe pump, followed by 1 g per hour continuously. During magnesium sulfate infusion, we assessed the patient continuously with a pulse oximeter and hourly with the urine output, respiratory rate and patellar reflexes. We collected a 24 hour urine sample from the patient which we

Table 1 Blood test results on the day of admission	
Test: value (reference range)	
Haemoglobin: 132 g/L (120–160)	Sodium: 135 mmol/L (135–145)
Haematocrit: 0.38 L/L (0.35–0.45)	Aspartate aminotransferase (AST): 23 U/L (<40)
Thrombocytes: $110\times10^9/L$ (150–400)	Alanine aminotransferase (ALT): 12 U/L (<45)
Leucocytes: $17.4\times10^9/L$ (4–10)	Lactate dehydrogenase: 170 U/L (<250)
Serum creatinine: 44 $\mu\text{mol/L}$ (50–90)	Gamma-glutamyl transferase: 15 U/L (<35)
Urea: 3.3 mmol/L (2.5–6.4)	Total bilirubin: <17 $\mu\text{mol/L}$ (<17)
GFR: >90 mL/min/1.73m <sup>2</sup> (>90)	Creatine kinase: 25 U/L (<245)
Potassium: 4.4 mmol/L (3.5–5.0)	Albumin: 32 g/L (29–46)



**Figure 3** MRI scan of the brain after endoscopic resection of the cyst. Note the normalised size of the ventricles (A, T1 transversal; B, T1 sagittal).

analysed for proteinuria. There was no proteinuria in the 24 hour urine sample, and we were able to rule out pre-eclampsia. At 24 hours postnatal, magnesium sulfate intravenous infusion was discontinued. Nifedipine 30 mg retard was given to manage hypertension. Four days postpartum, the patient underwent an uncomplicated endoscopic removal of the colloid cyst (figure 3).

### OUTCOME AND FOLLOW-UP

After a total of 2 weeks of hospital stay, a short week after the second neurosurgical operation, the patient was discharged home with her newborn. Cognitive screening with the Montreal Cognitive Assessment before discharge showed no signs of mental impairment. Six months after treatment, the patient reported that she did not have headaches and had no residual neurological deficit.

### DISCUSSION

Headaches occur frequently during pregnancy. Headaches are classified into primary headaches, in which the headache itself is the issue, such as migraine and tension-type headaches, and secondary headaches, which are caused by an underlying disease. Pregnancy is a risk factor for secondary headaches due to hormonal changes and hypercoagulability. A prospective study found that half of secondary headaches during pregnancies are caused by hypertensive disorders. Within that group, pre-eclampsia accounts for most.<sup>4,5</sup> Brain tumours and intracranial emergencies during pregnancy are very rare, with an estimated incidence of 0.04%.<sup>3</sup>

A colloid cyst is a rare brain tumour. Approximately two-thirds of patients with a colloid cyst experience symptoms, and half of the symptomatic group presents with hydrocephalus. Acute hydrocephalus causes elevated ICP and may result in death.<sup>2</sup> Curative treatment consists of endoscopic resection of the cyst.<sup>1</sup> Colloid cysts are not known to be related to pregnancy. Diagnosis and management are challenging because of the low incidence and because the symptoms mimic more prevalent diseases like pre-eclampsia.

When a pregnant patient presents to the hospital with a headache, it is important to confirm or rule out more prevalent diseases like pre-eclampsia. However, when a life-threatening event happens, the structured, universal approach based on the 'ABCDE' approach is the best method for initial assessment and stabilisation of the patient.<sup>6</sup> It is standardised in all areas of medicine, including obstetrics, and thus must also be applied to pregnant women.<sup>6</sup> The systematic approach improves collaboration between different disciplines. In our

case, the patient was haemodynamically stable but had a worsening in the disability assessment, necessitating imaging of the head.

During and after initial stabilisations in this case, we faced a number of difficulties regarding the management. First, we had to decide what type of imaging we would use. Although MRI is the imaging technique of choice for the pregnant patient, CT is the first choice for imaging the brain in neurological or neurosurgical emergencies. A CT scan of the head poses little to no risk for the fetus in terms of radiation exposure.<sup>7</sup>

Second, we discussed with our team whether to perform an emergency caesarean section prior to the placement of the EVD or to perform surgery on the pregnant woman. No randomised controlled trials have been conducted for surgery in a pregnant woman, so no specific recommendations have been made. The American College of Obstetricians Committee recommends that a pregnant woman should never be denied medically necessary surgery or have that surgery delayed, regardless of trimester, as this could adversely affect both the pregnant woman and her fetus.<sup>8</sup> Non-obstetric surgery during pregnancy occurs in approximately 0.7%–1.6% of pregnant women.<sup>9–11</sup> Most common surgeries are abdominal, such as appendectomy or cholecystectomy. Pregnancies in which non-obstetric surgery takes place are associated with a higher risk of miscarriage, stillbirth, preterm deliveries, lower birth weight in infants and more caesarean deliveries.<sup>9,12</sup> A study by Balinskaite *et al* showed that the overall attributable risk of these adverse birth outcomes in women having surgery during their pregnancy compared with women who did not was generally low.<sup>9</sup> Furthermore, studies cannot differentiate whether the adverse birth outcome is related to the operation or the underlying disease.<sup>9,12</sup>

In case of neurosurgery during pregnancy, it has been suggested that from a gestational age of 34 weeks or more, an emergency caesarean section should be considered before neurosurgery.<sup>13–15</sup> Possible advantages include fewer pregnancy-related issues during surgery, such as intubation, ventilation and blood pressure management, or the ability to allow pharmacological control of ICP.<sup>14</sup> On the other hand, other studies suggest that because operating is relatively safe, treatment for the mother should not be delayed by performing a caesarean section first.<sup>16</sup>

In our case, the patient had elevated ICP because of the acute hydrocephalus. This can lead to brain damage, various stages of coma and eventually death. A quick intervention is crucial to prevent (secondary) brain damage. The placement of an EVD is essential in the early management of ICP to reduce ICP and potentially prevent brain damage.<sup>17</sup> A caesarean section prior to the placement of the EVD could have led to irreversible brain damage. Due to the EVD, the ICP returned to normal, and the consciousness of the patient improved gradually. The pregnancy could be maintained.

Since our patient was diagnosed with labour hours after the EVD was placed, what was the best method to deliver? The patient was not yet fully conscious and presented with psychomotor agitation. She was clinically diagnosed in labour but could not be instructed for a vaginal delivery. We considered an assisted vaginal birth with neuraxial anaesthesia. The advantages of vaginal delivery are that there is no risk of general anaesthesia during caesarean section, faster recovery after birth and no risks for the next pregnancy. However, we could not properly determine whether the patient experienced enough pain relief from the anaesthesia. Also, neuraxial anaesthesia is not without risks. Neuraxial



## Case report

### Patient's perspective

One and a half years before my presentation in the hospital, I got my first migraine attack. It was an intense stabbing pain behind my right eye. From that moment on, it happened every 3–4 months, sometimes with vomiting. Whenever I got the headache, I went to sleep, and the pain would disappear after a few hours. I went to a physiotherapist who treated my back muscles, and for a few months, I experienced no headaches. A year ago, I suddenly started to experience double vision, which I attributed to my fatigue. I went to an ophthalmologist, and they fitted me with glasses. With the glasses, both the headaches and the double vision were gone. Then I found out I was pregnant! My whole pregnancy went very smoothly even though I had a COVID infection in the first weeks of my pregnancy. In the third trimester, I experienced migraine attacks on a regular basis. One day, I began experiencing a headache. I tried to go to sleep to see if it would help against the headache, but this time, it didn't go away. The pain was unbearable, and my partner decided to come home. He alerted my midwife, who came to our house and accompanied us to the hospital. I remember that my partner handed me pants, which I did not want to wear. From the moment I refused the pants my partner gave me to the moment I woke up with our son in my arms, I only have three memories. My first memory is of throwing up, and my second memory is of a tube in my mouth. My third and final memory is that my hands were tied to the bed. This memory is correct because, apparently, I was trying to pull the drain out of my head. Another thing I remember is that I had the song 'On the Boardwalk' in my head almost every day; it drove me crazy. On the first days of my admission, I was in the ICU. I only saw our son when they brought him to me for breastfeeding. These were moments I really looked forward to. After a few days, I transferred to the neurology department, where I could stay together with my child and partner. Then followed the operation to remove the colloid cyst. I was very nervous before the operation. I have never had surgery before, and now I have suddenly had it three times within 1 week. All the visits we received from family and from the hospital staff did me good. It did not matter if this was for fun or medical-related; it gave me a sense of time. My memory was very bad in the first few weeks. This was especially noticeable when I got home and had to do everything myself again, besides taking care of a newborn baby. The first weeks were really hard: it felt like I had been very close to death. I was afraid to go out, afraid that something might happen to me or my son. Fortunately, this feeling was replaced by a feeling of intense gratitude within a few weeks. Grateful to still be here, for the actions of my partner and all the medical professionals. Half a year after my operation, I finally feel a bit better again. To this date, I have had no more migraines. I still wear my glasses despite the fact that the double vision was probably caused by the cyst. The extreme fatigue I experienced upon returning home is as good as gone. I will never be the old me again because I have had this experience, which gave me a new perspective on life.

anaesthesia in a patient with increased ICP is usually considered to be a contraindication because of the risk of brain herniation.<sup>18</sup> With an EVD, the ICP is normalised and can be monitored, allowing for the safe administration of neuraxial anaesthesia.<sup>19</sup> A caesarean section would prevent elevation of the ICP caused by uterine contraction and pushing. As no

guidelines exist on these topics, we involved the multiple medical disciplines, the patient and the family in a shared decision-making process. We decided to perform a caesarean section under general anaesthetics due to the somnolent state of the patient.

### Learning points

- ▶ New-onset headaches in pregnancy should be reviewed carefully as they can be a sign of an underlying life-threatening neurological disease instead of more prevalent diseases like pre-eclampsia.
- ▶ The pregnant patient should not be withheld diagnostics like a CT scan and emergency surgery to diagnose and treat the underlying disease due to her pregnancy.
- ▶ In case of a life-threatening intracranial emergency, surgical intervention should not be delayed by delivery.
- ▶ Collaboration of all involved medical disciplines is essential to make an individualised treatment approach.

**Acknowledgements** We like to acknowledge Professor F McAuliffe for her insightful comments and suggestions on our manuscript, and thank the patient for her cooperation and perspective.

**Contributors** PB and KHK took the lead in writing the manuscript. PB was responsible for drafting the text, sourcing and editing the investigation results. KHK was responsible for the sourcing and editing of clinical images. PB, JHB, MJD and KHK provided critical revision for important intellectual content. The following authors gave final approval of the manuscript: PB, JHB, MJD and KHK.

**Funding** The authors have not declared a specific grant for this research from any funding agency in the public, commercial or not-for-profit sectors.

**Competing interests** None declared.

**Patient consent for publication** Consent obtained directly from patient(s).

**Provenance and peer review** Not commissioned; externally peer reviewed.

**Open access** This is an open access article distributed in accordance with the Creative Commons Attribution Non Commercial (CC BY-NC 4.0) license, which permits others to distribute, remix, adapt, build upon this work non-commercially, and license their derivative works on different terms, provided the original work is properly cited and the use is non-commercial. See: <http://creativecommons.org/licenses/by-nc/4.0/>.

Case reports provide a valuable learning resource for the scientific community and can indicate areas of interest for future research. They should not be used in isolation to guide treatment choices or public health policy.

### ORCID iDs

Petronella Brokkelkamp <http://orcid.org/0009-0007-6476-2214>

Kuan H Kho <http://orcid.org/0000-0002-1834-0922>

### REFERENCES

- 1 Brostigen CS, Meling TR, Marthinsen PB, *et al.* Surgical management of colloid cyst of the third ventricle. *Acta Neurol Scand* 2017;135:484–7.
- 2 Beaumont TL, Limbrick DD, Rich KM, *et al.* Natural history of colloid cysts of the third ventricle. *JNS* 2016;125:1420–30.
- 3 Esmaeilzadeh M, Uksul N, Hong B, *et al.* Intracranial emergencies during pregnancy requiring urgent neurosurgical treatment. *Clin Neurol Neurosurg* 2020;195:105905.
- 4 Negro A, Delaruelle Z, Ivanova TA, *et al.* European headache Federation school of advanced studies (EHF-SAS). headache and pregnancy: a systematic review. *J Headache Pain* 2017;18:106.
- 5 Robbins MS, Farmakidis C, Dayal AK, *et al.* Acute headache diagnosis in pregnant women: a hospital-based study. *Neurology* 2015;85:1024–30.
- 6 Paterson-Brown S, Howell C. *Managing Obstetric Emergencies and Trauma*. 3th ed. Cambridge: Cambridge University Press, 2014.
- 7 Copel J, El-Sayed Y, Heine RP, *et al.* Guidelines for diagnostic imaging during pregnancy and lactation. *Obstet Gynecol* 2017;130:e210–6.
- 8 American College of Obstetricians and Gynaecologists' Committee. Nonobstetric surgery during pregnancy. ACOG COMMITTEE OPINION number 775. Available:

- <https://www.acog.org/clinical/clinical-guidance/committee-opinion/articles/2019/04/nonobstetric-surgery-during-pregnancy> [Accessed 31 Jan 2023].
- 9 Balinskaite V, Bottle A, Sodhi V, *et al.* The risk of adverse pregnancy outcomes following nonobstetric surgery during pregnancy: estimates from a retrospective cohort study of 6.5 million pregnancies. *Ann Surg* 2017;266:260–6.
  - 10 Rasmussen AS, Christiansen CF, Uldbjerg N, *et al.* Obstetric and non-obstetric surgery during pregnancy: a 20-year Danish population-based prevalence study. *BMJ Open* 2019;9:e028136.
  - 11 Tolcher MC, Fisher WE, Clark SL. Nonobstetric surgery during pregnancy. *Obstet Gynecol* 2018;132:395–403.
  - 12 Fu PH, Yu CH, Chen YC, *et al.* Risk of adverse fetal outcomes following nonobstetric surgery during gestation: a nationwide population-based analysis. *BMC Pregnancy Childbirth* 2022;22:406.
  - 13 Ng J, Kitchen N. Neurosurgery and pregnancy. *J Neurol Neurosurg Psychiatry* 2008;79:745–52.
  - 14 Chowdhury T, Chowdhury M, Schaller B, *et al.* Perioperative considerations for neurosurgical procedures in the gravid patient: continuing professional development. *Can J Anaesth* 2013;60:1139–55.
  - 15 Godoy DA, Robba C, Paiva WS, *et al.* Acute intracranial hypertension during pregnancy: special considerations and management adjustments. *Neurocrit Care* 2022;36:302–16.
  - 16 Nossek E, Ekstein M, Rimón E, *et al.* Neurosurgery and pregnancy. *Acta Neurochir (Wien)* 2011;153:1727–35.
  - 17 Fried HI, Nathan BR, Rowe AS, *et al.* The insertion and management of external ventricular drains: an evidence-based consensus statement. *Neurocrit Care* 2016;24:61–81.
  - 18 Leffert LR, Schwamm LH. Neuraxial anesthesia in parturients with intracranial pathology: a comprehensive review and reassessment of risk. *Anesthesiology* 2013;119:703–18.
  - 19 Reschke M, Sweeney JM, Wong N. Spinal anesthesia performed for cesarean delivery after external ventricular drain placement in a parturient with symptomatology from an intracranial mass. *Int J Obstet Anesth* 2019;37:122–5.

Copyright 2023 BMJ Publishing Group. All rights reserved. For permission to reuse any of this content visit <https://www.bmj.com/company/products-services/rights-and-licensing/permissions/>  
BMJ Case Report Fellows may re-use this article for personal use and teaching without any further permission.

Become a Fellow of BMJ Case Reports today and you can:

- Submit as many cases as you like
- Enjoy fast sympathetic peer review and rapid publication of accepted articles
- Access all the published articles
- Re-use any of the published material for personal use and teaching without further permission

#### Customer Service

If you have any further queries about your subscription, please contact our customer services team on +44 (0) 207111 1105 or via email at [support@bmj.com](mailto:support@bmj.com).

Visit [casereports.bmj.com](http://casereports.bmj.com) for more articles like this and to become a Fellow