



OPEN ACCESS

# Adenosquamous carcinoma of the gallbladder: a rare entity and dilemmas in its management

Muhammed Ali Zishan , Chin Li Tee

General Surgery, Redcliffe Hospital, Redcliffe, Queensland, Australia

**Correspondence to**  
Dr Muhammed Ali Zishan;  
mzis9716@uni.sydney.edu.au

Accepted 11 May 2023

## SUMMARY

Gallbladder carcinomas are the most common form of biliary tract malignancies with adenocarcinomas, by far the most common variant while adenosquamous (adenosquamous carcinoma of the gallbladder) or pure squamous cell carcinomas representing only 2%–10% of all gallbladder carcinomas. Despite being a minority, these tumours demonstrate aggressive behaviour resulting in delayed presentations with widespread local invasion. We report a case involving a woman in her 50s who was diagnosed on imaging with a suspected gallbladder malignancy in the community. She proceeded to have a laparoscopic extended cholecystectomy with a cuff of segment 4b and 5 liver resection and cystic node sampling revealing a T3N1 lesion which on further recommendation by the multidisciplinary team proceeded to have an open portal lymphadenectomy yielding another positive lymph node. This case report highlights the dilemmas encountered in the management of this rare histological subtype in the absence of well-defined treatment algorithm and evolving guidelines.

## BACKGROUND

Gallbladder carcinoma has an annual incidence between 3 and 4 per 100 000 cases in Australia.<sup>1</sup> Despite its rarity, the silent and often rapid progression of disease lends a dismal prognosis. Risk factors attributed to its development include obesity, cholelithiasis, presence of the gallbladder polyps, female sex and chronic infection with *Salmonella* or *Helicobacter* species.<sup>2,3</sup> Adenocarcinoma of the gallbladder is by far the most common histological subtype accounting for nearly 90%–95% of cases and is relatively well studied.<sup>4</sup> However, adenosquamous and pure squamous cell carcinomas of the gallbladder are much rare accounting for 2%–10% of all gallbladder carcinomas.<sup>2,4</sup> Owing to its rarity, there is a paucity of data on the clinicopathological features with no uniform histological definition, with most papers attributing any form of squamous differentiation combined with glandular features to the adenosquamous carcinoma of the gallbladder (ASCGB) subtype.<sup>5</sup> Existing literature would suggest ASCGB to be associated with an increased tumour size, poorer survival, aggressive nature and locally advanced at presentation.<sup>6</sup> In this paper, we present a case report of a woman in her 50s diagnosed with ASCGB with positive lymph nodes and the challenges encountered in its management.

## CASE PRESENTATION

A fit and well woman in her 50s with a background history of cervical cancer and an active heavy smoker presented to her local general practitioner

with a history of intermittent crushing right upper quadrant abdominal pain with associated vomiting and unintentional weight loss over the last month.

Examination revealed a soft abdomen with tenderness in the epigastric and right upper quadrant. There were no palpable masses or lymphadenopathy. Her observations were also within normal limits, and she appeared well from the end of the bed without any signs of jaundice, pruritus or rash.

## INVESTIGATIONS

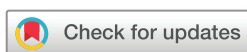An ultrasound requested in the community ([figure 1](#)) failed to demonstrate cholelithiasis but did note a 31×33×26 mm solid lesion at the fundus of the gallbladder suspicious for a malignancy, however, differentials would include a large polyp or mass-forming xanthogranulomatous cholecystitis. A CT chest/abdomen/pelvis performed subsequently confirmed that this circumferential fundal mass was likely to represent a gallbladder neoplasm without any evidence of nodal or distant metastasis ([figure 2](#)).

However, prior to her outpatient surgical review, she presented to the emergency department with severe abdominal pain with bloodwork revealing a leucocytosis of  $13.5 \times 10^9$  g/L and mild neutrophilia of  $9.19 \times 10^9$  g/L. Her liver function tests were deranged in a mixed pattern with normal bilirubin levels. Her tumour markers revealed a slightly elevated carcinoembryonic antigen level (CEA) of 3.7 µg/L but with normal CA 19.9 level.

Given her clinical deterioration, a repeat ultrasound was performed nearly 3 weeks following her original ultrasound in the community which again demonstrated the known heterogeneous gallbladder fundal mass along with a solid nodule adjacent to the gallbladder measuring 15×13×9 mm which was concerning for portal lymphadenopathy. While there was no intrahepatic bile duct or extrahepatic bile duct dilation, her gallbladder wall was thickened to 4 mm. Once stabilised she was booked urgently on an elective list for operative management.

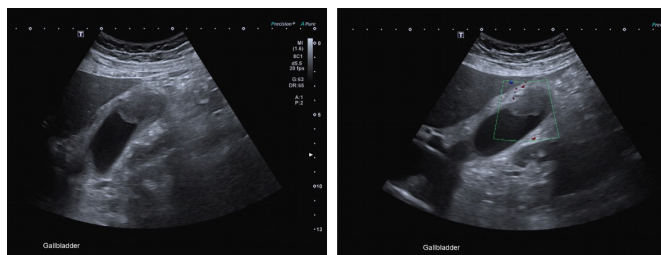
## TREATMENT

The patient underwent an elective laparoscopic extended cholecystectomy and a cuff of segment 4b and 5 liver resection and cystic node sampling. Standard port placement for a laparoscopic cholecystectomy and adhesiolysis was performed. Intraoperatively, a cuff of the cystic duct was sent off for frozen section which was negative for malignancy. The gallbladder along with a cuff of omentum and liver adjacent to the mass were removed en bloc ([figure 3](#)). The Calot's triangle was identified, and the right side



© BMJ Publishing Group Limited 2023. Re-use permitted under CC BY-NC. No commercial re-use. See rights and permissions. Published by BMJ.

**To cite:** Zishan MA, Tee CL. *BMJ Case Rep* 2023;**16**:e254883. doi:10.1136/bcr-2023-254883

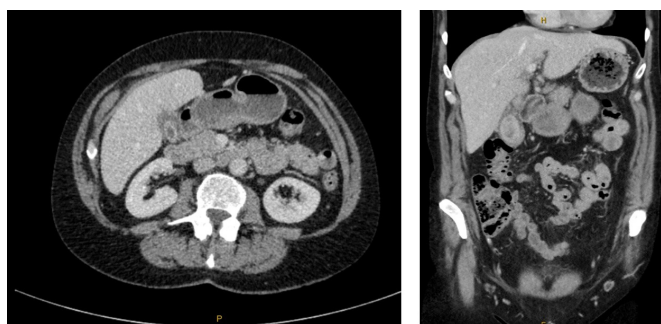


**Figure 1** Preoperative ultrasound imaging revealing suspected gallbladder mass within fundus with associated wall thickening and hyperaemia.

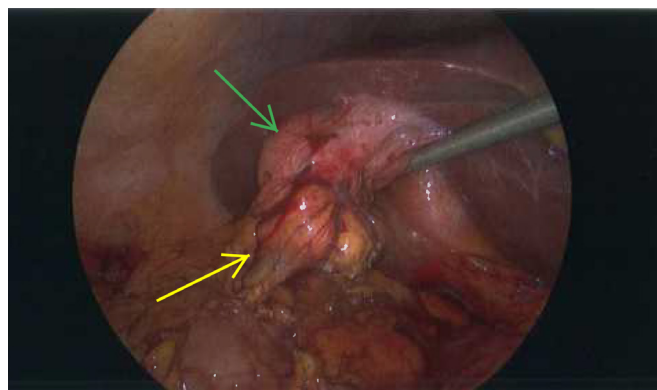
of the bile duct cleared along with the cystic node which was also sent for histopathology (figure 4). A drain was left within the gall bladder bed and the wounds closed in a standard fashion. She was monitored postoperatively in hospital and discharged day 2 on a full diet and her drain removed.

Histological assessment of her gall bladder revealed sheets of malignant cells demonstrating squamous morphology as confirmed on p40 staining (figure 5). In addition, there were foci of well-differentiated malignant glands (figure 6) with the overall appearance in keeping with an adenosquamous carcinoma. The tumour was noted to be infiltrating into the attached omental fat and demonstrating focal lymphovascular invasion without perineural involvement. There was also note of a focal high grade biliary intraepithelial neoplasia within the specimen, however, the margins were all clear from both the adenosquamous and intraepithelial components. The cystic duct margin was analysed and was confirmed to have no dysplasia or malignancy in keeping with the frozen section findings. The sampled cystic node showed evidence of metastatic carcinoma and this was deemed to be secondary to localised lymphovascular spread of disease. Given that her tumour had infiltrated the subserosal connective tissue into the attached omental fat with a positive cystic node her final pathological staging was T3N1.

A PET-CT (positron emission tomography) scan was requested to restage her disease which noted reactive changes at the surgical site as expected, however, a focus of intense FDG (fluorodeoxyglucose) avidity was noted within the sigmoid colon suspicious for a synchronous neoplasm. For completion purposes, she underwent a colonoscopy to visualise any sigmoid abnormalities which was unremarkable apart from a benign small polyp within the caecum and sigmoid diverticulosis. Her case was discussed at the multidisciplinary team (MDT) with a recommendation for a portal lymphadenectomy given her positive lymph node status.



**Figure 2** Preoperative CT scan revealing gall bladder mass in relation to other structures and absence of any obvious hepatic or distant metastases.



**Figure 3** Intraoperative image revealing gallbladder with mass at fundus (green arrow) adherent to adjacent liver and omentum (yellow arrow) which were removed en bloc.

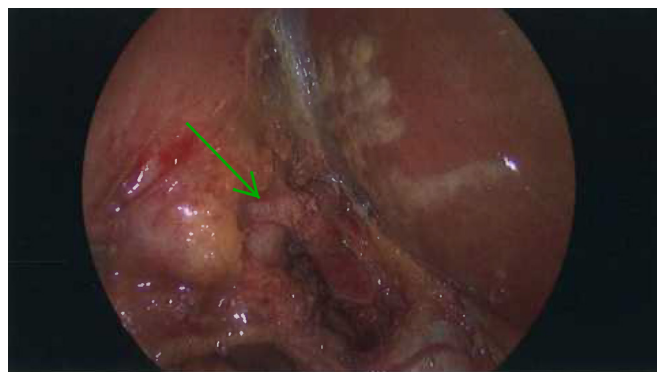
An open portal lymphadenectomy was performed with a right subcostal incision and periportal dissection of lymph nodes was undertaken with great care. Both anterior and posterior portal vein lymph node pockets were successfully retrieved with ligation of nearby vessels. Haemostatic agents were used at the surgical site prior to commencing closure in standard fashion. A transversus-abdominis plane catheter was left in situ for postoperative analgesia. She recovered gradually and was discharged postoperative day 6 without complications.

#### OUTCOME AND FOLLOW-UP

The histopathology from the portal lymphadenectomy yielded another positive lymph node out of the three removed thereby she had a total of 2/4 positive lymph nodes. The subsequent MDT recommendation was for the patient to proceed with adjuvant chemotherapy. She received eight cycles of intravenous gemcitabine and cisplatin. Apart from mild chemotherapy associated headaches and nausea, she tolerated the regimen quite well. A 6-month and 12-month surveillance staging scan has failed to demonstrate any disease recurrence. Given the low sensitivity of CEA or CA 19-9 as diagnostic biomarkers of the gallbladder malignancies,<sup>7</sup> we have opted to not perform routine tumour marker analysis for surveillance purposes.

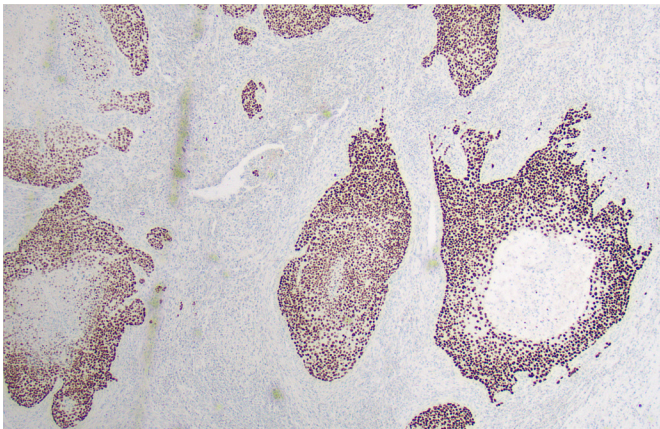
#### DISCUSSION

Gallbladder carcinomas are the most common biliary tree malignancies and despite a 71% reduction in mortality within the last three decades, its incidence is on the rise in Australia.<sup>1</sup> A 2021 analysis of the National Cancer Database in the USA found



**Figure 4** Intraoperative image revealing critical view with the dissection at Calots and clearance of cystic node and right side of bile duct. Green arrow to cystic duct.

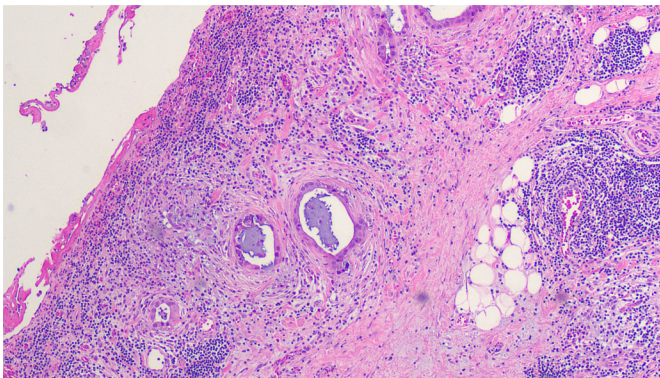




**Figure 5** Histopathology slides revealing squamous cells positive for p40 immunohistochemical staining.

an overall 5-year survival among ASCGB patients to be 18% following surgical resection when compared with a 25% overall 5-year survival in the gall bladder adenocarcinoma cohort post-surgical resection.<sup>5</sup> This study also found that tumour sizes greater than 4cm, positive lymph node status and involved surgical margins were independently associated with worse overall survival.<sup>5</sup> When applying these data to our case report, the fact that her tumour was <4cm with clear surgical margins, this would confer a favourable prognosis, however, her positive lymph node status would warrant further management.

Interestingly, the same study also found administration of chemotherapy combined with radiotherapy to be significantly



**Figure 6** Magnified view of H&E stain of the tumour demonstrating glandular features with surrounding inflammatory infiltrates.

associated with a survival benefit when compared with chemotherapy alone.<sup>5</sup> This practice, however, remains limited consistent with the 2016 guidelines from the European Society for Medical Oncology and their recommended chemotherapy regimen for locally advanced biliary tract cancers, reflect local practice in Australia as seen in this case.<sup>8</sup>

The PRODIGE12 trial also used a chemotherapy regimen similar to the one received by our patient but failed to demonstrate any survival benefit; however, this study included only 38 gallbladder carcinoma patients making it difficult to arrive at any definitive conclusion in this subset of patients.<sup>9</sup> The BILCAP study on the other hand has generated a lot of interest which used capecitabine, an oral chemotherapy agent versus observation alone in resected biliary tree cancers. The per-protocol analysis revealed significant improvements in overall survival and adjuvant capecitabine is now considered standard of care following resected biliary tree cancers in some international guidelines such as the American Society of Clinical Oncology.<sup>3 10</sup>

While an oncological resection of the gallbladder is advocated as the mainstay of treatment, there is variation in its approach, based on prior knowledge of suspected malignancy versus incidentally detected gall bladder cancers which now represent more than half of all new diagnoses.<sup>11</sup> A staging laparoscopy is advocated in cases of presumed gallbladder cancer to avoid non-therapeutic laparotomies with careful inspection to detect peritoneal or liver metastases and to evaluate suspicious lymph nodes such as the cystic node as reported in this case, as it has a positive predictive value of other involved lymph nodes within the porta hepatis as seen in our case.<sup>11</sup> While we aim for R0 resection in all cases, aggressive resection in advanced T3 and T4 lesions remains controversial, as they have been shown to increase mortality and morbidity without any survival benefit.<sup>11</sup>

In general, it is accepted that T1 and T2 tumours should undergo radical cholecystectomies with en bloc resection of adjacent liver and portal lymphadenectomy.<sup>11</sup> Lymphadenectomy is considered routine in tumour stages >T1b and confers a survival benefit over radical cholecystectomy alone without lymphadenectomy.<sup>11</sup> While studies have demonstrated that assessment of at least six lymph nodes within the porta hepatis is required for adequate staging, this is often not attained as seen in this case.<sup>8</sup>

A literature review of similar cases yielded some case reports and retrospective studies which were consistent with prior reports<sup>5</sup> of poor survival associated with advanced age, positive lymph node status and positive surgical margins (table 1).

This case highlights the challenges encountered in managing a rare form of cancer and the role played by the MDT approach.

Table 1 Literature review of similar cases published since 2015							
Author and year of publication	Country	Gender	Age	Stage of disease	Surgical margins	Adjuvant/ neoadjuvant therapy	Outcomes
Mandal (2021) <sup>13</sup>	USA	Female	76	T4N0M0	NA	Neoadjuvant chemo	Palliated death
Akce (2019) retrospective analysis of National Database from 2004 to 2013 <sup>14</sup>	USA	70 male 146 female (data available for 175 patients)	67 (median)	106 with T3 disease, 14 with T4 disease, 119 with N1 and 4 with M1 disease	69 involved margin and 98 clear margins	4 patients with neoadjuvant and 77 patients with adjuvant therapy	12 months survival 34.5% 60 months survival 13.9%
Gyawali (2023) <sup>15</sup>	Nepal	Female	70	T2bN1	Clear margins	Not stated	Alive 2 years postoperative
Tidjane (2022) <sup>16</sup>	Algeria	Female	82	T2bN1M0	Clear margins	Oral adjuvant chemo	Alive at 2 years postoperative
NA, not available.							

## Case report

As in other malignancies, the MDT approach has been shown to improve outcomes in gallbladder carcinomas by streamlining radiological investigations, recommendations on surgical management and appropriateness of adjuvant therapy on a case by case basis.<sup>12</sup> Studies have identified variations in outcomes following R0 resections in adenosquamous versus pure squamous cell gall bladder carcinomas,<sup>4</sup> and therefore, further studies are required to address optimum treatment and management.

### Patient's perspective

I was very surprised to hear how rare my condition is and how lucky I have been in attaining this outcome. I will forever be indebted to the excellent care provided by my doctors, nurses and allied health staff who have been involved in my care and I wish to learn about how my journey compared to others with the same diagnosis.

### Learning points

- Adenosquamous carcinomas of the gallbladder represent a minority of all gallbladder malignancies.
- A multidisciplinary team approach should be employed to improve patient outcomes by careful planning and optimisation of preoperative investigations and treatment.
- Further research will likely guide changes in guidelines and local practice regarding the optimum adjuvant strategies in this subset of patients algorithm based on histological subtypes.

**Contributors** MAZ acquired patient consent, creation and publication of manuscript. CLT (clinical supervisor) was responsible for oversight, proof reading and editing of manuscript prior to submission.

**Funding** The authors have not declared a specific grant for this research from any funding agency in the public, commercial or not-for-profit sectors.

**Competing interests** None declared.

**Patient consent for publication** Consent obtained directly from patient(s).

**Provenance and peer review** Not commissioned; externally peer reviewed.

**Open access** This is an open access article distributed in accordance with the Creative Commons Attribution Non Commercial (CC BY-NC 4.0) license, which permits others to distribute, remix, adapt, build upon this work non-commercially, and license their derivative works on different terms, provided the original work

is properly cited and the use is non-commercial. See: <http://creativecommons.org/licenses/by-nc/4.0/>.

Case reports provide a valuable learning resource for the scientific community and can indicate areas of interest for future research. They should not be used in isolation to guide treatment choices or public health policy.

### ORCID iD

Muhammed Ali Zishan <http://orcid.org/0000-0003-3092-0791>

### REFERENCES

- 1 Mollah T, Chia M, Wang LC. Epidemiological trends of gallbladder cancer in Australia between 1982 to 2018: a population-based study utilizing the Australian cancer database. *Ann Hepatobiliary Pancreat Surg*.
- 2 Davis T, Moudy P, Abdelgawad M, et al. Gallbladder Adenosquamous carcinoma: A case report and literature review. *J Surg Case Rep* 2021;2021:rjab365.
- 3 Gamboa AC, Maithel SK. The landmark series: gallbladder cancer. *Ann Surg Oncol* 2020;27:2846–58.
- 4 Leigh N, Solomon D, Pletcher E, et al. Adeno-squamous and squamous cell carcinoma of the gallbladder: the importance of histology in surgical management. *The American Journal of Surgery* 2020;220:1242–8.
- 5 Murimwa G, Hester C, Mansour JC, et al. Comparative outcomes of adenosquamous carcinoma of the gallbladder: an analysis of the National cancer database. *Journal of Gastrointestinal Surgery* 2021;25:1815–27.
- 6 Kim WS, Jang KT, Choi DW, et al. Clinicopathologic analysis of Adenosquamous/ squamous cell carcinoma of the gallbladder. *J Surg Oncol* 2011;103:239–42.
- 7 Kim HS, Han Y, Kang JS, et al. Serum Carcinoembryonic antigen and carbohydrate antigen 19-9 as preoperative diagnostic biomarkers of extrahepatic bile duct cancer. *BJS Open* 2021;5:zrab127.
- 8 Valle JW, Borbath I, Khan SA, et al. Biliary cancer: ESMO clinical practice guidelines for diagnosis, treatment and follow-up. *Annals of Oncology* 2016;27:v28–37.
- 9 Edeline J, Benabdelghani M, Bertaut A, et al. Gemcitabine and oxaliplatin chemotherapy or surveillance in resected biliary tract cancer (PRODIGE 12-ACCORD 18-UNICANCER G1): a randomized phase III study. *JCO* 2019;37:658–67.
- 10 Primrose JN, Fox RP, Palmer DH, et al. Capecitabine compared with observation in Resected biliary tract cancer (BILCAP): A randomised, controlled, Multicentre, phase 3 study. *Lancet Oncol* 2019;20:S1470-2045(18)30915-X:663–73..
- 11 Hickman L, Contreras C. Gallbladder cancer: Diagnosis, surgical management, and adjuvant therapies. *Surg Clin North Am* 2019;99:S0039-6109(18)30178-6:337–55..
- 12 Chan BKY, Carrion-Alvarez L, Telfer R, et al. Surgical management of suspected gallbladder cancer: The role of intraoperative frozen section for diagnostic confirmation. *J Surg Oncol* 2022;125:399–404.
- 13 Mandal S, Ponnekanti SK, Dadeboyina C, et al. A case report on adenosquamous carcinoma of gallbladder: a very rare malignancy. *Cureus* 2021;13:e15791.
- 14 Akce M, Zakka K, Penley M, et al. Clinicopathological features and survival outcomes of rare histologic variants of gallbladder cancer. *J Surg Oncol* 2020;121:294–302. Available <https://onlinelibrary.wiley.com/doi/10.1002/jso.25121>
- 15 Gyawali S, Pokhrel B, Sharma D, et al. Adenosquamous carcinoma of gallbladder with unusual prognosis: a case report. *J Nepal Med Assoc* 2023;61:76–9.
- 16 Tidjane A, Boudjenan-Serradj N, Khalifa S, et al. Adenosquamous carcinoma of gallbladder associated with biliopancreatic maljunction and Todani 1c choledochal cyst: a case report. *Adv in Digestive Medicine* 2022;6.

Copyright 2023 BMJ Publishing Group. All rights reserved. For permission to reuse any of this content visit <https://www.bmj.com/company/products-services/rights-and-licensing/permissions/> BMJ Case Report Fellows may re-use this article for personal use and teaching without any further permission.

Become a Fellow of BMJ Case Reports today and you can:

- Submit as many cases as you like
- Enjoy fast sympathetic peer review and rapid publication of accepted articles
- Access all the published articles
- Re-use any of the published material for personal use and teaching without further permission

### Customer Service

If you have any further queries about your subscription, please contact our customer services team on +44 (0) 207111 1105 or via email at [support@bmj.com](mailto:support@bmj.com).

Visit [casereports.bmj.com](http://casereports.bmj.com) for more articles like this and to become a Fellow