

Giant acquired digital fibrokeratoma

Arun Inamadar ,¹ Sharad Mutalik²

¹Department of Dermatology, Venereology & Leprosy, Shri BM Patil Medical College, Bijapur, India

²Department of Dermatology, Venereology & Leprosy, Joshi Hospital, Pune, Maharashtra, India

Correspondence to

Dr Arun Inamadar;
aruninamadar@gmail.com

Accepted 26 January 2023

DESCRIPTION

A man in his 50s presented to the dermatology outpatient department with a painless skin-coloured exophytic horn-like growth arising from the dorsal surface of the left index finger. It measured 3.5 cm in length with a broad base of 1.5 cm in diameter (figure 1). The growth had a characteristic hyperkeratotic collarette at its base. There was no history of any local factors like trauma or irritation. A clinical diagnosis of giant acquired digital fibrokeratoma (GADFK) was made. Surgical excisional biopsy is performed as both a diagnostic and therapeutic procedure. Histopathology examination revealed a digitate lesion, composed of massive hyperkeratosis, acanthosis, a core of thick collagen bundles and vertically oriented small dermal blood vessels suggestive of ADFK (figure 2). Neural structures were absent and lacked adnexal structures, ruling out the possibility of the supernumerary digit. The final diagnosis of giant ADFK was confirmed because of the size of more than 1 cm and histology.

ADFKs are benign, solitary, hyperkeratotic well-defined papules in digitate form looking like horns with a collarette of skin at its base. The lesions are usually dome-shaped, although they may present as elongated finger-like projections, as in the index case.^{1,2} Common sites of occurrence are on fingers and toes but can also

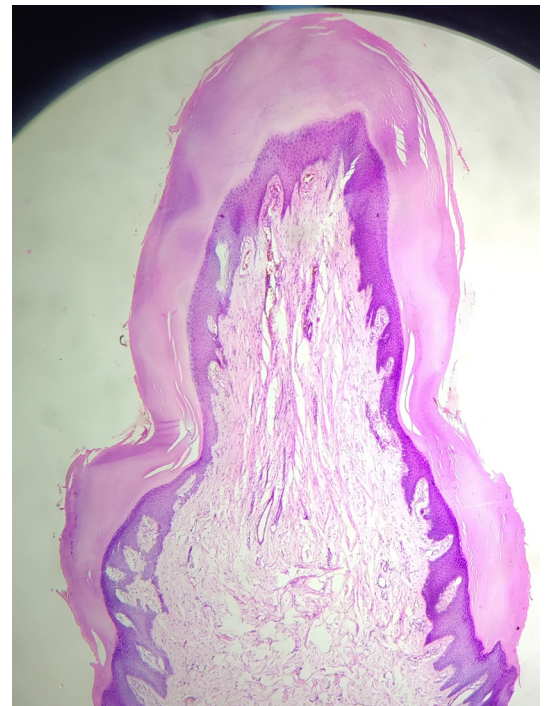


Figure 2 Hematoxylin and eosin stain reveals a digitate shaped, hyperkeratotic and acanthotic pedunculated lesion with peripheral collarette. The core is composed of dense collagen bundles, numerous capillaries and fibroblasts (original magnification, 5×).

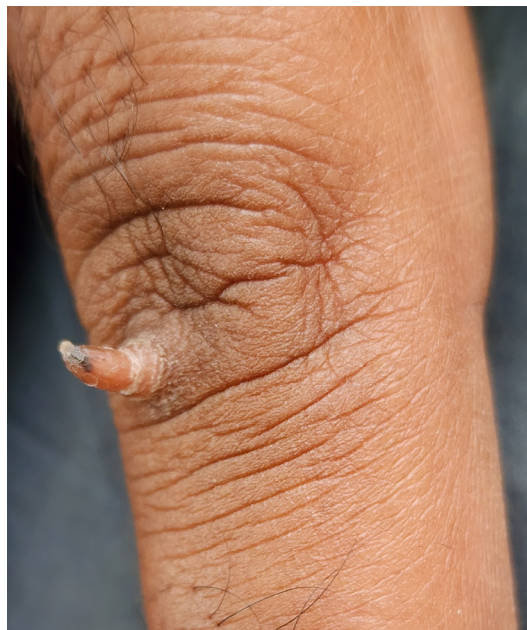

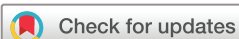Figure 1 Horn-like growth arising from the dorsal surface of the left index finger with hyperkeratotic collarette at its base.

be seen on the lower lip, nose, elbow, prepatellar area and periungual tissue. The size of the lesion is generally less than 1 cm, but there are reported cases of ADFK of more than 1 cm. These lesions are designated as GADFKs as in the index.²

The differential diagnosis of ADFK includes supernumerary digit, verrucae vulgaris, cutaneous horn, neurofibroma and pyogenic granuloma. Table 1 depicts the common conditions to be considered as differential diagnosis with their clinical characteristics and management.³⁻⁵

ADFK are usually asymptomatic but may be painful when traumatised. They are benign tumours with no risk of malignant transformation. They may affect the function of the digit and require removal. Surgical excision, cryotherapy, shave excision, curettage and cautery are all reported as treatment options. Excellent functional recovery with a satisfying cosmetic result is the expectation after complete surgical treatment. Usually, there is no recurrence.⁶

Classical collarette of skin at its base and specific histology helps in the diagnosis of ADFK.



© BMJ Publishing Group Limited 2023. No commercial re-use. See rights and permissions. Published by BMJ.

To cite: Inamadar A, Mutalik S. *BMJ Case Rep* 2023;**16**:e254499. doi:10.1136/bcr-2022-254499

Table 1 Differential diagnosis for ADFK

Condition	Differentiating points	Management
Supernumerary digit	Usually found at the base of the fifth finger. Histology shows—neural bundles and neuroid elements	Surgical excision
Verrucae vulgaris	Tiny black dots on the wart surface, especially after paring the surface.	Cauterization—chemical, electrical, radiofrequency cauterisation (RFC) Topical : Five fluoro uracil (FFU), Retinoid Cryosurgery
Cutaneous horn	Conical projection above the surface of the skin. Typically occurs in sun exposed areas. Actinic keratoses are the most common premalignant primary cause of cutaneous horn.	Surgical excision, RFC, treating the underlying cause
Cutaneous neurofibroma	Skin coloured soft, polypoid or dome-shaped nodule	Counselling about the benign nature of the disease
Pyogenic granuloma	Solitary, rapidly growing, friable, dome-shaped or pedunculated, papule or polyp; easily bleed with minor trauma	Topical TCA, eCo3 laser, cryosurgery
Koenen’s tumour (periungual fibroma)	Digitated or polypoid growths with glove-clove-like, globoid, fusiform, or vermiform shapes	Counselling about the benign nature of the disease
Non-pigmented eccrine poroma	Skin-coloured or pink papule, plaque or nodule; occurs in the palms or side of feet	Surgical excision
Aggressive papillary digital adenocarcinoma	Skin-coloured or tan-brown to grey papule or nodule	Surgery

ADFK, acquired digital fibrokeratoma .

Learning points

- ▶ Classical clinical finding of collarette of skin at its base and specific histology helps in the diagnosis of acquired digital fibrokeratoma (ADFK).
- ▶ ADFK is a benign tumour with no risk of malignant transformation.
- ▶ Excellent functional recovery with a satisfying cosmetic result is the expectation after complete surgical treatment.

Contributors All contributed for manuscript writing and SM for literature survey.

Funding The authors have not declared a specific grant for this research from any funding agency in the public, commercial or not-for-profit sectors.

Competing interests None declared.

Patient consent for publication Consent obtained directly from patient(s)

Provenance and peer review Not commissioned; externally peer reviewed.

Case reports provide a valuable learning resource for the scientific community and can indicate areas of interest for future research. They should not be used in isolation to guide treatment choices or public health policy.

ORCID iD

Arun Inamadar <http://orcid.org/0000-0002-8877-3723>

REFERENCES

- 1 Al-Atif HM. Giant acquired acral fibrokeratoma: a case report. *Dermatol Reports* 2019;11:8215.
- 2 Choi JH, Jung SY, Chun JS, et al. Giant acquired digital fibrokeratoma occurring on the left great toe. *Ann Dermatol* 2011;23:64–6.
- 3 Longhurst WD, Khachemoune A. An unknown mass: the differential diagnosis of digit tumors. *Int J Dermatol* 2015;54:1214–25.
- 4 Shih S, Khachemoune A. Acquired digital fibrokeratoma: review of its clinical and dermoscopic features and differential diagnosis. *Int J Dermatol* 2019;58:151–8.
- 5 Berger RS, Spielvogel RL. Dermal papule on a distal digit. acquired digital fibrokeratoma. *Arch Dermatol* 1988;124:1559–60.
- 6 Shelley WB, Phillips E. Recurring accessory “ fingernail ”: periungual fibrokeratoma. *Cutis* 1985;35:451–4.

Copyright 2023 BMJ Publishing Group. All rights reserved. For permission to reuse any of this content visit <https://www.bmj.com/company/products-services/rights-and-licensing/permissions/>
BMJ Case Report Fellows may re-use this article for personal use and teaching without any further permission.

Become a Fellow of BMJ Case Reports today and you can:

- ▶ Submit as many cases as you like
- ▶ Enjoy fast sympathetic peer review and rapid publication of accepted articles
- ▶ Access all the published articles
- ▶ Re-use any of the published material for personal use and teaching without further permission

Customer Service

If you have any further queries about your subscription, please contact our customer services team on +44 (0) 207111 1105 or via email at support@bmj.com.

Visit casereports.bmj.com for more articles like this and to become a Fellow