

# Insect wing case corneal foreign body: ASOCT-based findings

Rinky Agarwal <sup>1</sup>, Neeti Rana,<sup>2</sup> Sarita Beri,<sup>3</sup> Om Prakash<sup>3</sup>

<sup>1</sup>Ophthalmology, All India Institute of Medical Sciences, New Delhi, India

<sup>2</sup>Ophthalmology, Lady Hardinge Medical College, New Delhi, India

<sup>3</sup>Department of Ophthalmology, Lady Hardinge Medical College, New Delhi, India

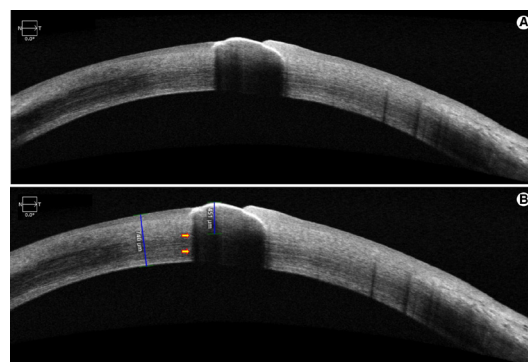
**Correspondence to**  
Dr Rinky Agarwal;  
rinky.1990@gmail.com

Accepted 16 August 2022

## DESCRIPTION

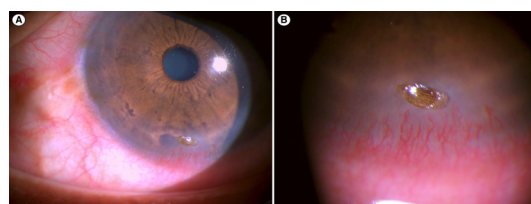
A man in mid-50s noticed mild irritation in right eye for 10 days following ocular trauma with an unknown insect 1 month ago. His visual acuity was 20/20 in both eyes. Slit lamp examination of left eye revealed an elevated lesion with oval shape, brown colour, well-defined margins and corrugated surface in inferior cornea. It was relatively translucent, and rigid shell-like, with a convex outer surface that had a waxy coating resembling the exoskeleton of insects ([figure 1](#)). It was associated with surrounding stromal infiltration and vascularisation. On fluorescence staining, dye gathered around the edges of the lesion with no epithelial defect. There was no associated conjunctival discharge, forniceal foreign body (FB) or anterior chamber reaction. A diagnosis of insect wing case (IWC) corneal FB (CFB) was made. Anterior segment optical coherence tomography (ASOCT, Cirrus, Carl Zeiss, Meditec, Germany) revealed a crescent-shaped concavo-convex surfaced hyper-reflective FB with sharp well-defined margins in the anterior cornea with shadowing of underlying structures. Central shadowing was noted beyond 451 µm of stromal thickness and marginal shadowing was noted underneath one edge of CFB ([figure 2](#)). It was removed with McPherson forceps on slit-lamp under topical anaesthesia and topical moxifloxacin (0.5%) was administered 6hourly for 5 days following which the site healed with minimal scarring. CFB revealed no microbiological growth.

IWCs are rarely described CFBs, last reported by Fogla *et al* in the month of November and December due to seasonal variation in the insect population.<sup>1</sup> The authors suggested that the firm adhesion of this convexoconcave FB on convex ocular surface could be due to vacuum created by the pressure of eyelid on the FB. As IWCs may cause corneal infiltration, neovascularisation and infective keratitis, they should be removed immediately and subjected to microbiological evaluation.



**Figure 2** ASOCT findings of insect wing case corneal foreign body (A, B), yellow arrows indicate marginal shadowing. ASOCT, anterior segment optical coherence tomography.

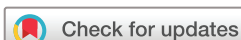ASOCT, a valuable non-invasive tool that provides high resolution details of anterior segment structures, is known to aid in diagnosis of CFB and in guiding an appropriate method of its removal.<sup>2,3</sup> Metallic CFBs may be deposited either superficially or deeply into the corneal stroma (due to their high velocity), are hyper-reflective on ASOCT and cause mirroring and shadowing effect on underlying structures, while organic FBs remain lodged superficially (due to their low velocity) and few organic CFBs such as hairy chestnut spines may not be detectable on ASOCT.<sup>3</sup> To the best of our knowledge, this is the first time, ASOCT is being used for imaging IWC. We noted localised shadowing of corneal details underlying the IWC. We also noted marginal shadowing under one edge of CFB. These findings are very similar to the those reported by Wang *et al* in their case 3, where a translucent brown shell CFB was identified clinically, and on ASOCT, a crescent-shaped low reflective signal with bilateral marginal zone shadowing 21 µm below the epithelium surface was noted. Although the beginning of shadowing usually indicates the



**Figure 1** Slit-lamp photograph of insect wing case corneal foreign body (A, B).

## Learning points

- ▶ Insect wing case can rarely present as superficial corneal foreign body and cause mild ocular irritation.
- ▶ Anterior segment optical coherence tomography demonstrates crescent shaped hyper-reflective foreign body with central shadowing and one-sided marginal shadowing of structures underlying foreign body.



© BMJ Publishing Group Limited 2022. No commercial re-use. See rights and permissions. Published by BMJ.

**To cite:** Agarwal R, Rana N, Beri S, *et al*. *BMJ Case Rep* 2022;**15**:e251578. doi:10.1136/bcr-2022-251578

inferior margin of CFB, thus determining its depth, it may sometimes conceal underlying corneal thinning or perforation and, tissue adhesives may be needed in reserve, based on clinical discretion of the ophthalmologist. ASOCT may also aid in differentiating IWCs from other brown-coloured lesions such as uveal tissue prolapse or ocular surface neoplasia.

To conclude, specific details such as crescent-shaped concavo-convex surfaced sharply defined hyper-reflective FB in the anterior cornea with localised central shadowing and marginal shadowing of underlying structures as visualised on ASOCT may aid in diagnosis and management of IWC CFB.

**Contributors** RA: patient care, manuscript writing, NR: data acquisition, patient care, SB: manuscript editing, OP: manuscript editing.

**Funding** The authors have not declared a specific grant for this research from any funding agency in the public, commercial or not-for-profit sectors.

**Competing interests** None declared.

**Patient consent for publication** Consent obtained directly from patient(s)

**Provenance and peer review** Not commissioned; externally peer reviewed.

Case reports provide a valuable learning resource for the scientific community and can indicate areas of interest for future research. They should not be used in isolation to guide treatment choices or public health policy.

#### ORCID iD

Rinky Agarwal <http://orcid.org/0000-0002-4576-4915>

#### REFERENCES

- 1 Fogla R, Rao SK, Anand AR, *et al.* Insect wing case: unusual foreign body. *Cornea* 2001;20:119–21.
- 2 Wang T, Zhong L, Yin S, *et al.* Comparison of different types of corneal foreign bodies using anterior segment optical coherence tomography: a prospective observational study. *J Ophthalmol* 2020;2020:1–7.
- 3 Akbaş E, Barut Selver Özlem, Palamar M. Retrospective evaluation of corneal foreign bodies with anterior segment optical coherence tomography. *Turk J Ophthalmol* 2021;51:265–8.

Copyright 2022 BMJ Publishing Group. All rights reserved. For permission to reuse any of this content visit <https://www.bmj.com/company/products-services/rights-and-licensing/permissions/>  
BMJ Case Report Fellows may re-use this article for personal use and teaching without any further permission.

Become a Fellow of BMJ Case Reports today and you can:

- ▶ Submit as many cases as you like
- ▶ Enjoy fast sympathetic peer review and rapid publication of accepted articles
- ▶ Access all the published articles
- ▶ Re-use any of the published material for personal use and teaching without further permission

#### Customer Service

If you have any further queries about your subscription, please contact our customer services team on +44 (0) 207111 1105 or via email at [support@bmj.com](mailto:support@bmj.com).

Visit [casereports.bmj.com](http://casereports.bmj.com) for more articles like this and to become a Fellow