



OPEN ACCESS

Successful use of stellate ganglion phototherapy in refractory ventricular tachycardia in a patient with cardiac sarcoidosis

Subaru Tanabe, Yusuke Nakano , Yasushi Suzuki, Tetsuya Amano

► Additional supplemental material is published online only. To view, please visit the journal online (<http://dx.doi.org/10.1136/bcr-2022-249183>).

Department of Cardiology, Aichi Medical University, Nagakute, Aichi, Japan

Correspondence to

Dr Yusuke Nakano;
nakanoy@aichi-med-u.ac.jp

Accepted 12 July 2022

SUMMARY

Ventricular arrhythmias are a life-threatening factor in cardiac sarcoidosis (CS), posing a significant therapeutic challenge. Stellate ganglion phototherapy (SGP), a non-invasive procedure for modification of the sympathetic nervous system, is an effective treatment for refractory ventricular tachycardia (RVT). However, there are limited data on the efficacy of SGP for RVT in patients with CS. In our case report, we found that SGP was effective for treating RVT in a patient with CS.

We present the case of a man in his 60s with multiple cardioversions of implantable cardioverter defibrillator for ventricular tachycardia. The patient was administered prednisolone for the management of CS, which subsequently led to an increase in anti-tachycardia pacing for ventricular tachycardias. We introduced SGP to suppress RVT and anti-tachycardia pacing decreased from 371 to 25 events. Thus, SGP could be a feasible option for the management of RVT in patients with CS.

BACKGROUND

Cardiac sarcoidosis (CS) is a disease with inflammatory granulomatous cardiac involvement of unknown aetiology.¹ Ventricular arrhythmias are one of the life-threatening factors that pose a significant therapeutic challenge in patients with CS, especially when they are incessant and recurrent.² Standard therapeutic options, including antiarrhythmic drugs, catheter ablation or both, are used for the management of ventricular arrhythmias in patients with CS.^{1 3 4} However, even with a combination of therapies, ventricular arrhythmias recur in about half of the cases.⁴⁻⁶ Therefore, in the setting of failed catheter ablation and medical therapies, additional treatment options are required to treat patients with CS with ventricular arrhythmias.

The cardiac sympathetic nervous system plays an important role in ventricular arrhythmogenesis.⁷ Therefore, neuromodulation therapies via the stellate ganglion, such as surgical stellate ganglion denervation, stellate ganglion block with local anaesthetics and stellate ganglion block with thoracic epidural anaesthesia, have been used to manage refractory ventricular tachycardias (RVTs).⁸⁻¹⁰ In addition, the efficacy of stellate ganglion phototherapy (SGP) in suppressing RVTs was recently reported.^{11 12} SGP is a non-invasive procedure for modification of the sympathetic nervous system, which can be applied in patients with a high risk of bleeding or severe conditions.^{11 12} However, data

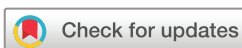on the efficacy of SGP for RVT in patients with CS are limited. The purpose of this study is to report a case of RVT in a patient with CS who was successfully treated with SGP.

CASE PRESENTATION

A man in his 60s with implantable cardioverter defibrillator (ICD) shock for ventricular tachycardia (VT) was admitted to our hospital. One year before admission, the patient developed sick sinus syndrome and VT due to non-ischaemic cardiomyopathy. Consequently, an ICD was implanted, and he was treated with 100 mg amiodarone (AMD) and 2.5 mg bisoprolol daily. There were no incidences of ICD shocks after ICD implantation, except for a few occasions of anti-tachycardia pacing (online supplemental figure 1).

ECG revealed a heart rate of 60 beats per minute (bpm), the QRS and QT intervals were within normal limits. Transthoracic echocardiography revealed diffuse, severely reduced left ventricular function (ejection fraction, approximately 35%) and the aneurysmal wall in the left inferior ventricle (figure 1). The laboratory test results were within the normal ranges, including a serum potassium level of 4.7 mmol/L and thyroid function. However, brain natriuretic peptide levels were elevated to 156 pg/mL due to decreased cardiac function.

After admission, AMD and bisoprolol were administered as first-line therapy for VT; doses were increased to 200 mg/day and 5.0 mg/day, respectively, and changes in the cardiac pacemaker backup rate were recorded a shift from 50 to 70 bpm. The cause of non-ischaemic cardiomyopathy was diagnosed as CS based on the following diagnostic criteria of the Japanese Circulation Society 2016¹³: (1) fatal ventricular arrhythmia, (2) abnormal ventricular wall anatomy (ventricular aneurysm), (3) left ventricular contractile dysfunction (left ventricular ejection fraction <50%) and (4) ¹⁸F-fluorodeoxyglucose positron emission tomography reveals abnormally high tracer accumulation in the heart. Prednisolone at 30 mg/day was initiated on day 8, as corticosteroid therapy is recommended in cases of CS.¹³ However, following corticosteroid therapy, the patient frequently suffered from multiple anti-tachycardia pacing for non-sustained VTs, which caused general malaise. Corticosteroid therapy for CS was considered as a possible trigger for VT and the treatment was discontinued. No



© BMJ Publishing Group Limited 2022. Re-use permitted under CC BY-NC. No commercial re-use. See rights and permissions. Published by BMJ.

To cite: Tanabe S, Nakano Y, Suzuki Y, et al. *BMJ Case Rep* 2022;**15**:e249183. doi:10.1136/bcr-2022-249183

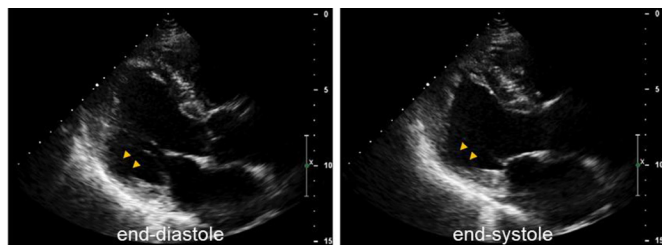


Figure 1 Echocardiographic findings. Transthoracic echocardiography in left ventricular long-axis view reveals an aneurysm with a wall thickness of 4.0mm on the inferior wall (yellow arrow). Left ventricular function is severely decreased with a left ventricular end-diastolic dimension of 55 mm (left panel) and a left ventricular end-systolic dimension of 46.5 mm (right panel). No valvular disease is observed.

other immunosuppressive drugs were initiated out of concern for avoiding drug-induced VT. Although three-dimensional endocardial mapping was performed, the VT circuit was not revealed. Additional epicardial mapping was avoided because the investigators did not have enough experience with epicardial ablation. The patient was treated with sotalolol 160 mg/day but continued to suffer from repeated VTs after catheter ablation (figures 2 and 3).

TREATMENT

SGP, a non-invasive technique when compared with the traditional stellate ganglion blockade, was performed for the treatment of RVTs. SGP was performed under local anaesthesia on bilateral satellite ganglions for 7 min on each side (figure 4). Treatment was commenced on day 29 and was continued until cardiac symptomatic nervous activation was suppressed.

OUTCOME AND FOLLOW-UP

After SGP therapy, incessant VTs were significantly reduced without any further complications, such as Horner’s syndrome and vagal or laryngeal recurrent nerve blockades. Subsequently, the frequency of anti-tachycardia pacing therapy decreased from 371 to 25 times. Consequently, palpitations and general malaise improved. The patient was discharged on day 49 without any symptoms (figure 2).

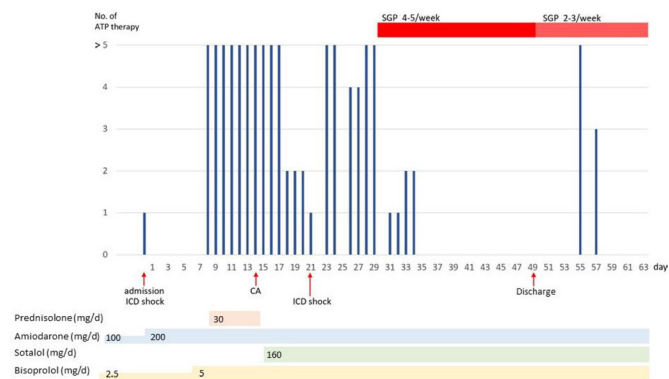


Figure 2 Clinical course before and after SGP. Medical therapies and catheter ablation were insufficient to suppress VT. After initiation of SGP, stimulations by ATP therapy significantly decreased from 371 times before SGP to 25 times. ATP, anti-tachycardia pacing; CA, catheter ablation; ICD, implantable cardioverter defibrillator; SGP, stellate ganglion phototherapy; VT, ventricular tachycardia.

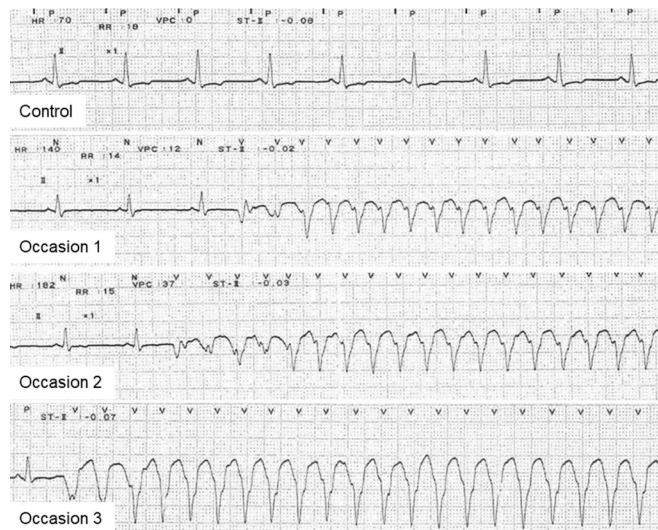


Figure 3 Incessant VT during hospitalisation. ECG monitoring at different occasions shows frequent incessant VTs (approximately 180 bpm). The top ECG strip shows the sinus rhythm. bpm, beats per minute; VT, ventricular tachycardia.

Two episodes of anti-tachycardia pacing recurred after the discontinuation of SGP following discharge. Hence, SGP was re-initiated two or three times a week. No further episodes of ICD shocks or anti-tachycardia pacing occurred. Thus, sotalolol was discontinued, and amiodarone was reduced to 100 mg/day. Hereafter, the initiation of immunosuppressive drugs is considered for the basic treatment of CS.

DISCUSSION

This is the first report describing a case of RVT in a patient with CS who was successfully treated with modification of the sympathetic nervous system using SGP.

Corticosteroid therapy and catheter ablation have been reported to have beneficial effects on ventricular arrhythmias

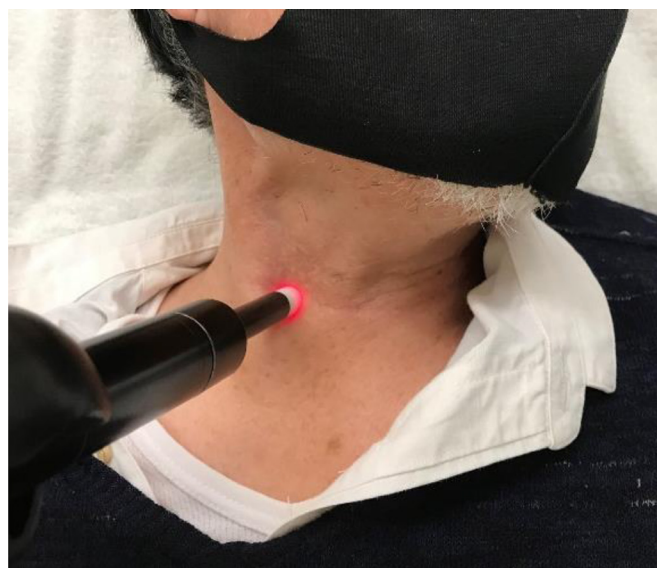

Figure 4 SGP using linearly polarised near-infrared light. A linear polarised light instrument, the Super Lizer, was used to irradiate the stellate ganglion located between the C7 and T1 vertebral bodies on both sides for 7 min per side. SGP, stellate ganglion phototherapy.

in patients with CS, but their limitations have also been discussed.^{3,4} The disease process in CS is considered to be a combination of active phase inflammation and chronic phase fibrosis.⁴ Triggered activity or abnormal automaticity associated with disease inflammation in the active phase may lead to ventricular arrhythmia.^{4,14} Therefore, corticosteroid therapy has been reported to have a beneficial effect on ventricular arrhythmias by suppressing disease inflammation in patients with CS.^{3,4} However, corticosteroid was also reported to increase the burden of ventricular arrhythmias,^{15–17} and this mechanism is poorly understood. In contrast, during the chronic phase, it is likely that macro re-entry circuits around cardiac scarring cause VT.^{5,6} Cardiac scarring has been reported to extend not only to the endocardium, including the left and right ventricles, but also to the epicardium,¹⁴ which may be challenging to ablate in ill-equipped facilities.

Ventricular arrhythmogenesis is often associated with the sympathetic nervous system.⁷ SGP, a neuromodulation therapy that non-invasively suppresses sympathetic neurological activity, is reported to be effective for RVT.^{11,12} The stellate ganglion, which is the therapeutic target of neuromodulation therapies, is located in the intervertebral space between the C7 and T1 vertebral bodies.¹⁸ It is irradiated through the skin surface using a phototherapy treatment device: Super Lizer, (Tokyo Iken Co), which uses linearly polarised near-infrared light with high magnetic permeability.¹¹ The wavelength band is 600–1600 nm, which allows the non-invasive penetration of light into the tissues to inhibit sympathetic neurological activity without any other nerve blockades.¹¹ Although SGP has been shown to have an antiarrhythmic effect on RVT in dilated cardiomyopathy or ischaemic cardiomyopathy,^{11,12} limited data are available regarding patients with CS.

In the present case of CS, ventricular arrhythmias increased immediately after the initiation of corticosteroid therapy, the standard therapy for CS. Therefore, steroid treatment is potentially a significant cause of ventricular arrhythmias. Catheter ablation of the endocardium did not suppress RVT, which suggests that the critical conduction pathway of VT extended to the epicardial muscle. Due to certain technical difficulties in treatment, additional ablation was not performed. Despite such a challenging case, successful non-invasive treatment of RVT was achieved with bilateral SGP.

In conclusion, we present a case of RVT in a patient with CS who was successfully treated by SGP, which is a non-invasive modification therapy of the sympathetic nervous system. SGP could be a key therapeutic option for the management of RVTs in patients with CS. Nevertheless, further studies are required to clarify these effects.

Learning points

- ▶ Corticosteroids and catheter ablation may not always be sufficiently effective for managing ventricular tachycardia in patients with cardiac sarcoidosis.
- ▶ Neuromodulation therapies via the stellate ganglion can be effective for the treatment of refractory ventricular tachycardia.
- ▶ Stellate ganglion phototherapy, a non-invasive neuromodulation therapy that suppresses sympathetic neurological activity, could be a key therapeutic option in the management of refractory ventricular tachycardia in patients with cardiac sarcoidosis.

Twitter Yusuke Nakano @Oskey59035187

Contributors All authors have contributed equally to the scientific content of this work and have edited the manuscript appropriately. ST and YN—analysis and interpretation of patient's data, conception and design, and drafting of the manuscript critically. These authors contributed equally to the study. YS—analysis and interpretation of patient's data and drafting of the manuscript critically. TA—revising the manuscript and final approval of the manuscript submitted.

Funding The authors have not declared a specific grant for this research from any funding agency in the public, commercial or not-for-profit sectors.

Competing interests None declared.

Patient consent for publication Obtained.

Provenance and peer review Not commissioned; externally peer reviewed.

Supplemental material This content has been supplied by the author(s). It has not been vetted by BMJ Publishing Group Limited (BMJ) and may not have been peer-reviewed. Any opinions or recommendations discussed are solely those of the author(s) and are not endorsed by BMJ. BMJ disclaims all liability and responsibility arising from any reliance placed on the content. Where the content includes any translated material, BMJ does not warrant the accuracy and reliability of the translations (including but not limited to local regulations, clinical guidelines, terminology, drug names and drug dosages), and is not responsible for any error and/or omissions arising from translation and adaptation or otherwise.

Open access This is an open access article distributed in accordance with the Creative Commons Attribution Non Commercial (CC BY-NC 4.0) license, which permits others to distribute, remix, adapt, build upon this work non-commercially, and license their derivative works on different terms, provided the original work is properly cited and the use is non-commercial. See: <http://creativecommons.org/licenses/by-nc/4.0/>.

Case reports provide a valuable learning resource for the scientific community and can indicate areas of interest for future research. They should not be used in isolation to guide treatment choices or public health policy.

ORCID iD

Yusuke Nakano <http://orcid.org/0000-0002-9314-3427>

REFERENCES

- 1 Birnie DH, Nery PB, Ha AC, *et al*. Cardiac sarcoidosis. *J Am Coll Cardiol* 2016;68:411–21.
- 2 Yazaki Y, Isobe M, Hiroe M, *et al*. Prognostic determinants of long-term survival in Japanese patients with cardiac sarcoidosis treated with prednisone. *Am J Cardiol* 2001;88:1006–10.
- 3 Yalagudri S, Zhu TN, Devidutta S, *et al*. Tailored approach for management of ventricular tachycardia in cardiac sarcoidosis. *J Cardiovasc Electrophysiol* 2017;28:893–902.
- 4 Viwe M, Nery P, Birnie DH. Management of ventricular tachycardia in patients with cardiac sarcoidosis. *Heart Rhythm O2* 2021;2:412–22.
- 5 Koplan BA, Soejima K, Baughman K, *et al*. Refractory ventricular tachycardia secondary to cardiac sarcoid: electrophysiologic characteristics, mapping, and ablation. *Heart Rhythm* 2006;3:924–9.
- 6 Jelic D, Joel B, Good E, *et al*. Role of radiofrequency catheter ablation of ventricular tachycardia in cardiac sarcoidosis: report from a multicenter registry. *Heart Rhythm* 2009;6:189–95.
- 7 Shen MJ, Zipes DP. Role of the autonomic nervous system in modulating cardiac arrhythmias. *Circ Res* 2014;114:1004–21.
- 8 Bourke T, Vaseghi M, Michowitz Y, *et al*. Neuraxial modulation for refractory ventricular arrhythmias: value of thoracic epidural anesthesia and surgical left cardiac sympathetic denervation. *Circulation* 2010;121:2255–62.
- 9 Fudim M, Boortz-Marx R, Ganesh A, *et al*. Stellate ganglion blockade for the treatment of refractory ventricular arrhythmias: a systematic review and meta-analysis. *J Cardiovasc Electrophysiol* 2017;28:1460–7.
- 10 Meng L, Tseng C-H, Shivkumar K, *et al*. Efficacy of stellate ganglion blockade in managing electrical storm: a systematic review. *JACC Clin Electrophysiol* 2017;3:942–9.
- 11 Nonoguchi NM, Adachi M, Nogami A, *et al*. Stellate ganglion phototherapy using low-level laser: a novel rescue therapy for patients with refractory ventricular arrhythmias. *JACC Clin Electrophysiol* 2021;7:1297–308.
- 12 Sato T, Kamada R, Koizumi T, *et al*. Refractory ventricular tachycardia in a patient with a left ventricular assist device successfully treated with stellate ganglion phototherapy. *Can J Cardiol* 2020;36:1977.e1–1977.e3.
- 13 Terasaki F, Azuma A, Anzai T, *et al*. JCS 2016 Guideline on Diagnosis and Treatment of Cardiac Sarcoidosis - Digest Version. *Circ J* 2019;83:2329–88.

- 14 Xing D, Martins JB. Triggered activity due to delayed afterdepolarizations in sites of focal origin of ischemic ventricular tachycardia. *Am J Physiol Heart Circ Physiol* 2004;287:H2078–84.
- 15 Banba K, Kusano KF, Nakamura K, *et al.* Relationship between arrhythmogenesis and disease activity in cardiac sarcoidosis. *Heart Rhythm* 2007;4:1292–9.
- 16 Medor MC, Spence S, Nery PB, *et al.* Treatment with corticosteroids is associated with an increase in ventricular arrhythmia burden in patients with clinically manifest cardiac sarcoidosis: insights from implantable cardioverter-defibrillator diagnostics. *J Cardiovasc Electrophysiol* 2020;31:2751–8.
- 17 Yodogawa K, Seino Y, Ohara T, *et al.* Effect of corticosteroid therapy on ventricular arrhythmias in patients with cardiac sarcoidosis. *Ann Noninvasive Electrocardiol* 2011;16:140–7.
- 18 Kawashima T. The autonomic nervous system of the human heart with special reference to its origin, course, and peripheral distribution. *Anat Embryol* 2005;209:425–38.

Copyright 2022 BMJ Publishing Group. All rights reserved. For permission to reuse any of this content visit <https://www.bmj.com/company/products-services/rights-and-licensing/permissions/>
BMJ Case Report Fellows may re-use this article for personal use and teaching without any further permission.

Become a Fellow of BMJ Case Reports today and you can:

- ▶ Submit as many cases as you like
- ▶ Enjoy fast sympathetic peer review and rapid publication of accepted articles
- ▶ Access all the published articles
- ▶ Re-use any of the published material for personal use and teaching without further permission

Customer Service

If you have any further queries about your subscription, please contact our customer services team on +44 (0) 207111 1105 or via email at support@bmj.com.

Visit casereports.bmj.com for more articles like this and to become a Fellow