

# Congenital cerebriiform plaque in a newborn

Keshavmurthy A Adya , Arun Inamadar 

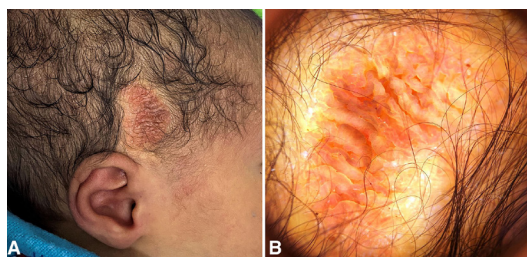
Department of Dermatology  
Venereology and Leprosy,  
Shri BM Patil Medical College,  
Bijapur, Karnataka, India

**Correspondence to**  
Dr Arun Inamadar;  
aruninamadar@gmail.com

Accepted 29 May 2022

## DESCRIPTION

A newborn boy was brought to us with a congenital hairless plaque on the right parietal scalp. Examination revealed a yellowish plaque measuring about 2×3 cm with a conspicuous brownish undulating papillomatous surface exhibiting a cerebriiform appearance (figure 1A). Rest of the cutaneous and systemic exam was normal. Dermoscopy revealed bright yellow structureless areas with thick curved pink-brown papillomatous structures and absence of terminal hairs (figure 1B). Clinical appearance was consistent with cerebriiform nevus sebaceous, which was confirmed by dermoscopy. Cerebriiform nevus sebaceous is a rare variant of nevus sebaceous presenting as yellowish-white plaque with a conspicuous cerebriiform surface. The classical form presents as a smooth yellowish-white or yellowish-orange hairless patch or slightly raised plaque in the neonatal/infantile period, which grows to assume verrucous/papillomatous surface after puberty. In contrast, the cerebriiform variant presents as a raised plaque with surface undulations resembling the surface of the brain in the neonatal stage itself. The reason for such appearance is unclear. When widespread, thorough work-up of the child may be necessary as it may be a part of linear nevus sebaceous syndrome that is associated with various systemic anomalies. Although benign in itself, secondary benign and malignant tumours are known to arise within the lesion, which may necessitate its elective removal.<sup>1</sup> The dermoscopic



**Figure 1** Yellowish plaque with brownish papillomatous surface in a cerebriiform pattern on the right parietal area (A). Dermoscopy showing bright-yellow structureless areas with thick curved pink-brown papillomatous structures and absence of terminal hairs (B) (Polarised dermoscopy (DermLite DL3, 3Gen Inc., San Juan Capistrano, CA, USA), X10).

## Learning points

- ▶ Cerebriiform nevus sebaceous is a rare variant of nevus sebaceous.
- ▶ Extensive and multidermatomal lesions may be associated with various internal anomalies.
- ▶ Use of dermoscopy in the neonatal stage provides a non-invasive confirmation of the diagnosis of this rare entity and also helps in differentiating from other lesions with similar morphology such as melanocytic nevus or verrucous epidermal nevus.

features of nevus sebaceous are fairly well characterised and depend on the stage of the lesion (yellowish or brown globules in clusters on a yellow background in the alopecic stage, and whitish-yellow lobular aspect with greyish papillary appearance in verrucous plaques).<sup>2</sup> Hence, dermoscopy allows a non-invasive confirmation of the diagnosis of this rare variant and differentiates from similar presentations such as congenital melanocytic nevus or verrucous epidermal nevus at this stage of life.

**Contributors** KAA: Literature search, analysis, processing, manuscript preparation, manuscript review. AI: Literature search, analysis, processing, manuscript preparation, manuscript review.

**Funding** The authors have not declared a specific grant for this research from any funding agency in the public, commercial or not-for-profit sectors.

**Competing interests** None declared.

**Patient consent for publication** Consent obtained from parent(s)/guardian(s)

**Provenance and peer review** Not commissioned; externally peer reviewed.

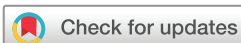Case reports provide a valuable learning resource for the scientific community and can indicate areas of interest for future research. They should not be used in isolation to guide treatment choices or public health policy.

## ORCID iDs

Keshavmurthy A Adya <http://orcid.org/0000-0003-4411-1979>  
Arun Inamadar <http://orcid.org/0000-0002-8877-3723>

## REFERENCES

- 1 Valerio E, Mardegan V, Zanella C, *et al*. Cerebriiform nevus sebaceous in a neonate. *J Pediatr* 2014;164:665–6.
- 2 Kelati A, Baybay H, Gallouj S, *et al*. Dermoscopic analysis of nevus sebaceous of Jadassohn: a study of 13 cases. *Skin Appendage Disord* 2017;3:83–91.



© BMJ Publishing Group Limited 2022. No commercial re-use. See rights and permissions. Published by BMJ.

**To cite:** Adya KA, Inamadar A. *BMJ Case Rep* 2022;15:e250974. doi:10.1136/bcr-2022-250974

Copyright 2022 BMJ Publishing Group. All rights reserved. For permission to reuse any of this content visit <https://www.bmj.com/company/products-services/rights-and-licensing/permissions/>  
BMJ Case Report Fellows may re-use this article for personal use and teaching without any further permission.

Become a Fellow of BMJ Case Reports today and you can:

- ▶ Submit as many cases as you like
- ▶ Enjoy fast sympathetic peer review and rapid publication of accepted articles
- ▶ Access all the published articles
- ▶ Re-use any of the published material for personal use and teaching without further permission

**Customer Service**

If you have any further queries about your subscription, please contact our customer services team on +44 (0) 207111 1105 or via email at [support@bmj.com](mailto:support@bmj.com).

Visit [casereports.bmj.com](http://casereports.bmj.com) for more articles like this and to become a Fellow