Managing chewing-induced oscillopsia

Sahil Agrawal , Neelam Pushker, Anju Bhari

Ophthalmology, Dr. Rajendra Prasad Centre for Ophthalmic Sciences, AIIMS, New Delhi, India

Correspondence to
Professor Neelam Pushker; pushkern@hotmail.com

Accepted 23 March 2022

DESCRIPTION

Oscillopsia is the instability of vision in which the objects in the visual field appear to oscillate, especially during movement. This may be rhythmic, and involuntary movement of the viewed world which is a frequent symptom of acquired nystagmus or it can also be voluntary and synchronous with contraction of temporalis muscle as in chewing-induced oscillopsia. We hereby demonstrate video of an unusual cause of monocular oscillopsia due to chewing induced anteroposterior displacement of the globe seen as an interesting sign in a case with surgically curable orbital tumour.

A 21-year-old man presented to the oculoplasty clinic with gradually progressive, painless protrusion of left eye for 18 months. On examination, he had a visual acuity of 6/6 in both the eye with no restriction of extraocular motility. The fundus examination was within normal limits. There was an axial proptosis of 3 mm with no palpable mass in the left eye (figure 1). A differential diagnosis on clinical examination of intraconal mass like cavernous haemangioma, schwannoma or an orbital dermoid cyst was reached.

Contrast-enhanced CT revealed a transcompartmental cystic lesion in the posterior orbit with fat density (−132 HU) measuring 2×2 cm. It was extending into infratemporal fossa through a bone defect in lateral orbital wall (greater wing of sphenoid), displacing the optic nerve (figure 2A,B). No intracranial extension was noted on MRI (figure 2C,D). Ultrasound orbit showed a heterogenous, encapsulated lesion (figure 2E).

We re-evaluated the patient. On examination, he had proptosis at rest that deteriorated during mastication. On repeated chewing movements, the eyeball was seen wobbling in anteroposterior direction. He also then gave a history that on chewing, the visual image from his left eye moved horizontally to the left and back to the right on relaxing his jaw (video 1). This phenomenon is known as chewing oscillopsia.

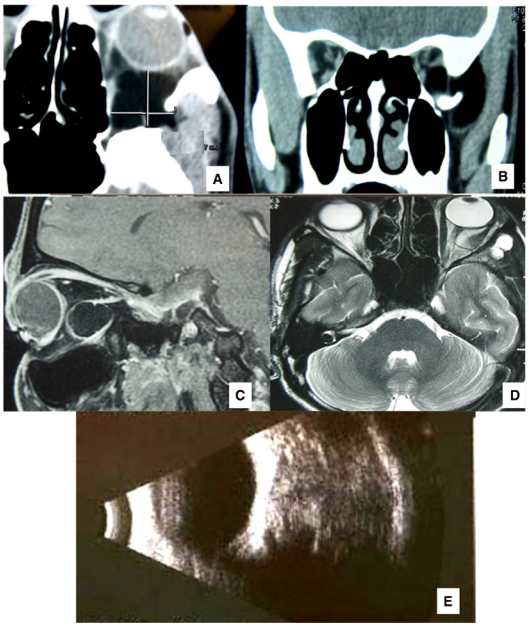

Figure 2 (A, B) Contrast-enhanced CT of left orbit showing a cystic mass lesion in posterior orbit with fat density. Mass is seen extending into infratemporal fossa through a large bone defect in lateral orbital wall; (C, D) postcontrast T1-weighted MRI showing trans compartmental fat density mass with no enhancement. T2-weighted MRI showed a well-defined hyperintense mass with fat fluid levels; (E) ultrasound of left orbit shows a heterogeneous lesion.

A diagnosis of left dumbbell dermoid cyst was reached. The patient was taken up for lateral orbitotomy with in toto excision of the cyst wall. The oscillopsia disappeared with no residual proptosis (figure 3). There has been no recurrence over 3-year follow-up.

Dermoid cysts comprise the most common orbital and periorbital tumours in infants and children, commonly localised in the frontozygomatic suture line in the periorbital region.[1 2] According to a largest reported series on dermoid cyst, dumbbell

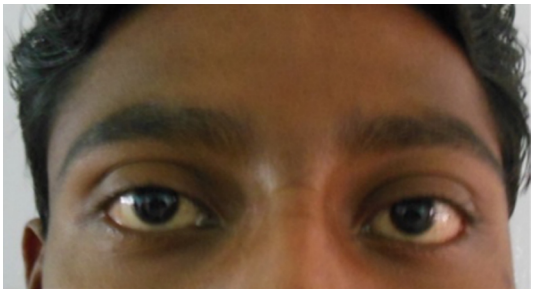

Figure 1 Preoperative photograph of the patient with left eye proptosis at rest.

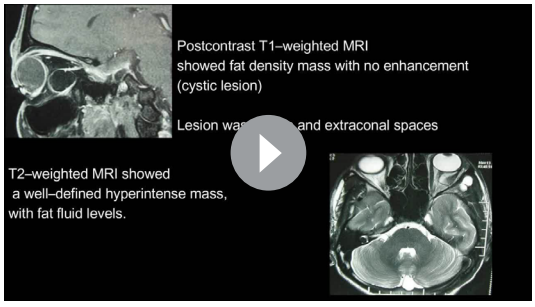

Video 1 Managing chewing-induced oscillopsia

To cite: Agrawal S, Pushker N, Bhari A. *BMJ Case Rep* 2022;**15**:e245382. doi:10.1136/bcr-2021-245382

Figure 3 Postoperative photograph shows no proptosis in the left eye.

Patient's perspective

I am happy that I don't any more have the visual problem and facial disfigurement. I am grateful to the entire team of doctors for their care.

Learning points

- Dermoid cysts may have an intraosseous or dumbbell component and a proper clinical examination including history of voluntary chewing-induced visual illusions or oscillopsia is important.
- Imaging should always be done in cases of dermoid cyst specifically to look for its dumbbell components into the temporalis fossa, intracranial cavity and the sinuses.
- The other causes of chewing-induced oscillopsia are orbitotemporal neurofibromatosis type II with a large defect in the greater wing of sphenoid, and defect in the lateral wall of orbit either due to trauma or bony opening created during lateral wall orbital decompression surgery.

dermoid cyst accounted to 5.7% of cases.[3] The prerequisite for chewing induced oscillopsia is the presence of a large defect in the lateral wall of the orbit. The explanation for the phenomena is that on clenching the jaws, temporalis muscle contracts, which pushes the tumour or soft tissues present in the temporalis fossa inside the orbital cavity through a large bony defect in the lateral wall of the orbit leading to anterior displacement of the globe. The globe moves back on relaxation of temporalis muscle. The causes are orbitotemporal dumbbell dermoid cyst, orbitotemporal neurofibromatosis type II with a defect in the greater wing of sphenoid, and defect in the lateral wall of orbit either due to trauma or lateral wall decompression surgery, etc.[4]

Management is surgical removal of the cyst along with its lining; a lateral orbitotomy is required in cases of orbitotemporal dumbbell dermoid cyst.

Contributors SA wrote the first draft; NP is the primary surgeon and did finalisation of the manuscript; AB helped in data collection and review.

Funding The authors have not declared a specific grant for this research from any funding agency in the public, commercial or not-for-profit sectors.

Competing interests None declared.

Patient consent for publication Consent obtained directly from patient(s)

Provenance and peer review Not commissioned; externally peer reviewed.

Case reports provide a valuable learning resource for the scientific community and can indicate areas of interest for future research. They should not be used in isolation to guide treatment choices or public health policy.

ORCID iD
Sahil Agrawal http://orcid.org/0000-0001-6667-249X

REFERENCES

1 Bender MB. Oscillopsia. *Arch Neurol* 1965;13:204–13.
2 Aschoff JC, Becker W. Voluntary nystagmus in five generations. *J Neurol Neurosurg Psychiatry* 1976;39:300–4.
3 Pushker N, Meel R, Kumar A, *et al*. Orbital and periorbital dermoid/epidermoid cyst: a series of 280 cases and a brief review. *Can J Ophthalmol* 2020;55:167–71.
4 Mettu P, Bhatti MT, El-Dairi MA, *et al*. Orbito-Masticatory syndrome. *J Neuroophthalmol* 2016;36:308–12.