



OPEN ACCESS

Severe thoracic pyomyositis in a patient with systemic lupus erythematosus

Yu-Ning Kuo ,¹ Chih-Sheng Lai,² Yi-Hsing Chen ,¹ Lai Kuo-lung¹

¹Division of Allergy, Immunology and Rheumatology, Department of Internal Medicine, Taichung Veterans General Hospital, Taichung, Taiwan

²Division of Plastic and Reconstructive Surgery, Department of Surgery, Taichung Veterans General Hospital, Taichung, Taiwan

Correspondence to

Dr Lai Kuo-lung;
kllaichiayi@vghtc.gov.tw

Accepted 7 January 2022

SUMMARY

Pyomyositis may mimic deep vein thrombosis and be misdiagnosed in patients with systemic lupus erythematosus (SLE). We report here on patient with SLE with severe thoracic pyomyositis presented with right upper arm swelling and fever. The patient fully recovered after a serial surgical debridement and antibiotic therapy. Pyomyositis, as well as deep vein thrombosis, should be considered during the differential diagnosis of patients with SLE experiencing fever and unilateral limb oedema. CT and identification of causal pathogens are crucial in the diagnosis of pyomyositis. Early effective antibiotic treatment as well as surgical intervention can together bring about a better outcome.

BACKGROUND

Pyomyositis is a pyogenic infection of skeletal muscle with the typical presentation of a localised abscess, which is mostly observed in tropical countries. It commonly affects patients with existing conditions such as diabetes mellitus, haematological malignancy, chronic renal failure, asplenia, HIV infection, autoimmune diseases and those receiving chemotherapy or immunosuppressive drugs.^{1,2} Pyomyositis is mostly caused by *Staphylococcus aureus* up to 90% of the cases. *S. aureus* is in most cases a community-acquired methicillin-resistant strain.^{3,4} Pyomyositis usually affects a single muscle, although the involvement of multiple muscles is not unusual (12%–40% of cases). Bulky muscles, particularly of the thigh, are the most commonly infected site. Other muscles, including the forearm, sternocleidomastoid and intercostal muscles are occasionally involved.

Three clinical stages of pyomyositis are known. The first stage is an invasive stage, involving muscle pain with oedema, low-grade fever and general malaise.¹ The second stage is a suppurative phase, where patients experience severe muscle tenderness and swelling, a high spike in fever and other severe systemic symptoms. During this stage, abscess formation is detectable, and it is when most cases are clinically diagnosed. However, classical signs of an abscess may be absent due to the tense overlying muscles.^{5,6} If treatment is delayed, the infection disseminates and progresses to the final stage, which is also the most severe stage. During this last stage, patients often experience bacteraemia, septic shock, acute renal failure, multiple abscesses and even death.²

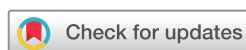The diagnosis of pyomyositis depends on findings obtained from imaging, including ultrasonography, CT and MRI or on pathological findings.

However, it is difficult to diagnose during the early stage due to its non-specific features. Therefore, it is necessary for clinicians to be alert for patients showing risks. Systemic lupus erythematosus (SLE) is a chronic autoimmune disease, which renders patients susceptible to infections due to impaired immunological responses, which are related to the disease itself.⁷ As the disease progresses, when superfluous immune reactivation damages multiple organs in patients with SLE, defence mechanisms fighting against pathogens including bacteria, viruses and fungi become impaired. Initially, white cell function defects play a very important role. Additionally, cytokine abnormalities also influence an SLE patient's susceptibility to infection, including decreased phagocytosis, reduced production of IL-8 and IL-12 by polymorphonuclear leucocytes and complement deficiency as well as defective chemotaxis, membrane recognition and attachment to microorganisms. Third, the presence of antimannose-binding lectin (MBL) autoantibodies in patients with SLE can influence MBL plasma levels and their functional activity. MBL activates the complement system, so the polymorphisms of the MBL-2 gene have been associated with infections. In addition to the disease itself, immunosuppressive agents used to treat SLE, such as steroids and cyclophosphamide are known to predispose patients with SLE to infection. The risk factors for infection are lupus activity state, hypocomplementaemia, use of high-dose steroids and immunosuppressive agents, fever, high-level erythrocyte sedimentation rate and of C reactive protein (CRP), an abnormality in white blood cell ($<4 \times 10^9/L$ or $>10 \times 10^9/L$) and a low level of albumin.

Timely diagnosis of pyomyositis in patients with SLE is challenging not only because of its non-specific features but also due to its mimicry of SLE flare-up and inflammatory myositis. Chest wall involvement is an uncommon condition and has been identified in only one of 25 reported SLE cases with pyomyositis in the available literature.^{7–31} Here, we have reported on a case of SLE with a large extent of chest wall pyomyositis, where the patient fully recovered after surgical intervention and antibiotic treatment.

CASE PRESENTATION

A 64-year-old woman with SLE was admitted to our hospital due to progressive pain in the right lower neck, painful swelling at the right shoulder for 3 days as well as fever without chills for 1 day. She had received acupuncture over the right shoulder 2 days prior to the onset of fever. She denied any



© BMJ Publishing Group Limited 2022. Re-use permitted under CC BY-NC. No commercial re-use. See rights and permissions. Published by BMJ.

To cite: Kuo Y-N, Lai C-S, Chen Y-H, et al. *BMJ Case Rep* 2022;**15**:e246484. doi:10.1136/bcr-2021-246484

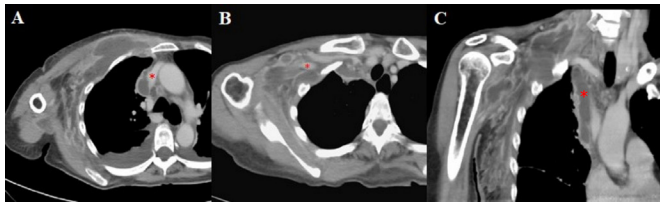


Figure 1 Axial views (A and B) and sagittal view (C) obtained from multidetector CT on hospital day 8. They demonstrate (A) large area of an abscess formation over inner part of the right upper chest wall, particularly the pectoralis muscles, which also compressed to the right lateral part of superior vena cava (star); (B) abscess compressed to distal end of the right subclavian vein (star); (C) abscess extended to right lower neck and mediastinum (star).

history of strenuous exercise or contact with any febrile individuals. She had been diagnosed with SLE 20 years prior at the age of 44 with initial presentations of Raynaud phenomenon, photosensitive rash, positive antinuclear antibody, positive antidouble-stranded DNA antibody, low complement, positive lupus anticoagulant and positive anti-Sjögren's syndrome-related antigen A ntibody. She had been taking azathioprine at 25 mg/day during the last year just prior to this admission.

On admission, her vital signs were temperature 39.9°C, pulse 120 bpm, blood pressure 83/47 mm Hg and respiratory rate 26/min. Her body weight was 56 kg. A physical examination revealed swelling and tenderness without erythematous changes over her right lower neck and shoulder, along with limited movement of the right shoulder and neck. The overlying skin was warm and no neck lymphadenopathy was palpable. There was no active cutaneous or mucosal sign of lupus, no arthritis and no leg oedema. Blood laboratory examinations revealed a white cell count of 2810/μL (normal range (N): 3900–11 000), haemoglobin 8.8 g/dL (N: 13.5–17.5 g/dL), platelet count 613×10⁹/L (N: 150–400×10⁹/L), total bilirubin 4.29 mg/dL (N: 0.2–1.2 mg/dL), albumin 2.6 g/dL (N: 3.3–5.0 g/dL), prothrombin time 14.6 s (N: 9.5–11.7 s), activate partial thromboplastin time 47 s (N: 24.3–32.7 s), blood urea nitrogen 33 mg/dL (N: 5–25 mg/dL), creatinine 1.25 mg/dL (N: 0.5–0.9 mg/dL), sodium 126 mEq/L (N: 137–153 mEq/L), potassium 3.4 mEq/L (N: 3.5–5.3 mEq/L), creatine kinase 587 U/L (N: 10–160 U/L), lactate: 19.8 mg/dL (N: 3–12 mg/dL), CRP 24.3 mg/dL (N: <0.3 mg/dL)

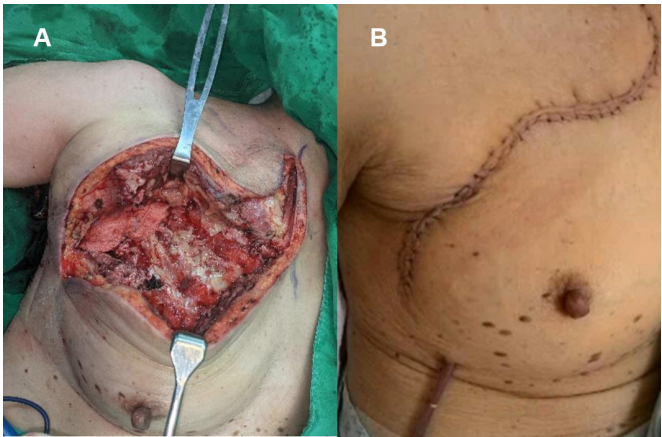


Figure 2 (A) Intraoperative photograph showed a partially necrotic pectoralis major muscle and presence of extensive necrotic tissues between the pectoralis minor and major muscles. (B) The surgical wound was sutured on hospital day 22, with a tubing put in place for continuous drainage.

and procalcitonin 42.53 ng/mL (<0.05 ng/mL). The high levels of CRP and procalcitonin indicated an active infection. Anti-dsDNA, complement C3 and C4, immunoglobulin G, lactate dehydrogenase and thyroid function were all within normal limits. The antiphospholipid profile revealed positive lupus anticoagulant, negative anticardiolipin and negative anti-β2 glycoprotein 1. A urine protein test was negative, while her SLE disease activity was low.

A chest radiograph and sonogram indicated pleural effusion on the right side. Pleural fluid analysis revealed it to be exudative in nature and the subsequent pleural fluid culture yielded no signs of bacterial growth. An urgently needed non-contrast CT scan revealed a small heterogeneous low-density lesion at the right lower neck, diffuse edematous changes in the right anterior and lateral chest wall with fat stranding. A musculoskeletal ultrasonography showed a decrease in echogenicity at the *anterior scalene muscles* with a loss of normal muscle texture. Image findings were consistent with pyomyositis without a liquified abscess. We initiated fluid resuscitation, vasopressor, parenteral empirical antibiotic treatments with cefotaxime at 2 g every 12 hours and vancomycin at 1 g every 12 hours for septic shock.

Table 1 Differential diagnosis of external compression to vein, deep vein thrombosis and lymphangitis in SLE patients with unilateral limb oedema

		External compression to vein (eg, abscess) ^{38–40}	Deep vein thrombosis ^{39 40}	Lymphangitis ^{33–37}
Clinical manifestation	Swelling or oedema	Upper extremity/lower extremity*	Lower extremity†	Lower extremity
	Pain	+	+/- ‡	–
	Fever	+/- §	–	–
Laboratory	D-dimer	–	+	–
	CRP/ESR	+	–	+/-
	APS profile	–	+¶	–
Therapy		Removal of lesion	Anticoagulation	Steroids

*Pyomyositis most often occur in the lower extremity, including the thigh, calf and *gluteal muscles*, although any muscle group can be involved, including the upper extremity muscles.

†Only 4%–10% of all deep vein thromboses were located in the upper extremities. Lower extremity deep vein thrombosis was diagnosed in the range of 20%–30% for patients with APS seen in large cohort studies.

‡Pain was felt in 86% and 19% of patients diagnosed with deep vein thrombosis.

§In clinical stage 1, fever may not be detected, but is often observed in clinical stage 2, which occurs 10–21 days after the initial onset of symptoms.

¶Thirty two per cent (21/66) of patients with positive lupus anticoagulant (LA) and/or positive anticardiolipin antibodies (aCLs) were diagnosed with deep vein thrombosis. Patients with LA+/aCL+ showed a higher prevalence of DVT (53%) as compared with LA+/aCL– (27%) and LA–/aCL+ (22%).

APS, antiphospholipid syndrome; CRP, C reactive protein; ESR, erythrocyte sedimentation rate; SLE, systemic lupus erythematosus.

Table 2 Summarised clinical features and therapies of 25 cases of systemic lupus erythematosus with pyomyositis^{7–31}

Number	Reference/year	Age (years)	Symptoms at presentation	Lesion location	Therapy	Outcome
1	Ushijima et al/1985 ¹⁰	14	Fever Swelling	<i>Quadriceps, Gluteal</i>	Antibiotics ID	Recovery
2	Shames and Fast/1989 ⁸	59	Fever Pain	<i>Gluteal</i>	Antibiotics ID	Recovery
3	Shamiss et al/1990 ¹¹	19	Fever Swelling Pain Oedema	<i>Posterior thighs, calves</i>	Antibiotics ID	Recovery
4	Bonafede et al/1992 ¹³	31	Swelling Pain	<i>Upper arm, thigh</i>	Antibiotics ID	Recovery
5	Dede et al/1993 ²⁸	23	Swelling	<i>Calf</i>	Antibiotics	Recovery
6	Yoshino et al/1994 ⁹	44	Pain	<i>Gluteal</i>	Antibiotics ID	Recovery
7	Belzunegui et al/1995 ¹⁵	27	Fever Pain Palpable mass	<i>Erector spinae</i>	Antibiotics	Recovery
8	Gordon et al/1995 ¹²	48	Fever	<i>Pectoralis major and minor, subclavius, intercostal muscles</i>	Antibiotics	Death
9	Claudepierre et al/1996 ¹⁶	32	Fever Pain Swelling	<i>Quadriceps</i>	Antibiotics ID	Recovery
10	Ushida et al/2001 ¹⁷	21	Pain	<i>Psoas</i>	Antibiotics ID	Death
11	Teh et al/2002 ¹⁸	25	NA	<i>Thigh, calf</i>	NA	Recovery
12	García Hernández et al/2003 ¹⁹	33	Fever Pain	<i>Iliopsoas</i>	Antibiotics ID	Recovery
13	Jidpugdeebodin and Punyagupta/2004 ²⁹	31	NA	<i>Shoulder, axilla, arm, forearm</i>	NA	Recovery
14	Ravindran and Duke/2009 ²⁰	34	Fever Pain Swelling	<i>Pronator teres</i>	Antibiotics	Recovery
15	Collier et al/2010 ²¹	NA	Fever Pain Swelling	<i>Sternocleidomastoid</i>	Antibiotic	Recovery
16	El Baaj et al/2010 ²²	47	Fever Pain	<i>Quadriceps</i>	Antibiotics ID	Recovery
17	Manzoor/2010 ³⁰	23	NA	<i>Rectus femoris</i>	NA	Recovery
18	Sokolove et al/2010 ²³	39	Fever Pain	<i>Quadriceps</i>	Antibiotics	Recovery
19	Souza et al/2011 ²⁴	25	Fever Pain	<i>Iliacus</i>	Antibiotics ID	Recovery
20	Blay et al/2014 ²⁵	16	Fever Pain	<i>Vastus intermedius</i>	Antibiotics	Recovery
21	Chebbi et al/2014 ²⁶	52	Fever Pain	<i>Iliacus, gluteal</i>	Antibiotics	Recovery
22	Simopoulou et al/2014 ²⁷	46	Fever Pain Swelling Ulcer with purulent discharge.	<i>Vastus lateralis</i>	Antibiotics ID	Recovery
23	Meesiri S/2016 ⁷	14	Fever Pain	<i>Gastrocnemius</i>	Antibiotics ID	Recovery
24	Modi MA et al/2013 ³¹	45	Swelling	<i>Quadriceps</i>	Antibiotics ID	Recovery
25	Chen YH et al/2018 ¹⁴	48	Pain Swelling	<i>Flexor hallucis, flexor digitorum.</i>	Antibiotics ID	Recovery

ID, incision and drainage; NA, not available.

On hospital day 5, her vital signs became stable, but she had an intermittent low-grade fever and progressive right upper limb edematous changes without erythema. However, there was no turning pale, pulseless, nor did she experience any numbness. Four sets of blood cultures were taken, all of which yielded no bacterial growth.

Because her progressive right upper limb oedema was suspected to be due to deep vein thrombosis, a multidetector CT (MDCT) was performed on hospital day 8. Those results revealed an extensive abscess at the *pectoralis muscle* with adjacent fat stranding. The abscess extended upward to the right lower neck (*levator scapulae muscle*) and the mediastinum as

Case report

well as down to the right deep lateral thoracic wall (*intercostal muscles*).

Notably, the abscess had compressed the superior vena cava and right subclavian vein, but no evidence of deep vein thrombosis was found ([figure 1](#)). A fasciotomy involving drainage and debridement was performed on the same hospital day as the MDCT, day 8. Extensive necrotic tissues were observed at the *pectoralis minor* and *major muscles* ([figure 2](#)). Negative pressure wound therapy (NPWT) was also applied. A pus culture yielded methicillin-resistant *S. aureus*. Vancomycin was prescribed for 28 days in order to control infection. Serial debridements were performed in combination with continuous NPWT for a span of 2 weeks. The patient's symptoms improved, including right lower neck and right upper limb swelling, and were completely resolved 6 days after the first debridement. The surgical wound was sutured on hospital day 22, with tubing put in place for drainage. Beginning on hospital day 29, antibiotics were switched to oral linezolid at 600 mg every 12 hours. She was discharged on hospital day 33.

Her condition remained stable during subsequent outpatient department (OPD) visits, with the drainage tubing being later removed. A follow-up CT scan performed 3 weeks after discharge showed a complete resolution of both the chest wall abscess and mediastinal abscess. The antibiotic linezolid was finally discontinued. No recurrence of pyomyositis was noted during OPD follow-up visits over the next 3 months.

DISCUSSION

Pyomyositis is an infection primarily involving skeletal muscles. The evolution of myositis could be clinically classified into three stages. In the first stage, non-specific symptoms may be complained of, including focal muscle pain with a wooden consistency, erythema, oedema, low-grade fever and general malaise, while many differentials should be concerning, including thrombotic events, haematoma, muscle strain and osteomyelitis. Our patient experienced progressive warmth, swelling and oedema without erythema over her right lower neck and right upper limb and a mimicking of classic symptoms for deep vein thrombosis. Positive findings for phospholipid antibodies occur in up to 40% of patients with SLE. A significant proportion of patients with SLE is also diagnosed with primary Antiphospholipid syndrome.³² Pyomyositis should also be differentially diagnosed for patients with SLE. Another differential diagnosis given patients with SLE with unilateral limb oedema is lymphangitis.^{33–37} The comparison between external compression to vein (eg, abscess),^{38–40} deep vein thrombosis and lymphangitis is shown in [table 1](#).

Regarding pyomyositis, up to 90% of patients are diagnosed at the second stage, also known as the purulent stage.⁷ However, during this stage, a lack of specific signs and symptoms as well as atypical manifestations may also be observed in patients with SLE.^{5 20 41–43} In SLE child patients, pyomyositis is extremely rare with a prevalence of only 0.35% (1/289).²⁵ However, the prevalence of pyomyositis in adult patients with SLE remains unclear. The diagnosis of pyomyositis is sometimes delayed or even missed due to its unfamiliarity to physicians. Any or all adverse conditions could result in high rates of complications and morbidity. Therefore, obtaining a timely diagnosis of pyomyositis in patients with SLE can be fraught with challenges. For a clinician, pyomyositis should be taken as a differential diagnosis for patients with an immunosuppression and immunocompromised state, like SLE. Imaging assessments, including ultrasonography, CT scans and MRIs, are important in diagnosing pyomyositis. Ultrasonography is a simple, easily available, non-radiative imaging tool

used for diagnosis, although it may miss spotting early myositis, deep muscle abscess or lesions, where its ultrasound beam fails to detect. Alternatively, a contrast-enhanced CT scan and MRI can provide a comprehensive assessment of muscle lesions. If clinical symptoms, including fever, local oedema, swelling and erythematous change, do not improve after empirical antibiotics treatment, repeating an image study, such as a CT scan, is necessary for both detection of disease progression and determining the time when surgical intervention becomes necessary. Regarding our present case, the first CT scan showed no abscess formation in the chest wall. However, a subsequent CT scan performed 7 days later revealed the extensive involvement of pyomyositis with abscess formations. An accurate assessment of the location and extent of muscle abscess is essential for both proper treatment and preoperative planning.

For pectoralis pyomyositis, particularly in stages 2 and 3, further management should include not only immediate and appropriate antibiotics therapy according to the culture of the purulent materials but also early drainage of any purulent discharge as well as surgical debridement. Our patient's clinical condition improved rapidly after surgical intervention when compared with antibiotics treatment alone. A similar case report on a 48-year-old SLE diagnosed woman with chest wall pyomyositis revealed that she had received antibiotics treatment, CT-guided aspiration and drainage of her abscess. She died due to pneumonia and sepsis while experiencing with multiple organ failure.¹² Other clinical features and therapies surrounding 25 cases of patients with SLE with pyomyositis are summarised in [table 2](#). In our present case, the patient successfully recovered from severe chest wall pyomyositis after serial debridement and proper antibiotic treatments. This result indicates the importance of surgical intervention in patients with SLE with chest wall pyomyositis. NPWT is a recent wound treatment modality that provides negative suction pressure for the continuous drainage of an abscess and any wound discharge. The therapy could improve wound closure after a fasciotomy has been performed for treating acute compartment syndrome in patients experiencing necrotising fasciitis. The time interval from fasciotomy to wound closure averages 11.8 days for patients with compartment syndrome using NPWT. There is no need for using a skin graft or flap, with no additional morbidity being reported.^{44 45} Our patient experienced normal, successful wound healing using NPWT after fasciotomy for pyomyositis. The time interval from fasciotomy to wound closure was 14 days.

In conclusion, pyomyositis may mimic deep vein thrombosis and be misdiagnosed in patients with SLE with unilateral limb oedema.

Learning points

- ▶ When a patient with systemic lupus erythematosus (SLE) shows unilateral limb oedema in the presence of fever and warm skin, infections such as an abscess or pyomyositis should be taken into consideration.
- ▶ Pyomyositis may mimic deep vein thrombosis and be misdiagnosed in patients with SLE experiencing unilateral limb oedema.
- ▶ An imaging assessment such as a CT scan, along with the identification of causal pathogens, is crucial for the diagnosis of pyomyositis.
- ▶ While regards to pyomyositis, early effective antibiotic treatment and surgical intervention can provide a satisfactory outcome.

Imaging assessment such as a CT scan and identification of causal pathogens are crucial for diagnosis. A successful outcome depends on early and effective antibiotic treatment as well as surgical intervention.

Contributors C-SL, Y-NC and LK-I provided and cared for study patients. LK-I had the idea for the article and planned the work. LK-I also reviewed the study proposal, edited the article and controlled the decision to publish. C-SL participated in editing of the manuscript. Y-NC performed the literature search, wrote the article and accepted full responsibility for the finished article.

Funding The authors have not declared a specific grant for this research from any funding agency in the public, commercial or not-for-profit sectors.

Competing interests None declared.

Patient consent for publication Consent obtained directly from patient(s).

Provenance and peer review Not commissioned; externally peer reviewed.

Open access This is an open access article distributed in accordance with the Creative Commons Attribution Non Commercial (CC BY-NC 4.0) license, which permits others to distribute, remix, adapt, build upon this work non-commercially, and license their derivative works on different terms, provided the original work is properly cited and the use is non-commercial. See: <http://creativecommons.org/licenses/by-nc/4.0/>.

Case reports provide a valuable learning resource for the scientific community and can indicate areas of interest for future research. They should not be used in isolation to guide treatment choices or public health policy.

ORCID iDs

Yu-Ning Kuo <http://orcid.org/0000-0003-1334-741X>

Yi-Hsing Chen <http://orcid.org/0000-0002-8135-9554>

REFERENCES

- Narayanappa G, Nandeesh BN. Infective myositis. *Brain Pathol* 2021;31:e12950.
- Chauhan S, Jain S, Varma S, et al. Tropical pyomyositis (myositis tropicans): current perspective. *Postgrad Med J* 2004;80:267–70.
- Ruiz ME, Yohannes S, Wladyka CG. Pyomyositis caused by methicillin-resistant *Staphylococcus aureus*. *N Engl J Med* 2005;352:1488–9.
- Shittu A, Deinhardt-Emmer S, Vas Nunes J, et al. Tropical pyomyositis: an update. *Trop Med Int Health* 2020;25:660–5.
- Agarwal V, Chauhan S, Gupta RK. Pyomyositis. *Neuroimaging Clin N Am* 2011;21:975–83.
- Habeych ME, Trinh T, Crum-Cianflone NF. Purulent infectious myositis (formerly tropical pyomyositis). *J Neurol Sci* 2020;413:116767.
- Meesiri S. Pyomyositis in a patient with systemic lupus erythematosus and a review of the literature. *BMJ Case Rep* 2016;2016:bcr2016214809.
- Shames JL, Fast A. Gluteal abscess causing sciatica in a patient with systemic lupus erythematosus. *Arch Phys Med Rehabil* 1989;70:410–1.
- Yoshino YHS, Takeuchi A, Hashimoto T. [Gluteal abscess caused by *Staphylococcus aureus* in a patient with systemic lupus erythematosus]. *Ryumachi* 1994;34.
- Ushijima H, Soda H, Okitsu S, et al. Subcutaneous and / or intramuscular abscesses in two cases of systemic lupus erythematosus. *Jpn J Clin Immunol* 1985;8:47–53.
- Shamiss A, Thaler M, Nussinovitch N, et al. Multiple *Salmonella* enteritidis leg abscesses in a patient with systemic lupus erythematosus. *Postgrad Med J* 1990;66:486–8.
- Gordon BA, Martinez S, Collins AJ. Pyomyositis: characteristics at CT and MR imaging. *Radiology* 1995;197:279–86.
- Bonafede P, Butler J, Kimbrough R, et al. Temperate zone pyomyositis. *West J Med* 1992;156:419–23.
- Chen Y-H, Lu C-C, Chen H-C. *Candida albicans* Pyomyositis in a Patient with Systemic Lupus Erythematosus. *J Rheumatol* 2018;45:286–7.
- Belzunegui J, Plazaola I, Uriarte E, Pego JM, et al. Primary tuberculous muscle abscess in a patient with systemic lupus erythematosus. *Br J Rheumatol* 1995;34:1177–8.
- Claudepierre P, Saint-Marcoux B, Allain J, et al. Clinical images: value of magnetic resonance imaging in extensive pyomyositis. *Arthritis Rheum* 1996;39:1760.
- Ushida H, Koizumi S, Katoh K, Okada Y, et al. [Systemic lupus erythematosus presenting as a brainstem infarction and hemorrhage during treating retroperitoneal abscess: a case report]. *Nihon Hinyokika Gakkai Zasshi* 2001;92:579–82.
- Teh CL, Kong KO, Chong APY, Badsha H, et al. Mycobacterium haemophilum infection in an SLE patient on mycophenolate mofetil. *Lupus* 2002;11:249–52.
- García Hernández FJ, Sánchez Román J, Ocaña Medina C. Absceso del músculo iliopsoas y lupus eritematoso sistémico [Iliopsoas abscess and systemic lupus erythematosus]. *An Med Interna* 2003;20:198–200.
- Ravindran V, Duke O. Non-Tropical pyomyositis in a patient with systemic lupus erythematosus. *Lupus* 2009;18:379–80.
- Collier S, Vig N, Collier J. Two cases of tropical pyomyositis of the sternocleidomastoid muscle occurring in the UK. *Br J Oral Maxillofac Surg* 2010;48:216–7.
- El Baaj FT M, Modden K, Hassikou H. La pyomyosite : une complication infectieuse du lupus érythémateux systémique [Pyomyositis: an infectious complication in systemic lupus erythematosus]. *La Revue de Médecine Interne* 2010;31:e4–6.
- Sokolove J, Copland A, Shirvani S, et al. A 39-year-old woman with lupus, myositis, and a recalcitrant vasculopathy. *Arthritis Care Res* 2010;62:1351–6.
- Souza HCBde, Carvalho BNde, Morais MGvde, et al. Tropical pyomyositis in a patient with systemic lupus erythematosus and HTLV 1/2 infection. *Rev Bras Reumatol* 2011;51:97–103.
- Blay G, Ferriani MPL, Buscatti IM, et al. Pyomyositis in childhood-systemic lupus erythematosus. *Rev Bras Reumatol Engl Ed* 2016;56:79–81.
- Chebbi W, Jerbi S, Kessomtini W, et al. Pyogenic sacroiliitis and pyomyositis in a patient with systemic lupus Erythematosus. *Case Rep Rheumatol* 2014;2014:1–4.
- Simopoulou T, Varna A, Dailiana Z, et al. Tuberculous pyomyositis: a re-emerging entity of many faces. *Clin Rheumatol* 2016;35:1105–10.
- Dede H, Ozdoğan H, Dumankar A, et al. Tropical pyomyositis in a temperate climate. *Br J Rheumatol* 1993;32:435–6.
- Jidpugdeebodin S, Punyagupta S. Salmonella Crepitant pyomyositis in a patient with systemic lupus erythematosus. *J Infect Dis Antimicrob Agents* 2004;21:11–15.
- Manzoor K. A 'tropical disease' in an immunocompromised patient. *Darlington County Durham Med J* 2010;4:7–9.
- Modi MA, Mate AD, Nasta AM, et al. Primary tuberculous pyomyositis of quadriceps femoris in an immunocompetent individual. *Case Rep Infect Dis* 2013;2013:723879.
- Meroni PL, Tsokos GC. Editorial: systemic lupus erythematosus and antiphospholipid syndrome. *Front Immunol* 2019;10:199.
- Ye J, Zhou Z, Teng J, et al. Lymphoedema of lower limbs in systemic lupus erythematosus. *BMJ* 2019;1970.
- Rajasekhar L, Habibi S, Sudhakar P, et al. Lymphatic obstruction as a cause of extremity edema in systemic lupus erythematosus. *Clin Rheumatol* 2013;32 Suppl 1:11–13.
- Pittau E, Tinti A, Martini L, Bogliolo A, et al. Systemic lupus erythematosus with pitting oedema of the distal lower limbs. *Br J Rheumatol* 1998;37:104–5.
- Whitfield A. Disseminated lupus with chronic lymphangitis of the face and osteoarthritis of the hands. *Proc R Soc Med* 1908;1:93–4.
- Günaydin I, Daikeler T, Mohren M, et al. Lower limb pitting edema in systemic lupus erythematosus. *Rheumatol Int* 1999;18:159–60.
- Shepherd JJ. Tropical myositis: is it an entity and what is its cause? *Lancet* 1983;2:1240–2.
- Cervera R, Piette J-C, Font J, et al. Antiphospholipid syndrome: clinical and immunologic manifestations and patterns of disease expression in a cohort of 1,000 patients. *Arthritis Rheum* 2002;46:1019–27.
- Cervera R, Khamashta MA, Shoenfeld Y, et al. Morbidity and mortality in the antiphospholipid syndrome during a 5-year period: a multicentre prospective study of 1000 patients. *Ann Rheum Dis* 2009;68:1428–32.
- Al-Khazraji A, Takher J, Alkhawam H, et al. Primary tuberculous pyomyositis of the calf muscles. *Am J Med Sci* 2017;353:187–8.
- Simmers TA, van den Bosch J, Vasmel WL. Tropical pyomyositis in a temperate climate: a case report. *Neth J Med* 1996;49:86–9.
- Sciascia S, Cuadrado MJ, Karim MY. Management of infection in systemic lupus erythematosus. *Best Pract Res Clin Rheumatol* 2013;27:377–89.
- Eceviz E, Çevik HB. Shoelace technique plus negative-pressure wound therapy closure in fasciotomy wounds. *Adv Skin Wound Care* 2020;33:497–500.
- Lee JY, Jung H, Kwon H, et al. Extended negative pressure wound therapy-assisted dermatotraction for the closure of large open fasciotomy wounds in necrotizing fasciitis patients. *World J Emerg Surg* 2014;9:29.

Copyright 2022 BMJ Publishing Group. All rights reserved. For permission to reuse any of this content visit <https://www.bmj.com/company/products-services/rights-and-licensing/permissions/>
BMJ Case Report Fellows may re-use this article for personal use and teaching without any further permission.

Become a Fellow of BMJ Case Reports today and you can:

- ▶ Submit as many cases as you like
- ▶ Enjoy fast sympathetic peer review and rapid publication of accepted articles
- ▶ Access all the published articles
- ▶ Re-use any of the published material for personal use and teaching without further permission

Customer Service

If you have any further queries about your subscription, please contact our customer services team on +44 (0) 207111 1105 or via email at support@bmj.com.

Visit casereports.bmj.com for more articles like this and to become a Fellow