



OPEN ACCESS

# Metastatic spread of serous ovarian carcinoma to the bilateral breasts: a rare presentation

Arif Musa,<sup>1</sup> Michael Joiner,<sup>1</sup> Stephen Dzul,<sup>1</sup> Steven Raymond Miller<sup>2</sup>

<sup>1</sup>Oncology, Wayne State University, Detroit, Michigan, USA

<sup>2</sup>Oncology, Barbara Ann Karmanos Cancer Institute, Detroit, Michigan, USA

**Correspondence to**

Dr Steven Raymond Miller; srmiller@med.wayne.edu

Accepted 12 November 2022

**SUMMARY**

A woman presented with a mass in her right breast. She had previously been treated with carboplatin, paclitaxel and bevacizumab for serous ovarian carcinoma diagnosed 5 years previously and was currently on maintenance olaparib. A right breast mammogram demonstrated periareolar skin thickening and the physical examination revealed an erythematous, non-blanching cutaneous lesion. A punch biopsy revealed high-grade serous carcinoma of ovarian origin, positive for PAX-8, WT-1 and p53. Positron emission tomogram-CT scan showed diffusely increased fluorodeoxyglucose uptake in the right breast. She was treated with external beam radiation therapy to the right breast and regional lymphatics and received 5200 cGy in 20 fractions to the right breast and supraclavicular region with good response. Two weeks after completing radiation therapy, she presented with a new lesion inferior to her left areola, concerning for metastasis to the contralateral breast. Subsequent biopsy of the left breast identified metastatic serous ovarian carcinoma for which she received an additional 5200 cGy in 20 fractions to the breast.

**BACKGROUND**

Management of cancer localised to the breast versus cancer metastatic to the breast is very different. For patients presenting with a new breast mass, it is, therefore, necessary to distinguish between metastatic spread to the breast and primary breast malignancies. While breast cancer represents the most common malignancy in women, metastatic spread to the breast from extramammary solid tumours is comparatively rare and carries a poorer prognosis due to a high likelihood of widely disseminated disease.<sup>1</sup>

**CASE PRESENTATION**

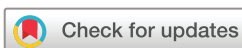A woman with history of stage IIIc serous ovarian carcinoma presented with a new right breast mass. On physical examination, the inferior quadrants of the right breast exhibited peau d'orange appearance. No axillary adenopathy or nipple inversion was noted, and the patient denied any nipple discharge or pain. Her previous medical history includes a history of stage IIIc serous ovarian carcinoma with right pelvic lymphadenopathy diagnosed 5 years ago. She underwent a total abdominal hysterectomy, bilateral salpingo-oophorectomy, infracolic and infragastric omentectomy, argon beam ablation and six cycles of carboplatin and paclitaxel chemotherapy.

Two years after initial therapy, she developed rising CA-125 concerning for recurrence, for which she received additional systemic therapy with nine cycles of carboplatin, doxorubicin and bevacizumab followed by six cycles of maintenance bevacizumab. While on maintenance, bevacizumab patient noticed her right breast became swollen. This prompted a restaging CT of the chest, abdomen and pelvis, which identified interval development of moderate asymmetric increased soft tissue and skin thickening of the right breast. Subsequent skin punch biopsy of the right breast identified metastatic serous carcinoma consistent with ovarian primary. At that time, she was offered mastectomy, which she declined. Due to her progression following carboplatin therapy, she was deemed as having platinum-resistant disease and was transitioned to systemic therapy with six cycles of weekly paclitaxel and bevacizumab followed by maintenance olaparib.<sup>2</sup>

The patient has a previous medical history significant for type 2 diabetes, major depressive disorder, hypertension and hypercholesterolemia. Her surgical history includes hernia repair and hip surgery. She is a former smoker with one-half pack per day for 6 years (three pack years in total) before quitting 36 years ago. She occasionally drinks alcohol. She denies any family history of malignancy.

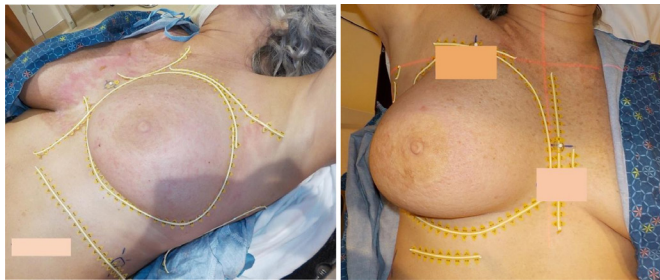
**INVESTIGATIONS**

A CT scan of the chest, abdomen and pelvis with oral and intravenous contrast revealed an interval increase in the soft tissue of the right breast and skin thickening. On examination, the breast was noted to appear swollen bilaterally with hyperpigmented skin changes present inferior to the right nipple (figure 1). There was no lymphadenopathy or other signs of metastatic spread in the abdomen or pelvis. A core needle biopsy of the right breast lesion revealed metastatic carcinoma, compatible with serous type, high-grade ovarian carcinoma. Immunohistochemical analysis found tumour cells to be positive for PAX-8, WT-1 and p53. Tumour cells were negative for GATA-3. Laboratory tests indicated an elevated cancer antigen 125 (CA-125) of 101 (normal range: 0–35 U/mL). Immunohistochemical results positive for PAX-8 and WT-1 and elevated CA-125 confirmed the diagnosis of metastatic spread of serous ovarian carcinoma. A positron emission tomogram (PET)-CT scan was ordered for restaging. There was diffuse fluorodeoxyglucose (FDG) uptake in the right breast, consistent with secondary malignant neoplasm of the right breast consistent with biopsy-proven



© BMJ Publishing Group Limited 2022. Re-use permitted under CC BY-NC. No commercial re-use. See rights and permissions. Published by BMJ.

**To cite:** Musa A, Joiner M, Dzul S, et al. *BMJ Case Rep* 2022;**15**:e251721. doi:10.1136/bcr-2022-251721



**Figure 1** Left and right breasts at time of radiation planning.

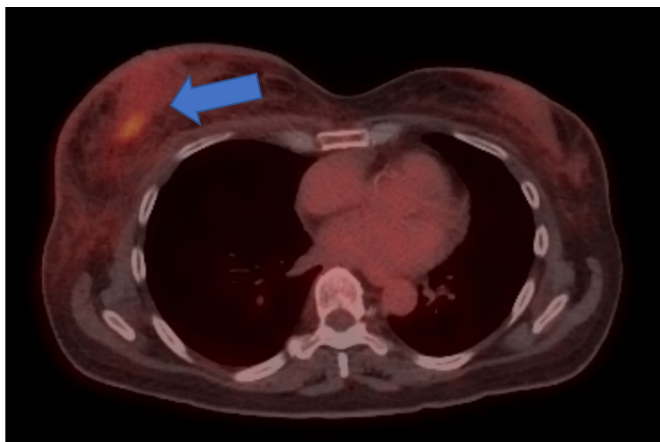
metastatic ovarian carcinoma. There were no other regions with FDG avid diseases that were concerning for metastatic spread.

### DIFFERENTIAL DIAGNOSIS

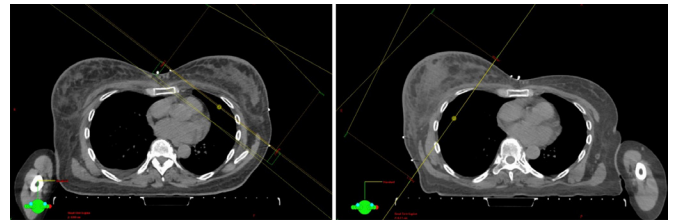
Many different aetiologies make up the differential diagnosis for this unusual case. The most common causes for breast redness include infection, malignancy, trauma, dermatological conditions and venous hypertension with infections and mastitis being the most common.<sup>1</sup> Our initial diagnosis for our patient was a primary breast cancer or a metastatic cancer which had spread to the breast. A PET scan revealed activity in the right breast and a skin biopsy consisted with metastatic ovarian cancer. Other diagnoses including infection were dismissed after the breast biopsy revealed cancer and the right breast did not seem infected. Several small skin nodules were noted, which were more consistent with a recurrent cancer. If the biopsies had been negative, though, cellulitis would have been number one on the differential diagnosis. Finally, the patient denied any recent trauma to the breast, which could account for the skin redness or any history of eczema or a skin allergic reaction. An allergic reaction could have been treated with steroid creams or oral medication. Finally, the patient denied any history of venous hypertension. A recent CT scan revealed no evidence of a deep vein thrombosis (DVT) or superior vena cava syndrome and the patient did not have a right arm shunt for dialysis. Again, secondary to the positive skin biopsy, this diagnosis of venous hypertension was placed lower on the differential.

### TREATMENT

The patient received 5200 cGy of external beam radiation in 20 fractions to the right breast over the course of 1 month without



**Figure 2** Axial PET scan image demonstrating increased FDG uptake in the right breast. FDG, fluorodeoxyglucose; PET, positron emission tomogram.



**Figure 3** Representative CT simulation axial images displaying right and left breast radiation fields.

concurrent chemotherapy. She tolerated the procedure well and there was no evidence of recurrence of disease in the right breast (figure 2).

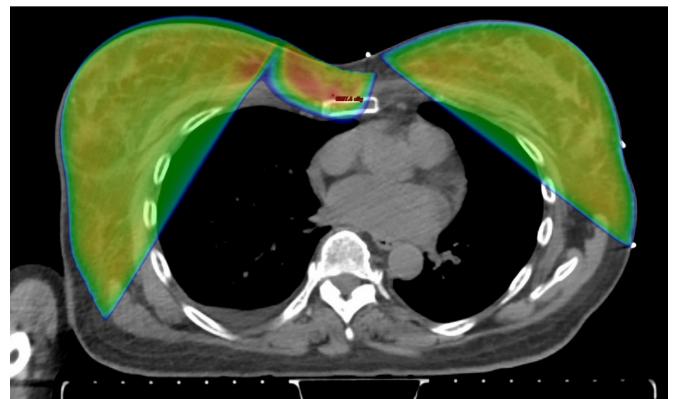
### OUTCOME AND FOLLOW-UP

One month after treatment, there was no recurrence of disease noted in the right breast. After radiation therapy, postradiation dermatitis and pain were well controlled with topical silvadene and oral analgesics, respectively. However, she also presented with peau d'orange skin changes in the contralateral (left) breast concerning for metastatic spread. A subsequent biopsy confirmed metastasis to the left breast. She underwent primary radiation therapy to the left breast, also 5200 cGy in 20 fractions (figures 3 and 4).

### DISCUSSION

High-grade serous carcinoma of the ovary represents the most common as well as most deadly form of ovarian cancer.<sup>2</sup> Serous ovarian carcinomas originate from one of three anatomical locations: the surface epithelium of the ovary, the fallopian tube epithelium or the mesothelium of the peritoneum.<sup>3</sup> Most patients with high-grade serous ovarian cancer develop metastatic disease.<sup>4</sup> Metastasis is most common to the peritoneum and omentum, which occurs via local extension;<sup>3</sup> however, less commonly, tumour cells can reach distant sites via lymphatic or haematogenous spread.<sup>5</sup>

Metastatic spread to the breast is exceedingly rare. In fact, extramammary metastases to the breast represent <1% of breast tumours.<sup>6</sup> Bilateral metastasis is even rarer.<sup>7</sup> Differentiating between primary breast cancers and metastases from distant sites such as the ovary is necessary due to differences in prognosis and management. The mechanism for metastatic spread to the breast appears to be haematogenous or lymphatic seeding.<sup>6</sup> Metastatic spread carries a far poorer prognosis with one study finding that



**Figure 4** Radiation treatment plan showing predicted dose distribution from bilateral breast irradiation.

**Table 1** Cases of bilateral breast metastasis of serous ovarian carcinoma in the literature

Author (year)	Age	Stage	Presentation	Lymphadenopathy	Histology	Treatment	Serum	Immunohistochemistry	Outcome (interval*)
Krishnan (1980) <sup>1</sup>	60	N/A	Edema, Erythema, Induration, Tenderness	None	Papillary serous, psammoma bodies	Chemotherapy, radiation	N/A	N/A	Death (6 months)
Hughes (1983) <sup>2</sup>	48	N/A	Mass	Axillary	Papillary adenocarcinoma	Mastectomy	N/A	N/A	Death (5 months)
Wadhwa (1999) <sup>3</sup>	45	IV	Induration, Peau d'orange	Axillary, supraclavicular	Papillary serous, focal calcifications, psammoma bodies	Chemotherapy, mastectomy, radiation	CA-125	N/A	Progression (25 months)
Ozgueroğlu (1999) <sup>4</sup>	55	IIIC	Edema, Erythema, Induration	Supraclavicular	Papillary adenocarcinoma	N/A	CA-125	N/A	Death (3 months)
Özsaran (2000) <sup>5</sup>	41	N/A	Edema, Mass, Nipple retraction, Peau d'orange	Axillary	Papillary serous, microcalcifications	Chemotherapy	CA-125	p53 (+)	Death (N/A)
Oksüzöglü (2001) <sup>6</sup>	N/A	IIIC	N/A	Axillary	Papillary cyst-adenocarcinoma	Chemotherapy	CA-125	N/A	Partial response (18 months)
Kayıkçıoğlu (2001) <sup>7</sup>	33	IIIC	Erythema, Induration, Tenderness	Axillary	Papillary serous	Chemotherapy, hormone therapy	CA-125	OC125 (+)GCDFF (-)ER (-)	Death (18 months)
Gökaslan (2005) <sup>8</sup>	68	N/A	Mass	Axillary	Papillary serous cystadenocarcinoma	Chemotherapy	N/A	CA-125 (+), CA15-3 (+)	N/A (N/A)
Fulciniti (2008) <sup>9</sup>	49	III	Mass	None	Serous carcinoma, microcalcifications, psammoma bodies	Chemotherapy	N/A	CA-125 (+)WT-1 (+)	N/A (N/A)
Khalifeh (2009) <sup>10</sup>	56	IV	Erythema	Axillary	Serous carcinoma, calcifications, psammoma bodies	Chemotherapy, hormone therapy, mastectomy, radiation	CA-125, CA27.29	ER (+),PR (-),WT-1 (+),GCDFF (-)	Good response (16 months)

\*Interval: since breast involvement.

CA-125, cancer antigen 125; CA 15-3, cancer antigen 15-3; ER, estrogen receptor; GCDFF, gross cystic disease fluid protein; OC-125, monoclonal antibody for CA-125 antigen; WT-1, Wilms' tumour-1 antigen.

## Case report

in patients with primary serous ovarian carcinoma, metastatic spread to the breast led to 70% mortality within 3–10 months.<sup>8</sup> Breast cancers are treated with local or systemic treatments such as surgery, radiation, hormone therapy, chemotherapy and targeted therapy.

Differentiating metastatic disease from primary breast malignancy can be challenging. Clinical signs typically include single or multiple nodules, erythema, induration and the peau d'orange sign.<sup>9</sup> However, these findings are often indistinguishable from those seen in primary tumours of the breast. Histologically, metastatic serous ovarian carcinoma and ductal carcinoma of the breast have been known to share similarities such as pleomorphism, prominent nucleoli and nuclear atypia.<sup>8</sup>

Therefore, immunohistochemistry is often used to distinguish metastatic disease from primary tumours. Tumour markers that are typically increased in ovarian carcinomas include PAX-8, WT-1 and CA-125.<sup>8</sup> By comparison, GATA-3 and gross cystic disease fluid protein (GCDFP) expression are not expected to be elevated in ovarian metastases.<sup>8</sup> Serum CA-125 is also often elevated in ovarian cancer. CA-125 levels can also be trended to monitor for disease recurrence in patients who have undergone treatment.<sup>10</sup> Of note, both metastatic disease and primary tumours may have increased expression of estrogen receptor (ER) and progesterone receptor (PR).<sup>8</sup> If further confirmation of the tumour origin is needed, molecular testing can be used to determine the pattern of mutations at the site of the breast tumour as well as the suspected primary.<sup>11</sup>

### Literature review

A review of the published literature found only 10 cases of confirmed bilateral metastases from ovarian carcinoma (table 1). The average age of presentation was 50.5 years (range: 33–68 years) during which patients typically had a previous diagnosis of stage III or IV ovarian carcinoma. Patients presented with a wide variety of symptoms, many of which were also typical presenting symptoms of primary breast malignancies. Physical examination findings were often incongruent breasts. The most common findings were erythema (44%), induration (44%) and the presence of a mass (44%). Oedema (33%), tenderness (22%), Peau d'orange sign (22%) and nipple retraction (11%) were less common.

Axillary lymphadenopathy (70%) was present in the majority of cases. By comparison, supraclavicular lymphadenopathy was seen in 20% of cases. Prominent histological findings included calcifications and psammoma bodies. The vast majority of cases (80%) included an elevated serum CA-125 or diffuse staining of CA-125. Other immunohistochemical findings that were positive included WT-1, p53, OC125 (antibody that binds CA-125) and CA 15–3. GCDFP was negative for 2 cases and PR was negative for one case. Notably, 1 case was ER-positive and another case was ER-negative. The most commonly employed treatment was chemotherapy (78%) followed by radiation (33%) and mastectomy (33%). The follow-up period after bilateral breast involvement was confirmed and was, on average, 13 months (range: 3–25 months). The majority of patients died within the follow-up period, suggesting a poor prognosis.

### Treatment

The patient in this case was treated systemically with a chemotherapy regimen that included doxorubicin, carboplatin and bevacizumab before being started on maintenance therapy with olaparib. She refused mastectomy and, thus, local therapy with radiation was recommended. At our institution, 52 Gy of radiation in 20 fractions is the standard treatment.

Given the rarity of metastatic disease to the breast from primary ovarian cancer, there is no established treatment. Typically, metastatic ovarian cancer is treated with systemic chemotherapy with first-line regimen often including carboplatin and paclitaxel;<sup>12</sup> however, newer targeted systemic agents can be considered.<sup>13</sup> Local treatment in the form of mastectomy, lumpectomy, lymphadenectomy and/or radiation therapy may be considered based on extent of disease and patient symptoms. A review of 127 cases of serous and non-serous ovarian carcinoma with metastatic spread to unilateral or bilateral breasts found that chemotherapy was administered in 49 cases (38.6%), mastectomy or quadrantectomy performed in 5 (3.9%), lumpectomy performed in 16 (12.6%), hormone therapy administered in 2 = (1.6%) and radiation therapy in 2 (1.6%).<sup>14</sup> Symptomatic metastases to the breast may be effectively treated with radiation therapy for

### Patient's perspective

My treatment for metastatic breast cancer was a life changing event. I had hoped that I had been done with treatment since many of my scans were negative and I was responding well to chemotherapy.

When I developed these lesions on my breast, I just thought that it was an allergic reaction. My right breast continued to swell and did not respond well to chemotherapy. My oncologist was not quite sure what was going on, but the skin biopsy of the breast answered the question. The radiation treatment, I must say was very painful. At first, it did not bother me but after a few weeks of treatment my right breast became red and tender. The pain was more annoying than anything making it difficult to wear tight clothing. I must walk around most of the time without a bra. My nurse gave me Aquaphor and Silvadene cream to use which helped but did soothe the pain an appreciable degree. I was given a prescription for Norco, which helped with the pain but made my thinking somewhat cloudy. The treatment I have to say was somewhat miserable. My right breast felt like it was on fire and there was not a lot I could do about it. I had very few family members that I could talk to about my suffering. Finally, the radiation treatments were completed, and I was hoping that the pain would go very soon. To celebrate the completion of my treatment, I even took a trip to Florida. I had to stay covered up in Florida since the skin of my right chest was all red. I had a good time, but unfortunately returned to the bad news after a biopsy of recurrent disease in the left breast. Since I know what to expect from the right breast, the treatment was slightly easier but was still painful. The skin did heal up after the second radiation treatment and now I am just waiting to see what additional chemotherapeutics options might be available

### Learning points

- ▶ Metastatic spread to the breast is exceedingly rare but should be considered as a differential diagnosis in patients presenting with a new breast mass, particularly those with history of malignancy such as high-grade ovarian carcinomas.
- ▶ Metastatic spread to the breast is indicative of disseminated disease and carries a poor prognosis.
- ▶ Patients diagnosed with high-grade serous ovarian carcinoma should be followed closely for breast disease.
- ▶ Patients who develop metastatic spread to the breast should be monitored closely for spread to the contralateral breast.



palliation,<sup>15</sup> as in this patient. External beam radiation for breast tumours may be given as a single fraction or in multiple fractions. Single-fraction radiation has the benefit of interfering less with systemic therapies while fractionated therapy produces a stronger response.<sup>16</sup> According to the randomized trial of accelerated partial breast irradiation (RAPID) trial, whole breast irradiation with 42.5 Gy in 16 fractions or 50 Gy in 25 fractions led to a recurrence of 2.8% after 8 years.<sup>17</sup> Other fractionated regimens include 45 Gy in 15 fractions, 39 Gy in 13 fractions and 50 Gy in 25 fractions.<sup>16</sup>

## CONCLUSION

Metastatic spread to the bilateral breasts from primary serous ovarian carcinoma constitutes an exceedingly rare occurrence. Patients who present with signs and symptoms of breast cancer should have metastatic disease considered as a differential diagnosis. Metastatic disease carries a poor prognosis and variable treatment course. Biopsy-proven metastatic serous ovarian carcinoma should be treated systemically with chemotherapy. Additional treatment with targeted systemic agents and/or radiation therapy should be considered based on immunohistochemistry, extension of disease and other patient-specific factors. External beam radiation therapy should be considered for symptomatic relief and palliation for locally advanced and early course breast metastasis.

**Contributors** AM, MJ, SD and SRM all contributed to the writing and review of this case report.

**Funding** The authors have not declared a specific grant for this research from any funding agency in the public, commercial or not-for-profit sectors.

**Competing interests** None declared.

**Patient consent for publication** Consent obtained directly from patient(s)

**Provenance and peer review** Not commissioned; externally peer reviewed.

**Open access** This is an open access article distributed in accordance with the Creative Commons Attribution Non Commercial (CC BY-NC 4.0) license, which permits others to distribute, remix, adapt, build upon this work non-commercially, and license their derivative works on different terms, provided the original work is properly cited and the use is non-commercial. See: <http://creativecommons.org/licenses/by-nc/4.0/>.

Case reports provide a valuable learning resource for the scientific community and can indicate areas of interest for future research. They should not be used in isolation to guide treatment choices or public health policy.

## REFERENCES

- 1 Akçay MN. Metastatic disease in the breast. *Breast* 2002;11:526–8.
- 2 National comprehensive cancer network Genetic/familial high-risk assessment: breast and ovarian, version 1. practice guidelines, 2011. Available: <https://www.nccn.org> [Accessed 12 May 2011].
- 3 Kim J, Park EY, Kim O, *et al.* Cell origins of high-grade serous ovarian cancer. *Cancers* 2018;10. doi:10.3390/cancers10110433. [Epub ahead of print: 12 11 2018].
- 4 Lengyel E. Ovarian cancer development and metastasis. *Am J Pathol* 2010;177:1053–64.
- 5 Shinagare AB, O'Neill AC, Cheng S, *et al.* Advanced high-grade serous ovarian cancer: frequency and timing of thoracic metastases and the implications for chest imaging follow-up. *Radiology* 2015;277:733–40.
- 6 Thomakos N, Diakosawas M, Machairiotis N, *et al.* Rare distant metastatic disease of ovarian and peritoneal carcinomatosis: a review of the literature. *Cancers* 2019;11. doi:10.3390/cancers11081044. [Epub ahead of print: 24 07 2019].
- 7 Georgiannos SN, Chin J, Goode AW. Secondary neoplasms of the breast: a survey of the 20th century. *Cancer* 2001;92:2259–66.
- 8 Dursun P, Yanik FB, Kusu E, *et al.* Bilateral breast metastasis of ovarian carcinoma. *Eur J Gynaecol Oncol* 2009;30:9–12.
- 9 Panse G, Bossuyt V, Ko CJ. Metastatic serous carcinoma presenting as inflammatory carcinoma over the breast-Report of two cases and literature review. *J Cutan Pathol* 2018;45:234–9.
- 10 Moreno-Astudillo L, Villaseñor-Navarro Y, Sánchez-Goytia V, *et al.* A case series of breast metastases from different extramammary malignancies and their literature review. *Case Rep Radiol* 2019;2019:1–7.
- 11 Bottoni P, Scatena R. The role of Ca 125 as tumor marker: biochemical and clinical aspects. *Adv Exp Med Biol* 2015;867:229–44.
- 12 Khalifeh I, Deavers MT, Cristofanilli M, *et al.* Primary peritoneal serous carcinoma presenting as inflammatory breast cancer. *Breast J* 2009;15:176–81.
- 13 Caruso G, Musacchio L, Santangelo G, *et al.* Ovarian cancer metastasis to the breast: a case report and review of the literature. *Case Rep Oncol* 2020;13:1317–24.
- 14 Jutzy JMS, Lemons JM, Luke JJ, *et al.* The evolution of radiation therapy in metastatic breast cancer: from local therapy to systemic agent. *Int J Breast Cancer* 2018;2018:1–7.
- 15 Jacobson G, Kaidar-Person O, Haisraely O, *et al.* Palliative radiation therapy for symptomatic advance breast cancer. *Sci Rep* 2021;11:5282.
- 16 Whelan TJ, Julian JA, Berrang TS, *et al.* External beam accelerated partial breast irradiation versus whole breast irradiation after breast conserving surgery in women with ductal carcinoma in situ and node-negative breast cancer (rapid): a randomised controlled trial. *Lancet* 2019;394:2165–72.
- 17 Froman J, Landercasper J, Ellis R, *et al.* Red breast as a presenting complaint at a breast center: an institutional review. *Surgery* 2011;149:813–9.

Copyright 2022 BMJ Publishing Group. All rights reserved. For permission to reuse any of this content visit <https://www.bmj.com/company/products-services/rights-and-licensing/permissions/>  
BMJ Case Report Fellows may re-use this article for personal use and teaching without any further permission.

Become a Fellow of BMJ Case Reports today and you can:

- ▶ Submit as many cases as you like
- ▶ Enjoy fast sympathetic peer review and rapid publication of accepted articles
- ▶ Access all the published articles
- ▶ Re-use any of the published material for personal use and teaching without further permission

### Customer Service

If you have any further queries about your subscription, please contact our customer services team on +44 (0) 207111 1105 or via email at [support@bmj.com](mailto:support@bmj.com).

Visit [casereports.bmj.com](http://casereports.bmj.com) for more articles like this and to become a Fellow