OPEN ACCESS

Proximal tibiofibular joint (PTFJ) dislocation due to Ehlers-Danlos syndrome: posterolateral open-wedge high tibial osteotomy combined with medial closed-wedge distal femoral osteotomy can correct the severe valgus deformity with a markedly increased tibial posterior slope

Masaki Amemiya ,[1,2] Ryuichi Nakamura ,[1] Mitsuo Yoshimura,[3] Tomoharu Takagi[4]

[1]Joint Preservation and Sports Orthopaedic Center, Harue Hospital, Sakai, Japan
[2]Joint Surgery and Sports Medicine, Graduate School of Medical and Dental Sciences, Tokyo Medical and Dental University, Tokyo, Japan
[3]Hand Surgery Center, Harue Hospital, Sakai, Japan
[4]Orthopaedic Surgery, Fukui-ken Saiseikai Hospital, Fukui, Japan

Correspondence to
Dr Ryuichi Nakamura; ryu-nakamura@msj.biglobe.ne.jp

Accepted 18 November 2022

To cite: Amemiya M, Nakamura R, Yoshimura M, *et al*. *BMJ Case Rep* 2022;**15**:e250308. doi:10.1136/bcr-2022-250308

SUMMARY

Ehlers-Danlos syndrome (EDS) causes joint hypermobility and joint dislocation. Since there are no reports of proximal tibiofibular joint (PTFJ) dislocation caused by EDS, little is known about the long-term course of this disease. A woman in her 40s presented with a posterolaterally depressed tibial condyle and severe valgus deformity caused by a long-standing PTFJ dislocation due to EDS. Considering the pathology, posterolateral open-wedge high tibial osteotomy (PLOWHTO) and medial closed-wedge distal femoral osteotomy were performed according to the deformity analysis. A favourable short-term clinical outcome was obtained and the PTFJ dislocation was reduced over time. Although PLOWHTO has several pitfalls, it is a logical and useful surgical technique that can help treat posterolateral dysplasia of the tibial plateau concomitant with severe valgus deformity, regardless of joint laxity, if performed with attention to pitfalls.

BACKGROUND

Ehlers-Danlos syndrome (EDS) is a hereditary disorder that leads to systemic connective tissue fragility, such as in the skin, joints and blood vessel walls, with joint hypermobility, leading to systemic joint dislocations and subsequent osteoarthritis. Although various types of joint dislocations have been reported,[1–3] there are no previous reports on proximal tibiofibular joint (PTFJ) dislocations caused by EDS. Here, we report a case of EDS with PTFJ dislocation that led to a severe valgus-aligned knee with posterolateral dysplasia of the lateral tibial condyle.

CASE PRESENTATION

A woman in her early 40's, who suffered a severe valgus deformity with PTFJ dislocation in her left knee, was referred to our hospital. Her left knee pain gradually worsened with time after undergoing a lateral meniscectomy 10 years ago. She had no symptoms of swelling, clicking, catching or limitation in her range of motion, but her quality of life was severely limited by the impairment of weight-bearing caused by the excessive valgus of the knee with hyperextension (table 1).

All conservative treatments, such as insole therapy and steroid injection, offered at several hospitals had failed.

Hyperextension of both knees, elbows, wrists and fingers was observed (figure 1), and the Beighton criteria showed a score of 8 out of 9.[4] In addition to PTFJ dislocation, she had severe scoliosis, a history of patellar dislocation and a family history of joint hypermobility, which may suggest a genetic predisposition. Based on these findings, we clinically diagnosed her condition as EDS, despite the lack of biochemical and/or molecular analysis due to her refusal.

INVESTIGATIONS

Plain radiographs and CT revealed that the fibular head was dislocated, and the tibial condyle unsupported by the fibula was depressed posterolaterally (figure 2A,B,E,G,H). The lateral view of CT showed a steep lateral tibial posterior slope at an angle of 17° (Figure 5E). MRI demonstrated that the middle part of the lateral meniscus was almost completely resected (figure 2C,D). A radiograph of the anteroposterior view of the whole leg in the standing position showed that the mechanical lateral distal femoral angle (mLDFA, reference values: 85°–90°)[5] and mechanical medial proximal tibial angle (mMPTA, reference values: 85°–90°)[5] were 85° and 100°, respectively. The weight-bearing line (WBL) ratio[6] was 130%, demonstrating severe valgus alignment. The major cause was a deformity of the proximal tibia with a mild deformity of the distal femur (figure 2F).

Based on the deformity analysis, we performed preoperative planning. The target mechanical axis was planned as the postoperative WBL ratio passed through 50% from the medial edge of the tibial plateau. Accordingly, the correction angle was planned to be 6° by medial closed-wedge distal femoral osteotomy (MCWDFO) and 8° by posterolateral open-wedge high tibial osteotomy (PLOWHTO). The posterior opening distance was calculated to be 8 mm based on a

Table 1 Patient-reported outcome measurement at 2 years after surgery

	Preoperative	2 years after surgery
KOOS symptoms	85.7	92.9
KOOS pain	75	94.4*
KOOS ADLs	48.5	97.1*
KOOS sports	20	75*
KOOS QOL	0	87.5*

Asterisks indicate minimal clinically significant differences.
KOOS ADLs, KOOS Activity of Daily Living; KOOS, Knee Injury Osteoarthritis and Outcome Score; KOOS QOL, KOOS Quality of Life.

3-dimensional printed model (ZimmerBiomet G.K., Tokyo, Japan) (figure 2I,J). Although the standard value of the tibial posterior slope is 6° when the posterior cortex is used as a reference line,[7] the target slope was planned to be around 10° to prevent further hyperextension of the knee.

DIFFERENTIAL DIAGNOSIS

Treatment

The patient was placed in a supine position under general anaesthesia. No tourniquet was used throughout the whole arthroscopy and femoral, fibular and tibial osteotomy procedures. After arthroscopic partial meniscectomy for a flap tear of the posterior segment of the lateral meniscus, a biplanar MCWDFO was performed using a subvastus approach according to the procedure described by Nakamura *et al*.[8] The osteotomized site was fixed with an MCWDFO-specific locking plate (TriS Medial DFO Plate, Olympus Terumo Biomaterials, Tokyo, Japan). The peroneal nerve was then released through a posterolateral longitudinal skin incision, separate from the incision for the tibial osteotomy, to prevent peroneal nerve palsy by posterolateral opening. The posterolateral incision provided working space for subsequent fibular osteotomy with safe and sufficient retraction of the released nerve. Segmental fibular osteotomy was performed through the same incision immediately below the fibular head (figure 3A,B).

Subsequently, a 10 cm curved longitudinal skin incision was made on the anterolateral aspect of the knee through Gerdy's tubercle. The tibialis anterior and posterior soft tissues were subperiosteally released. Two Kirschner wires (2.0 mm diameter) were inserted 40 mm distal to the lateral proximal tibial plateau to 15 mm distal to the medial proximal tibial joint surface. A hinge point was set at approximately 5 mm before the medial

Figure 1 Physical examination demonstrates polyarticular joint hypermobility. The knee and elbow joints show hyperextension by more than 10°. The Beighton diagnostic criteria for EDS show a score of 8 out of 9.[4] EDS, Ehlers-Danlos syndrome.

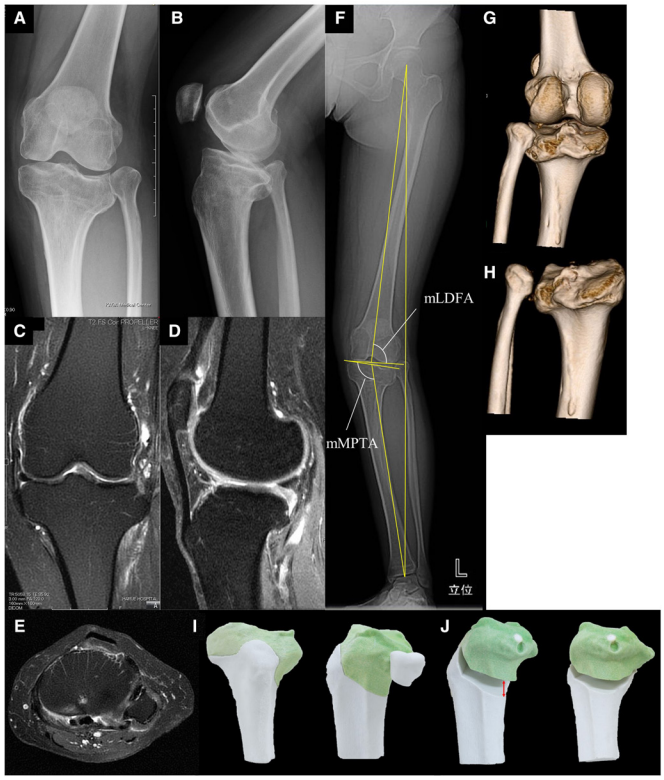

Figure 2 Preoperative plain radiographs, MRI, three-dimensional (3D) CT and a 3D-printed model from the 3D-CT. (A) A plain radiograph with an anterior–posterior view shows that the proximal tibiofibular joint (PTFJ) was dislocated with decompression of the lateral tibial plateau. (B) Lateral view of a radiograph. (C) The coronal plane of MRI demonstrates that the middle part of the lateral meniscus has been almost resected. (D) The sagittal MRI of the lateral compartment of the knee. (E) Axial view of the MRI. There was no interposed connective tissue between the fibular head and the lateral tibial condyle. (F) A radiograph of the whole leg in the standing position shows severe valgus alignment due to proximal tibial deformity. Weight-bearing line (WBL) ratio=130%, mechanical lateral distal femoral angle (mLDFA)=85° and mechanical medial proximal tibial angle (mMTPA)=100°. (G) A posterior view of CT demonstrates the dislocation of PTFJ and the steep tibial posterior slope. (H) Posteromedial view. (I) The osteotomy line of posterolateral open-wedge high tibial osteotomy in a 3D printed model. (J) The simulation of the posterolateral opening of the osteotomized site (double-headed arrow).

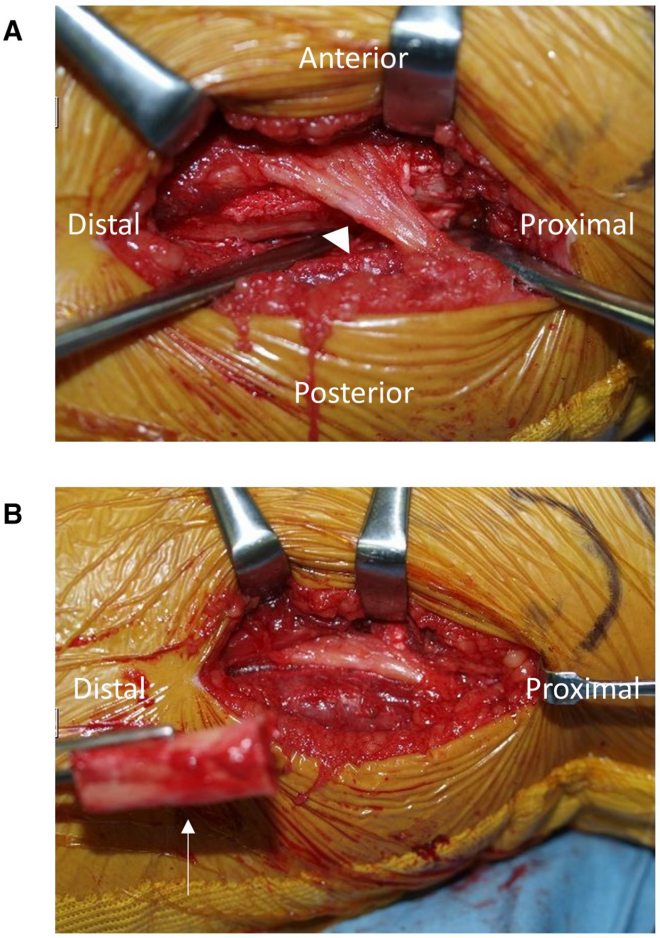

Figure 3 The peroneal nerve neurolysis and fibula osteotomy of the left knee. (A) The peroneal nerve (white arrowhead) was released in the proximal and distal directions. (B) Segmental osteotomy (white arrow) of the fibula was performed.

tibial cortex. Since PLOWHTO is likely to be unstable following a hinge fracture, the medial plate (TomoFix small version, DePuy Synthes, Bettlach, Switzerland) was temporarily fixed with two Kirschner wires before tibial osteotomy (figure 4A,B). For the medial plating, the anteromedial arthroscopic portal was extended distally by 3 cm and the plate was subcutaneously installed.

A biplanar osteotomy was performed similarly to that of medial open-wedge high tibial osteotomy (OWHTO),[9–11] and the osteotomized site was opened to the planned distance using a spreader. The removed fibula was crushed and used as a gap filler, and two bone-substitute wedges made of beta-tricalcium phosphate (OSferion60 Marvelous; Olympus Terumo Biomaterials, Tokyo, Japan) were inserted between the lateral cortices (figure 4C). Lateral fixation was then performed using an locking compression plate (LCP) proximal lateral tibial plate (DePuy Synthes, Bettlach, Switzerland), and medial plate fixation was completed using locking screws (figure 5A,B). Range of motion exercises were initiated on the first day after surgery, and full weight-bearing was allowed at 6 weeks.

OUTCOME AND FOLLOW-UP

Postoperative radiography of the entire leg revealed an anatomically corrected WBL (51%). mLDFA and mMPTA

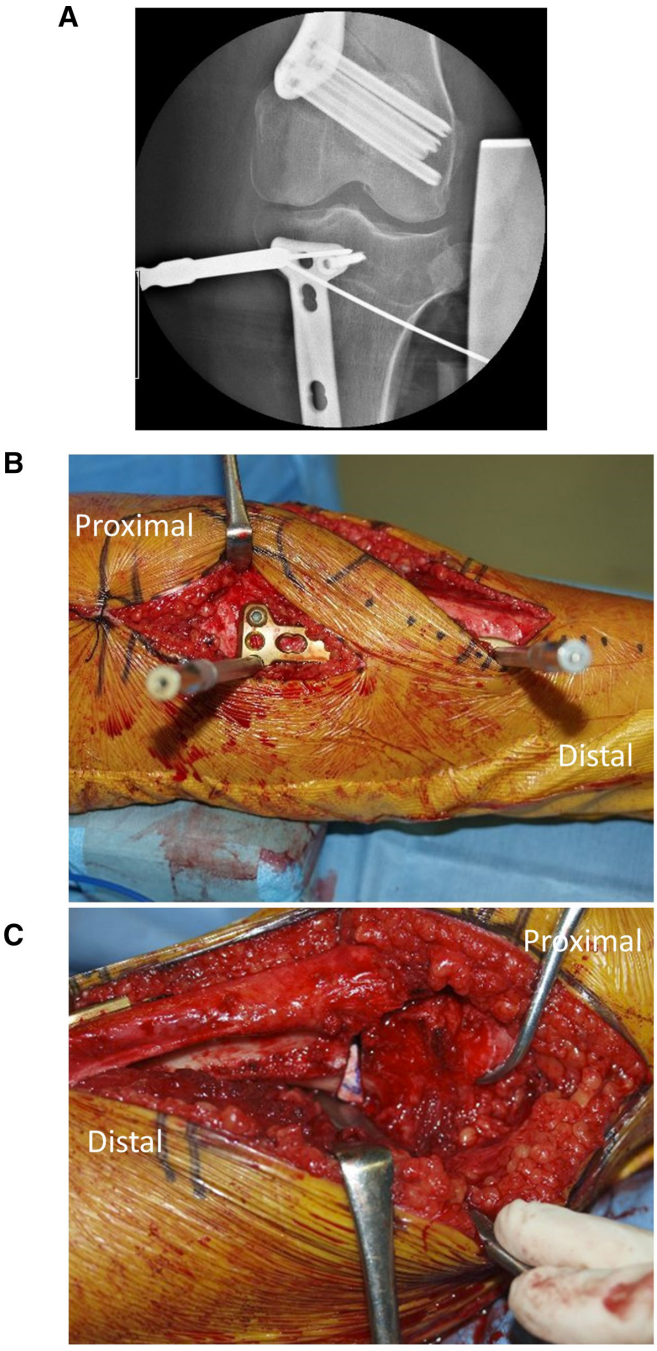

Figure 4 Medial plating before posterolateral opening. (A) Temporary fixation on the anteromedial side of the osteotomy level. (B) The proximal screw is inserted through the medial another skin incision, and the distal part of the plate is fixed through the lateral skin incision. (C) A posterolateral osteotomy line is shown. The beta-tricalcium phosphate is inserted in the direction of the posterolateral opening.

were corrected to 91° from 85° and 92° from 100°, respectively. The 3-dimensional CT demonstrated that the lateral tibial posterior slope angle decreased from 17° to 11° after surgery (figure 5E,F). Both coronal and sagittal alignments were maintained for 2 years after surgery (figure 5C,D), and the PTFJ dislocation was reduced over time (figure 5C,D).

At 2 years of follow-up, the patient reported no complaints and showed significant improvement in Knee Injury and Osteoarthritis Outcome Score. The score exceeded the

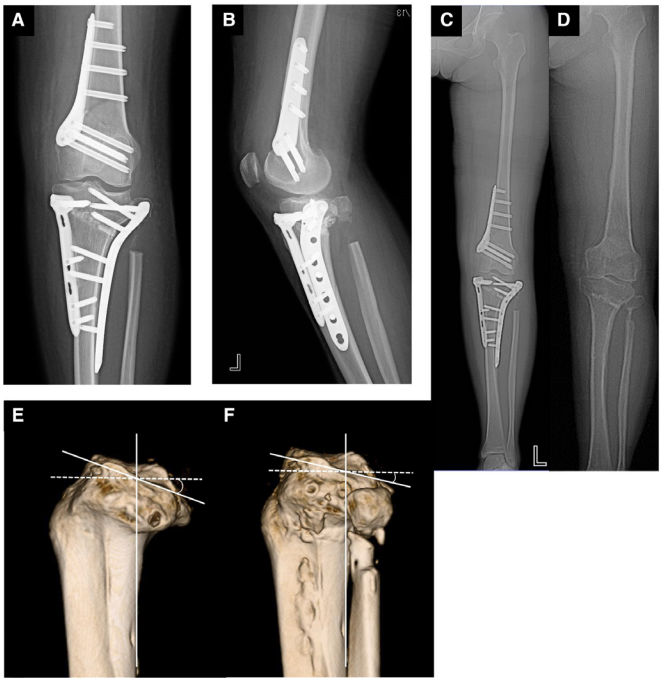

Figure 5 Postoperative images. (A) A radiograph of the anteroposterior view of the postoperative knee. (B) Lateral view. (C) A radiograph of the whole leg in the standing position demonstrates anatomical alignment. (D) A postoperative radiograph obtained after 2 years shows favorable alignment. (E) Preoperative posterior tibial slope angle. (F) Three-dimensional CT demonstrates that the posterior tibial slope angle decreased after surgery.

minimal clinically important difference[12] except for the symptom subscale (table 1).

DISCUSSION

Although there have been reports of dislocation of the hip, patella, shoulder, elbow joints, etc, in patients with EDS,[1–3] a case of dislocation of the PTFJ associated with EDS has never been reported. Traumatic PTFJ dislocation in adulthood, although rare,[13] provides little useful information about the effects of PTFJ dislocation in skeletally immature knees on bony growth and/or bony deformities. From the present case, we found that the dislocation of the fibula, which acts as a supporting strut for the posterolateral part of the tibial condyle,[14 15] caused dysplasia of the posterolateral tibia, resulting in valgus knee alignment. It is possible that excessive lateral compartment loading exerted a compression force on the distal lateral femur, which also induced a valgus deformity of the distal femur.

In comparison with other syndromic dysplasias of the knee joint such as Blount disease, Turner syndrome or Ellis-van Creveld syndrome, the skin and blood vessels of EDS patients should be treated with special care because of the fragility of the systemic connective tissue. Gentle retraction and careful haemostasis during surgery could be crucial to a successful osteotomy. The use of separate incisions—an anterolateral incision for the tibial osteotomy and a posterolateral incision for the fibular osteotomy/peroneal nerve release—may enhance security. To control bleeding, we used a non-tourniquet procedure under strict blood pressure control (< 100 mm Hg) to ensure that any vascular injury could be detected during surgery, thus mitigating the risk of postoperative haemorrhagic swelling.

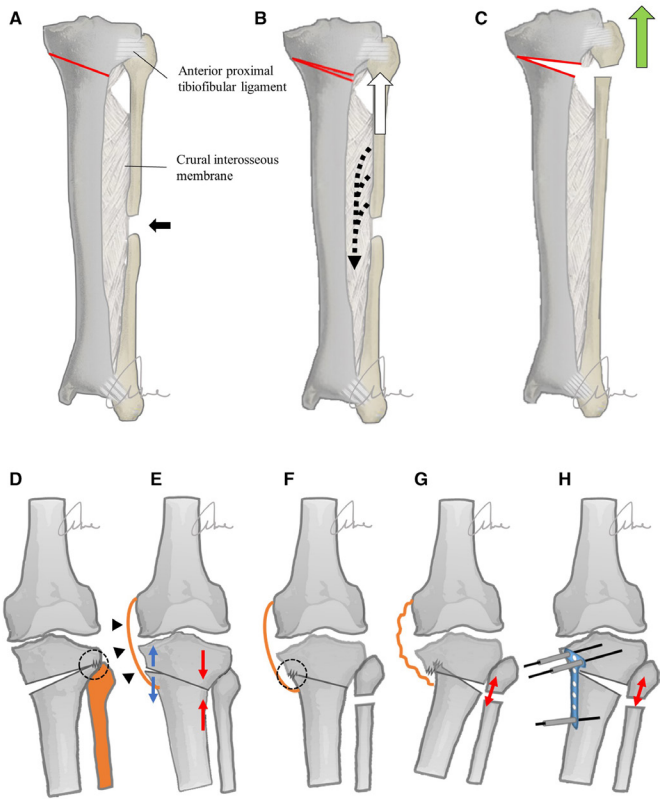

Figure 6 The role of the crural interosseous membrane and the stabilizing effect of each osteotomy. (A) Fibula osteotomy at the midportion and segmental resection (black arrow). (B) In opening the proximal tibia (red lines), the proximal part of the osteotomized fibula requires a proximal migration (white arrow) in synchrony with the tibia. The counterforce by the crural interosseous membrane inhibits the proximal migration of the fibula (black dotted arrow), which makes it difficult to open the gap. (C) The proximal fibular osteotomy immediately below the fibular head enables fibular proximal migration without any interference (green arrow). (D) In medial open-wedge high tibial osteotomy (HTO), the fibula supports the lateral stability when a hinge fracture (dotted circle) occurs. (E) In hybrid closed-wedge HTO, which is combinational HTO of medial open (blue arrows) and lateral close (red arrows), medial collateral ligament acts as tension band (black arrowheads), leading to medial stability. (F) In posterolateral open-wedge HTO, when a hinge fracture (dotted circle) occurs, (G) lateral osteotomized site opening (double-headed arrow) results in medial instability since medial collateral ligament does not act as a medial stabiliser. (H) Temporary fixation on the anteromedial side of the osteotomy provides medial stabilisation and facilitates the posterolateral opening maneuver (double-headed arrow). The figures were drawn by the first author (anonymised for the blinded review).

For patients with Blount disease or Turner syndrome, with severe varus of the knees with a single deformity centre around the medial tibial condyle, surgical correction with a large opening at one time should be avoided. An inverted V-shaped high tibial osteotomy,[16] which can reduce the opening distance, or gradual correction using the hemicallotasis method,[17] are possible options. For severe and complicated valgus deformity due to Ellis-van Creveld syndrome, two-step correction[18] may be the most reliable procedure. In the current case with EDS, the posterolateral opening distance was decreased by performing an MCWDFO according to the deformity analysis, reducing the

Learning points

- Proximal tibiofibular joint dislocation due to Ehlers-Danlos syndrome causes dysplasia of the posterolateral tibia, resulting in a severe valgus-aligned knee.
- Depending on the patient's condition and deformity, extra-articular osteotomy may be helpful in certain cases.
- In posterolateral open-wedge high tibial osteotomy (PLOWHTO), peroneal nerve neurolysis is necessary to avoid peroneal nerve palsy.
- PLOWHTO requires fibula osteotomy just below the fibula head to eliminate the effect of crural interosseous membrane stability.
- In PLOWHTO, anteromedial temporary fixation provides a medial stabilising effect.

risk of complications such as skin laceration, peroneal nerve palsy and/or delayed union.

The efficacy of TKA as a treatment for knee OA and joint instability associated with EDS has been reported previously.[19] However, it has also been reported that postoperative instability can necessitate revision surgery in some cases.[20 21] Since the valgus deformity was localised to the proximal tibia in this case, extra-articular osteotomy was a more logical and solution-oriented approach to the problems of joint laxity and deformity correction.

Considering the pathology, the correction osteotomy should be targeted for anatomical alignment. Therefore, we planned (1) the posterolateral opening osteotomy of the tibia and (2) the medial closing osteotomy of the distal femur. Although MCWDFO can be performed in the usual manner, PLOWHTO has several pitfalls.

The important points to be considered when using this technique are as follows: (1) peroneal nerve neurolysis is necessary; (2) fibula osteotomy is performed just below the fibular head and (3) the posterolateral gap is opened after temporary plate fixation of the anteromedial site. Mechanical stretching of the nerve is likely to contribute to nerve injury or ischaemia,[22 23] resulting in peroneal nerve palsy. Prior to fibula osteotomy, peroneal nerve neurolysis creates a working space for the osteotomy by retracting the peroneal nerve. Fibular osteotomy before PLOWTHO must be performed just below the fibular head because the crural interosseous membrane stabilises the positional relationship between the tibia and fibula (figure 6C). The crural interosseous membrane makes it challenging to open the gap if fibular osteotomy is performed at the midportion of the fibula (figure 6A,B). In medial OWHTO, the PTFJ stabilises the osteotomy site, even if a type I hinge fracture occurs (figure 6D).[24] In addition, in hybrid closed-wedge HTO, the medial collateral ligament acts as a tension band, leading to medial stability (figure 6E).[25] However, in PLOWHTO, there is no stabilising effect on the anteromedial aspect of the osteotomy site, which leads to instability following a hinge fracture (figure 6F,G). Therefore, temporary anteromedial plate fixation was necessary before opening the posterolateral gap (figure 6H). Attention to these critical factors can help reduce the risks of intraoperative and postoperative complications.

Although this is a report of a single rare case and its short-term outcome, PLOWHTO can be applied to cases of tibial plateau fractures with lateral tibial dysplasia. However, it remains unknown whether patients need to undergo additional surgery in the long term. Segmental osteotomy of the fibula might cause deformity of the tibia in the long term owing to the lack of support of the fibula. As segmental osteotomy of the fibula can shorten the course of the peroneal nerve, we performed segmental osteotomy in this case. Although the short-term clinical outcomes were favourable, further follow-up is required.

In conclusion, we performed a novel osteotomy adapted to the patient's pathology and deformity in a young patient with genu valgum due to EDS, which led to good short-term outcomes. PLOWHTO is considered a valuable surgical technique when performed with attention to pitfalls.

Acknowledgements We thank Hiroyuki Tsuchiya, MD, PhD, Atsushi Okawa, MD, PhD, Hideyuki Koga, MD, PhD for continuous support, Kaori Matsumoto for shooting photos and Editage. (www.editage.com) for English-language editing.

Contributors MA drafted the manuscript. MY and TT helped in surgery. RN performed the surgery and completed the final manuscript. All authors read and approved the final manuscript.

Funding The authors have not declared a specific grant for this research from any funding agency in the public, commercial or not-for-profit sectors.

Competing interests RN has a consultancy with Olympus Terumo Biomaterials.

Patient consent for publication Consent obtained directly from patient(s).

Provenance and peer review Not commissioned; externally peer reviewed.

ORCID iDs
Masaki Amemiya http://orcid.org/0000-0001-8532-6859
Ryuichi Nakamura http://orcid.org/0000-0002-1743-7749

REFERENCES

1 Rames RD, Strecker WB. Recurrent elbow dislocations in a patient with ehlers-danlos syndrome. *Orthopedics* 1991;14:707–9.
2 Kay RM, Skaggs DL. Bilateral hip dislocations in a father and son with ehlers-danlos syndrome. *Orthopedics* 2001;24:1165–6.
3 Homere A, Bolia IK, Juhan T, *et al*. Surgical management of shoulder and knee instability in patients with ehlers-danlos syndrome: joint hypermobility syndrome. *Clin Orthop Surg* 2020;12:279–85.
4 Beighton P, De Paepe A, Steinmann B, *et al*. Ehlers-danlos syndromes: revised nosology, villefranche, 1997. Ehlers-danlos national foundation (USA) and ehlers-danlos support group (UK). *Am J Med Genet* 1998;77:31–7.
5 Paley D, Herzenberg JE, Tetsworth K, *et al*. Deformity planning for frontal and sagittal plane corrective osteotomies. *Orthop Clin North Am* 1994;25:425–65.
6 Takeuchi R, Ishikawa H, Aratake M, *et al*. Medial opening wedge high tibial osteotomy with early full weight bearing. *Arthroscopy* 2009;25:46–53.
7 El-Azab H, Halawa A, Anetzberger H, *et al*. The effect of closed- and open-wedge high tibial osteotomy on tibial slope: a retrospective radiological review of 120 cases. *J Bone Joint Surg Br* 2008;90:1193–7.
8 Nakamura R, Akiyama T, Takeuchi R, *et al*. Medial closed wedge distal femoral osteotomy using a novel plate with an optimal compression system. *Arthrosc Tech* 2021;10:e1497–504.
9 Staubli AE, De Simoni C, Babst R, *et al*. TomoFix: a new LCP-concept for open wedge osteotomy of the medial proximal tibia--early results in 92 cases. *Injury* 2003;34 Suppl 2:55–62.
10 Lobenhoffer P, Agneskirchner JD. Improvements in surgical technique of valgus high tibial osteotomy. *Knee Surg Sports Traumatol Arthrosc* 2003;11:132–8.
11 Nakamura R, Kuroda K, Takahashi M, *et al*. Open wedge high tibial osteotomy with pes anserinus preservation and insertion of bone substitutes. *Arthrosc Tech* 2022;11:e69–78.
12 Jacquet C, Pioger C, Khakha R, *et al*. Evaluation of the "minimal clinically important difference" (MCID) of the KOOS, KSS and SF-12 scores after open-wedge high tibial osteotomy. *Knee Surg Sports Traumatol Arthrosc* 2021;29:820–6.
13 Cunningham NJ, Farebrother N, Miles J. Review article: isolated proximal tibiofibular joint dislocation. *Emerg Med Australas* 2019;31:156–62.

14 Nakamura R, Komatsu N, Murao T, *et al*. The validity of the classification for lateral hinge fractures in open wedge high tibial osteotomy. *Bone Joint J* 2015;97-B:1226–31.
15 Jiang W-B, Sun S-Z, Li C, *et al*. Anatomical basis of the support of fibula to tibial plateau and its clinical significance. *J Orthop Surg Res* 2021;16:346.
16 Kondo E, Yasuda K, Yabuuchi K, *et al*. Inverted V-shaped high tibial osteotomy for medial osteoarthritic knees with severe varus deformity. *Arthrosc Tech* 2018;7:e999–1012.
17 Oh C-W, Kim S-J, Park S-K, *et al*. Hemicallotasis for correction of varus deformity of the proximal tibia using a unilateral external fixator. *J Orthop Sci* 2011;16:44–50.
18 Kamada T, Mashima N, Imai H, *et al*. Successful two-step correction for severe genu valgum in ellis-van creveld syndrome: a case report. *J Orthop Case Rep* 2017;7:13–16.
19 Rose PS, Johnson CA, Hungerford DS, *et al*. Total knee arthroplasty in ehlers-danlos syndrome. *J Arthroplasty* 2004;19:190–6.
20 Ainsworth SR, Aulicino PL. A survey of patients with ehlers-danlos syndrome. *Clin Orthop Relat Res* 1993;286:250–6.
21 Tibbo ME, Wyles CC, Houdek MT, *et al*. Outcomes of primary total knee arthroplasty in patients with ehlers-danlos syndromes. *J Arthroplasty* 2019;34:315–8.
22 Schinsky MF, Macaulay W, Parks ML, *et al*. Nerve injury after primary total knee arthroplasty. *J Arthroplasty* 2001;16:1048–54.
23 Xu J, Liu H, Luo F, *et al*. Common peroneal nerve 'pre-release' in total knee arthroplasty for severe valgus deformities. *Knee* 2020;27:980–6.
24 Takeuchi R, Ishikawa H, Kumagai K, *et al*. Fractures around the lateral cortical hinge after a medial opening-wedge high tibial osteotomy: a new classification of lateral hinge fracture. *Arthroscopy* 2012;28:85–94.
25 Saito H, Saito K, Shimada Y, *et al*. Short-term results of hybrid closed-wedge high tibial osteotomy: a case series with a minimum 3-year follow-up. *Knee Surg Relat Res* 2018;30:293–302.