Bilateral serous choroidal detachment post panretinal photocoagulation as a clue in diagnosis of early diabetic nephropathy

Nidhi Mahendra Vithalani,[1] Akash Belenje,[1] Raja Narayanan [1,2]

[1]Srimati Kannuri Santhamma Centre for Vitreoretinal Diseases, LV Prasad Eye Institute, Hyderabad, Telangana, India
[2]Department of Retina, LV Prasad Eye Institute, Hyderabad, Telangana, India

Correspondence to
Dr Akash Belenje; akashbshetty01@gmail.com

Accepted 7 December 2021

To cite: Vithalani NM, Belenje A, Narayanan R. *BMJ Case Rep* 2022;**15**:e248272. doi:10.1136/bcr-2021-248272

DESCRIPTION

A 53-year-old man presented with complaints of bilateral painless progressive vision reduction for the previous year. He suffered from type 2 diabetes mellitus and hypertension for which he had been on oral medications for 5 years. His best-corrected visual acuity was 20/200 in the right eye and 20/100 in the left eye. The anterior segment evaluation of both eyes indicated the presence of cataractous lens with nuclear sclerosis of grade 2–3 and the intraocular pressures were within normal limits. Fundus evaluation indicated the presence of proliferative diabetic retinopathy (PDR) with extramacular tractional retinal detachment and hypertensive retinopathy with sclerosed vessels in the right eye and PDR with hypertensive retinopathy with sclerosed vessels in the left eye. He was then advised for panretinal photocoagulation (PRP) three-disc diameter away from the fibrovascular proliferation in both the eyes. The patient underwent first sitting of multi-spot 532 nm frequency-doubled Nd-YAG pattern scan laser (PASCAL) in two of the quadrants in both the eyes on the same day. The laser parameters for the PRP included a spot size of 200 µm, at 250–300 mW power for the duration of 40–50 ms, with each burn one spot-size apart to achieve a total of 1800 burns in two quadrants. A week later when the patient came for the second sitting laser there was a massive 360° choroidal detachment in the right eye (figure 1A) and nasal choroidal detachment in the left eye (figure 1B) with closely spaced high intense fresh laser burns in some areas. Visual acuity and intraocular pressure values remained stable in both eyes. The second sitting laser was withheld and the patient was started on hourly topical steroid (1% prednisolone acetate) and topical cycloplegic (2% homatropine hydrobromide) three times a day in both the eyes. On a high index of suspicion, the patient was also asked for physician evaluation with renal profile. The systemic evaluation by physician revealed an uncontrolled blood pressure of 200/134 mm Hg and also raised serum creatinine of 2.4 and blood urea levels of 51 indicating the presence of newly detected early diabetic nephropathy. Two weeks later, the choroidal detachment had completely subsided in both the eyes (figure 2) and the patient underwent second sitting laser after his blood pressure was under control. There was no choroidal detachment noted after the second sitting of laser. However, the patient developed preretinal haemorrhage and vitreous haemorrhage in his left eye 6 weeks later due to unstable PDR and was advised vitreoretinal surgery for the same.

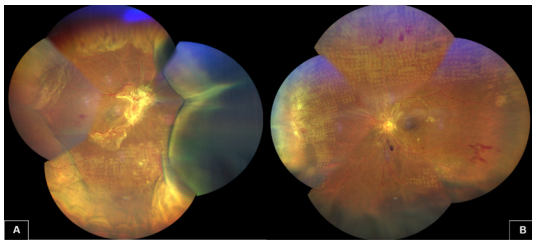

Figure 1 A (Right eye) B (Left eye): Right eye fundus image shows massive 360° choroidal detachment with fresh laser burns in inferior and nasal quadrants. Left eye fundus image shows nasal choroidal detachment with fresh laser burns superior and nasal quadrants.

The incidence of serous choroidal detachment has decreased with advent of multi-spot PASCAL laser which uses short pulse duration of laser when compared with the single spot laser.[1–4] The acute adverse effects like macular oedema, serous choroidal detachment and exudative retinal detachment can be expected due to high thermal energy delivery to retina and choroid due to increase in power, increase in duration and more number of spots per sitting.[1–4] The autoregulatory mechanism of choroidal vessels will be compromised in patients with malignant hypertension with renal failure due to fibrinous necrosis of vessel wall and hence their recovery to an insult like laser will be hampered making them more prone for serous choroidal detachment and exudative retinal detachments.[5 6] In our case although the spots were dense and closely packed in few areas we suspected that

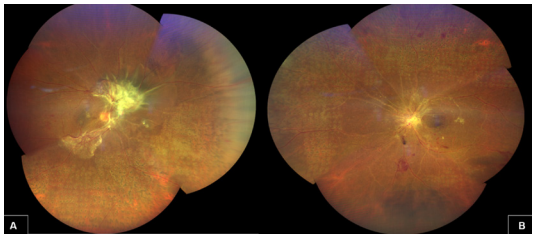

Figure 2 A (Right eye) B (Left eye): Complete resolution of choroidal detachment in both the eyes 2 weeks after systemic blood pressure control and topical med12ications.

the underlying systemic cause would have made the patient more prone for serous choroidal detachment and timely physician evaluation helped us in detecting the diabetic nephropathy at a very early stage.

Learning points

- High thermal energy delivery to retina and choroid can cause serous choroidal detachment even in multi-spot PASCAL laser.
- High index of suspicion regarding uncontrolled blood pressure and renal failure is necessary whenever we see serous choroidal detachment post laser.

Contributors NMV: Performed the laser, documented the fundus images. AB: Wrote the Manuscript. RN: Manuscript editing and managed the case.

Funding The authors have not declared a specific grant for this research from any funding agency in the public, commercial or not-for-profit sectors.

Competing interests None declared.

Patient consent for publication Consent obtained directly from patient(s).

Provenance and peer review Not commissioned; externally peer reviewed.

Case reports provide a valuable learning resource for the scientific community and can indicate areas of interest for future research. They should not be used in isolation to guide treatment choices or public health policy.

ORCID iD
Raja Narayanan http://orcid.org/0000-0001-9688-5859

REFERENCES

1 Nagpal M, Marlecha S, Nagpal K. Comparison of laser photocoagulation for diabetic retinopathy using 532-nm standard laser versus Multispot pattern scan laser. *Retina* 2010;30:452–8.
2 Deschler EK, Sun JK, Silva PS. Side-Effects and complications of laser treatment in diabetic retinal disease. *Semin Ophthalmol* 2014;29:290–300.
3 Salman AG. Pascal laser versus conventional laser for treatment of diabetic retinopathy. *Saudi J Ophthalmol* 2011;25:175–9.
4 Rajagopal S, Madhivanan N, Mayilvakanam L, *et al*. Choroidal Detachment Following Multi-spot Double Frequency Nd-YAG Retinal Photocoagulation - A Case Report. *J Lasers Med Sci* 2020;11:345–7.
5 Villalba-Pinto L, Hernández-Ortega M Ángeles, de Los Mozos FJL, *et al*. Massive bilateral serous retinal detachment in a case of hypertensive chorioretinopathy. *Case Rep Ophthalmol* 2014;5:190–4.
6 Kapoor A, Kumar A, Chawla R. Bilateral exudative retinal detachment and choroidopathy as the presenting signs of malignant hypertension. *BMJ Case Rep* 2021;14:e242413.