Uncommon cause of respiratory distress—late-presenting congenital diaphragmatic hernia

Suvi Alikärri,[1] Vilhelmiina Parikka ,[2,3] Mari Fihlman,[4] Arimatias Raitio [3,5]

[1]Department of Surgery, Porvoo Hospital, Porvoo, Finland
[2]Department of Paediatrics and Adolescent Medicine, Turku University Hospital, Turku, Finland
[3]Department of Clinical Medicine, University of Turku, Turku, Varsinais-Suomi, Finland
[4]Department of Anaesthesiology and Intensive Care, Turku University Hospital, Turku, Finland
[5]Department of Paediatric Surgery, Turku University Hospital, Turku, Finland

Correspondence to
Vilhelmiina Parikka;
vilpar@utu.fi

Accepted 22 August 2021

To cite: Alikärri S, Parikka V, Fihlman M, *et al*. *BMJ Case Rep* 2021;**14**:e245826. doi:10.1136/bcr-2021-245826

DESCRIPTION

A previously healthy 11-month-old boy was brought to the paediatric emergency unit due to breathing difficulties, tiredness and momentary loss of consciousness. His oxygen saturation was 95%. In a clinical examination, breathing sounds were not heard on the left side, and he was suffering from respiratory distress. Chest radiograph showed tracheal deviation, a mediastinal shift to the right and air-filled left thorax cavity (figure 1). These findings were reported as tension pneumothorax.

An emergency chest drain insertion in the operating theatre was scheduled. Initially, air was aspirated with a syringe, and a chest drain was inserted using the Seldinger technique,[1] resulting in a discharge of stomach contents from the drain. Esophagogastroscopy confirmed the drain to be in the stomach. Intraoperative C-arm fluoroscopy revealed an intrathoracic location of the stomach consistent with a diagnosis of congenital diaphragmatic hernia. After discussing with parents, the diaphragmatic defect was repaired in laparotomy and the stomach perforation was sutured. The recovery was uneventful, and the boy was discharged on the fifth postoperative day. During 2 years of follow-up, no respiratory or gastrointestinal complications have been observed (figure 2).

Congenital diaphragmatic hernia is an uncommon congenital defect with an incidence of one in 2500–3000 live births.[2] However, 5%–20% of the cases are diagnosed after the neonatal period.[3] Cases with late presentation may suffer from respiratory and/or gastrointestinal symptoms or be completely asymptomatic.[3] In this case, the presence of several air-filled cavities, indistinct diaphragm on the left side, as well as inability to visualise the normal gastric bubble in chest radiograph were signs not typical to pneumothorax, and should have raised suspicion of congenital diaphragmatic hernia. Late-presenting congenital diaphragmatic hernia should be kept in mind as a rare diagnostic possibility when interpreting chest radiographs.

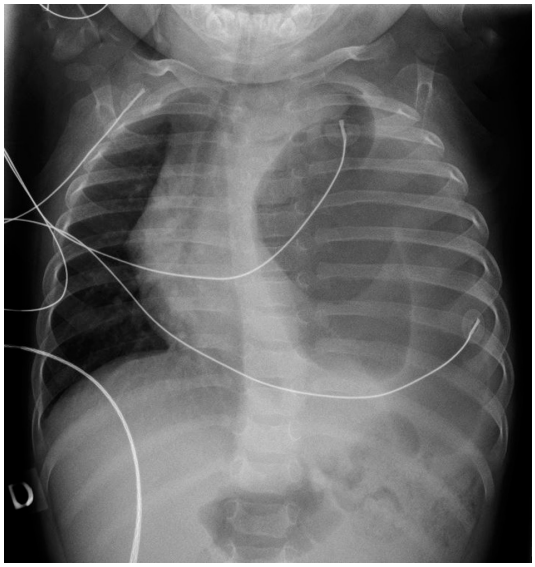

Figure 1 Preoperative chest radiograph with mediastinal shift.

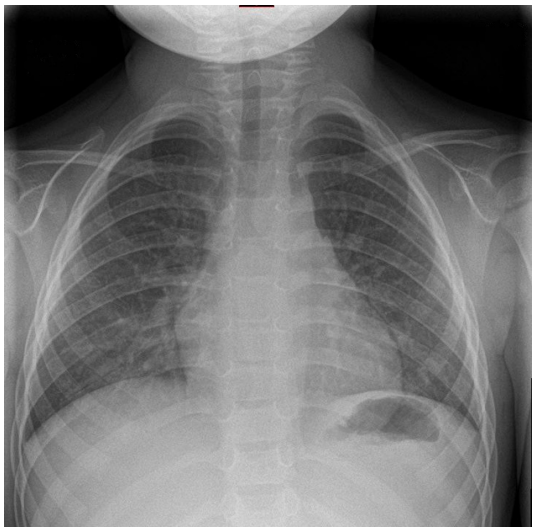

Figure 2 Chest radiograph 2 years after congenital diaphragmatic hernia repair.

Learning points

- Congenital diaphragmatic hernia is an uncommon congenital defect, which is typically diagnosed prenatally.
- In rare cases, respiratory distress might be caused by a late-presenting congenital diaphragmatic hernia.
- Careful analysis of radiographic findings coupled with high clinical suspicion is needed to avoid misdiagnosis of late-presenting congenital diaphragmatic hernia.

Twitter Arimatias Raitio @ArimatiasRaitio

Contributors SA drafted the manuscript; SA, VP, MF and AR edited the text and images. All authors approved the final version of the manuscript to be published.

Funding The authors have not declared a specific grant for this research from any funding agency in the public, commercial or not-for-profit sectors.

Competing interests None declared.

Patient consent for publication Obtained.

Provenance and peer review Not commissioned; externally peer reviewed.

ORCID iDs
Vilhelmiina Parikka http://orcid.org/0000-0002-9281-8154
Arimatias Raitio http://orcid.org/0000-0001-9114-2204

REFERENCES

1 McElnay PJ, Lim E. Modern techniques to insert chest drains. *Thorac Surg Clin* 2017;27:29–34.
2 Torfs CP, Curry CJ, Bateson TF, *et al*. A population-based study of congenital diaphragmatic hernia. *Teratology* 1992;46:555–65.
3 Bagłaj M, Dorobisz U. Late-presenting congenital diaphragmatic hernia in children: a literature review. *Pediatr Radiol* 2005;35:478–88.