

# Acute upper airway obstruction due to tonsillitis necessitating emergency cricothyroidotomy

Binu Ravindran, Feby Korandiarkunnel Paul, Prasad Vyakarnam

Anaesthesia, Dartford and Gravesham NHS Trust, Dartford, UK

**Correspondence to**  
Dr Binu Ravindran;  
b.ravindran@nhs.net

Accepted 12 July 2021

## SUMMARY

A 17-year-old man was admitted to Accident & Emergency out of hours with unilateral tonsillar enlargement covering more than 75% of his oropharyngeal inlet. He appeared calm and stable on initial presentation, but in a short span of time rapidly deteriorated, leading to near complete airway obstruction necessitating an emergency awake cricothyroidotomy. Tracheostomy and tonsillectomy were done after this, he was ventilated postoperatively in intensive therapy unit and discharged home in a week. This is a rare clinical scenario in a patient presenting with palatine tonsillitis. A few subtle points in the history and examination alerted the team and prevented a risky inter hospital transfer for ear, nose and throat review. This is the first reported case in UK of palatine tonsillitis not due to infectious mononucleosis presenting with acute upper airway obstruction in a patient with no airway anomalies. It may also have been a varied presentation of COVID-19.

## BACKGROUND

Tonsillitis, a commonly prevalent illness, can deteriorate rapidly to life-threatening airway compromise in a healthy young patient. Although a rare complication, subtle features in the history and examination can help predict critical deterioration to a reasonable degree. We report the case of a seventeen year old male who presented with unilateral enlarged tonsillitis and subsequently developed life-threatening upper airway obstruction necessitating an emergency cricothyroidotomy. This case also shows how clear communication, prompt action and teamwork helped save a young patient's life.

## CASE PRESENTATION

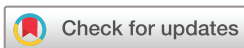A 17-year-old man presented to Accident & Emergency (A&E) with acute tonsillitis. He had a week's history of sore throat, odynophagia and malaise. He was able to swallow liquids and semisolids with difficulty but solid food particles got stuck to the back of his throat. These symptoms were worse for the last 2 days. There was a history of snoring but his sleep was adequate. He had a 2-day history of loss of voice and difficulty in breathing. He said he was unable to talk as he was not able to shift air through the mouth. There was a history of syncope at school the same day. He was previously fit and well with a history of recurrent tonsillitis for the past 2 years.

On examination, the patient was mobile with a normal build. He was alert with a Glasgow Coma Score of 15/15, heart rate 72 beats/min, normal sinus rhythm, normotensive (117/78 mm Hg), afebrile

at 36.8°C, respiratory rate 17/min and saturating 98% on room air. There was no stridor, drooling, trismus or cyanosis. The accessory muscles of respiration were inactive and there was no tracheal tug. He spoke in a low husky voice and looked anxious. Oral examination showed a right tonsillar swelling crossing the midline and occupying more than 75% of the oropharyngeal inlet (figure 1). The hard and soft palate and left tonsillar pillar were visible, but the right tonsillar pillar, the posterior oropharynx and the uvula were completely obliterated by the tonsillar mass. There was extensive inflammation and tenderness around the area. Apart from this, airway assessment was unremarkable and the cardiovascular and respiratory systems were normal. The laboratory blood results were unremarkable with C reactive protein (CRP) <5 mg/L, white cell count (WCC)  $9.1 \times 10^9/L$  and normal renal functions and serum electrolytes.

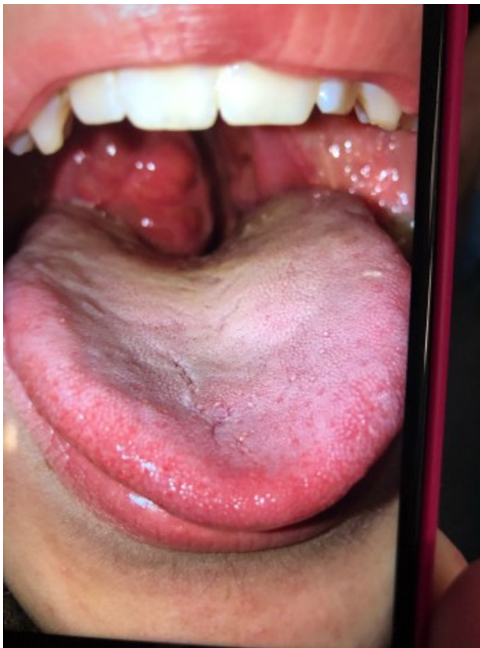## TREATMENT

The patient's airway was deemed unsafe by the anaesthetist for inter hospital patient transfer to avail ear, nose and throat (ENT) services and a decision was made to observe the patient overnight in A&E. He was treated with benzyl penicillin, analgesics, dexamethasone and intravenous fluids. Within an hour of anaesthetic review, the patient deteriorated rapidly. He developed inspiratory stridor and tachypnoea with prominent accessory muscles of respiration. He was saturating 100% on high flow oxygen and was haemodynamically stable with no cyanosis. Despite being given epinephrine nebulisation twice, upper airway obstruction worsened. Jaw thrust relieved the obstruction temporarily. Urgent ENT help was summoned from a nearby hospital and difficult airway equipment arranged. The patient started deteriorating rapidly at this point with jaw thrust no longer relieving the obstruction. He developed paradoxical chest movements but remained haemodynamically stable. Considering the possibility of losing the airway in an attempt to intubate, airway plans were changed and an awake cricothyroidotomy under local anaesthetic was performed by the ENT surgeon while jaw thrust was maintained by the anaesthetist with the patient remaining in the sitting position. Ventilation was established through a size 6 mm internal diameter endotracheal tube and end tidal carbon dioxide confirmed. Propofol boluses were given and he was transferred from A&E to theatres. The patient was anaesthetised with sevoflurane, propofol and alfentanil boluses and paralysed with rocuronium. Emergency tracheostomy and tonsillectomy were performed followed by fiberoptic endoscopy of the



© BMJ Publishing Group Limited 2021. No commercial re-use. See rights and permissions. Published by BMJ.

**To cite:** Ravindran B, Korandiarkunnel Paul F, Vyakarnam P. *BMJ Case Rep* 2021;**14**:e242500. doi:10.1136/bcr-2021-242500



**Figure 1** Right tonsillar mass covering more than 75% of the oropharyngeal inlet with only a slit available for passage of air.

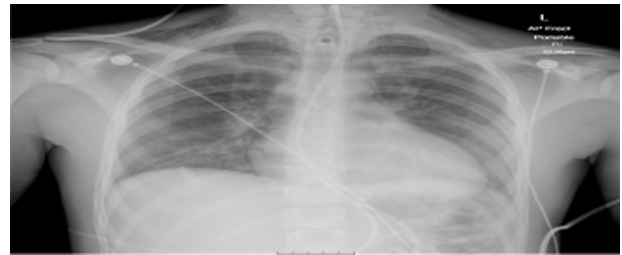trachea and vocal cords by the ENT surgeon. The patient was then transferred to Intensive therapy unit (ITU) and ventilated postoperatively for 2 days. He developed surgical emphysema and negative pressure pulmonary oedema postoperatively.

### INVESTIGATIONS

Blood reports showed a transient lymphopaenia of  $0.8 \times 10^9/L$ , neutrophilia of  $8.1 \times 10^9/L$ , WCC of  $10.8 \times 10^9/L$  and CRP of 33 mg/L on admission to ITU which later normalised (table 1). Apart from this, full blood count, renal functions and liver functions were unremarkable except for a raised alanine transaminase of 89 U/L, fibrinogen of 8.3 g/L and prolonged prothrombin time of 13.3 s.

Cultures of tracheal aspirates, throat swab, urine, faeces, wound swab and blood were negative for all bacteria including *Salmonella*, *Shigella*, *Cryptosporidium*, *Campylobacter*, *Escherichia coli* and beta-haemolytic Streptococci. Screening was negative for Toxoplasma, *Clostridium difficile*, Epstein-Barr virus and Cytomegalovirus and throat swab viral PCR negative for coronavirus, adenovirus, influenza A&B viruses, metapneumovirus parainfluenza virus, rhinovirus, enterovirus, respiratory syncytial virus and bocavirus. A specific SARS-CoV-2 test was not done.

Chest X-ray confirmed subcutaneous emphysema in the neck and supraclavicular regions (figure 2). CT chest postsurgery showed extensive subcutaneous and mediastinal emphysema



**Figure 2** Chest X-ray showing subcutaneous emphysema at the base of the neck and supraclavicular regions bilaterally.

with mild bilateral basal ground glass opacities and consolidation (figure 3). Bronchoscopy confirmed a posterior tracheal tear with a possible involvement of the posterior aspect of the vocal cords.

### OUTCOME AND FOLLOW-UP

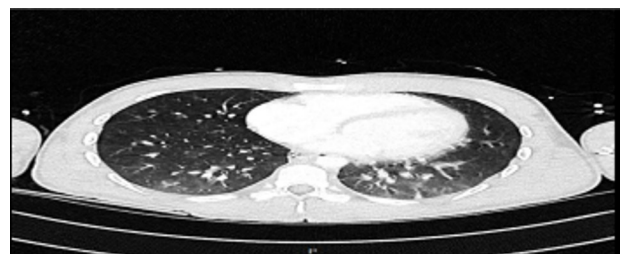
The patient had episodes of anxiety and panic attacks which were treated with anxiolytics.

The tracheal tear was managed conservatively with spontaneous ventilation, dexamethasone, antibiotics tazobactam and piperacillin, and the patient made a full recovery. Trachea was decannulated on the fourth day and he was discharged home on the sixth day postsurgery.

At 8 months, following the event, he still has occasional weakness of voice which is gradually improving and his voice is getting stronger. He is also undergoing treatment and counselling for post-traumatic stress disorder. He has otherwise been leading a normal and active life, going to school and engaged in singing and sports.

### DISCUSSION

Tonsillitis is inflammation of tonsils which are lymphoid tissue in the pharynx. These tissues form the Waldeyer's ring composed of lingual, palatine and adenoids. Tonsillitis can cause abscess formation, epiglottitis and obstructive sleep apnoea, but it is rarely known to cause life threatening airway compromise. Infectious mononucleosis can cause massive tonsillar enlargement and pharyngeal oedema leading to upper airway obstruction.<sup>1,2</sup> It causes oedema of the uvula, epiglottis, arytenoids and forms dystrophic calcifications and tonsilloliths presenting with airway obstruction.<sup>3</sup> Michael Balfour-Lynn reported infections like laryngotracheobronchitis, epiglottitis caused by H influenza B, bacterial tracheitis, diphtheria, retropharyngeal and peritonsillar abscess leading to upper airway obstruction.<sup>4</sup> Epstein-Barr virus, a common aetiological agent known to cause massively enlarged tonsils, tested negative in this patient. Appelblatt and Baker described a functional component to airway obstruction severe enough to warrant tracheostomy.<sup>5</sup> Fondaw *et al* reported a case of COVID-19 presenting with upper airway obstruction



**Figure 3** CT chest showing bilateral interstitial changes.

Investigations	Day 1	Day 4	Normal range
Haemoglobin	126 g/L	146 g/L	(120–150) g/L
Haematocrit	38%	43%	(40–50)%
WCC	$10.8 \times 10^9/L$	$7.5 \times 10^9/L$	$(4.0–11.0) \times 10^9/L$
Lymphocytes	$0.8 \times 10^9/L$	$2.0 \times 10^9/L$	$(1.0–4.0) \times 10^9/L$
Neutrophils	$8.1 \times 10^9/L$	$3.9 \times 10^9/L$	$(2.0–7.0) \times 10^9/L$
Platelets	$242 \times 10^9/L$	$253 \times 10^9/L$	$(150–410) \times 10^9/L$

WCC, white cell count.

due to acute epiglottitis requiring emergency surgical cricothyroidotomy.<sup>6</sup> Our case could have been a varied presentation of COVID-19. Considering that this occurred in beginning of the COVID-19 pandemic, there arises a suspicion whether SARS-CoV-2 could have caused this. A single throat swab was negative for corona virus PCR. The patient had mild bilateral ground glass changes on CT chest and the blood results showed a lymphopaenia and raised fibrinogen. A specific SARS-CoV-2 test and other COVID-19-related tests were not done as knowledge of COVID-19 was limited and guidance regarding this was not available at the time. Chronic airway obstruction can lead to pulmonary hypertension and consequent cor pulmonale.<sup>7,8</sup> Lingual tonsils are notorious in causing unanticipated airway obstruction during anaesthesia being asymptomatic and undetected on routine airway assessment.<sup>9-11</sup> Stone and Thomas reported, palatine tonsils in a 24-year-old man, not due to infectious mononucleosis, presenting with acute severe airway obstruction requiring emergency transfer to theatres for airway management.<sup>12</sup> The conventional method of attempting intubation under anaesthesia risked ending in a cannot intubate, cannot ventilate situation in our patient. A tracheostomy was also not feasible in this rapidly deteriorating clinical scenario, hence an awake cricothyroidotomy was done under local anaesthetic after a collective decision with ENT.

Here, we try to comprehend the reason behind airway obstruction, the cause for rapid deterioration, how this can be predicted and why this particular management option was selected. The patient looked calm and comfortable on initial examination. The history of syncope could probably be a vasovagal attack secondary to pain. It could very rarely be due to intermittent airway obstruction due to mechanical pressure on the larynx as explained by Fries *et al.*<sup>13</sup> The history of difficulty in talking due to inability to shift air through the mouth points out significant airway obstruction. The sudden deterioration could be due to the sheer size of the tonsil opposing the post pharyngeal wall or the surrounding inflammation and oedema causing obstruction as described by Balfour-Lynn and Wright.<sup>4</sup> An abscess was ruled out during the operation. Mouth breathing could lead to dryness and stickiness of the tonsils. Mc Donnell *et al* reported the successful use of epinephrine in relieving acute airway obstruction by reducing oedema due to vasoconstriction.<sup>14</sup> Was epinephrine counterproductive in this case, leading to airway dryness and tissue stickiness? Negative pressure generated due to air hunger may have created a suction effect and sealed the airway. Patient anxiety and consequent rapid breathing could have contributed to this. Airway occlusion caused by posterior displacement of the epiglottis by the enlarged tonsil, though more likely in the case of lingual tonsil, could probably occur in palatine tonsillitis if it is massively enlarged. Laryngospasm is also a possibility due to altered swallowing mechanisms. Gupta and Cheifetz described the efficacy of heliox when used early in acute disease process but then again, this limits the fraction of inspired oxygen and was unavailable in the hospital.<sup>15</sup>

Numerous ways of dealing with an acute airway obstruction exist and there are a multitude of gadgets available. The difficult airway society guidelines advice to proceed to plan D or cricothyroidotomy in a cannot intubate cannot ventilate scenario.<sup>16</sup> It could be argued that an attempt could have been made at intubation. The patient was on the verge of a respiratory arrest with rapidly progressive airway obstruction. It was decided to proceed with an emergency awake cricothyroidotomy considering the possibility of exacerbating a cannot intubate cannot oxygenate scenario. This enabled the team to remain in control of the situation with the patient breathing spontaneously till a definitive

### Patient's perspective

I couldn't get any air into my lungs, several people were bent on top of me on the table and I was extremely scared. Someone pushed my jaw, this gave me some relief and when they cut the front of my neck, I could finally breathe. I panicked, but now when I look back, I am happy to be sitting here and talking to my parents. I am very thankful to all the hospital staff who looked after me.

### Learning points

- ▶ Tonsillar enlargement occupying more than 75% of the oropharyngeal inlet could rapidly progress to severe airway compromise, even though the patient may appear misleadingly calm when seen initially.
- ▶ Subtle points in the history and examination may alert us to the likelihood of developing airway obstruction.
- ▶ An element of flexibility to existing guidelines may in the rarest of occasions be required to solve a critical situation, but it has to be properly justified.
- ▶ There is no substitute for good communication and teamwork especially in a life-threatening and time pressured scenario.

airway was secured. This was a team decision based purely on clinical judgement. Jones and Cohle reported a 23-year-old woman with lingual tonsils causing unanticipated difficult airway and cannot intubate cannot ventilate situation following induction of anaesthesia and ending with cerebral anoxia and death.<sup>11</sup> Hillman *et al* stated that anaesthesia increased the risk of airway obstruction and difficult intubation in tonsillar hypertrophy and advised to secure the airway before anaesthesia if a doubt exists.<sup>17</sup> Thus, while it is essential to stick to difficult airway guidelines, there could be times when an element of flexibility is required depending on the clinical scenario at hand with prime regard to patient safety. Cricothyroidotomy can have serious complications like endotracheal tube misplacement, tracheal and vocal cord injury, vocal cord granuloma and paralysis, pneumonia, retropharyngeal abscess and late complications like tracheal and subglottic stenosis.<sup>18</sup> This incident was complicated by a posterior tracheal tear and minor injury to the vocal cords, which is a known complication in emergency cricothyroidotomy by conventional palpation method, even in experienced hands. The tracheal tear could perhaps have been avoided by prior use of airway ultrasound and also by directing the scalpel perpendicular to the skin.<sup>19,20</sup> Considering the imminent airway threat and time constraints, these measures could not be instituted but as the injuries were minor, they healed with conservative management.

**Contributors** BR and FKP obtained patient consent, wrote, edited and reviewed the final draft. PV obtained the photograph and reviewed the final draft.

**Funding** The authors have not declared a specific grant for this research from any funding agency in the public, commercial or not-for-profit sectors.

**Competing interests** Obtained.

**Patient consent for publication** Not required.

**Provenance and peer review** Not commissioned; externally peer reviewed.

This article is made freely available for use in accordance with BMJ's website terms and conditions for the duration of the covid-19 pandemic or until otherwise determined by BMJ. You may use, download and print the article for any lawful,



non-commercial purpose (including text and data mining) provided that all copyright notices and trade marks are retained.

## REFERENCES

- Chan SC, Dawes PJ. The management of severe infectious mononucleosis tonsillitis and upper airway obstruction. *J Laryngol Otol* 2001;115:973-7.
- Ala-Kokko TI, Kyllönen M, Nuutinen L. Management of upper airway obstruction using a Seldinger minitracheotomy kit. *Acta Anaesthesiol Scand* 1996;40:385-8.
- Lo R-H, Chang K-P, Chu S-T. Upper airway obstruction caused by bilateral giant tonsilloliths. *J Chin Med Assoc* 2011;74:329-31.
- Balfour-Lynn IM, Wright M. Acute infections that produce upper airway obstruction. *Kendig's Disorders of the Respiratory Tract in Children* 2019;9:406-19.
- Appelblatt NH, Baker SR. Functional upper airway obstruction. A new syndrome. *Arch Otolaryngol* 1981;107:305-6.
- Fondaw A, Arshad M, Batool S, et al. COVID-19 infection presenting with acute epiglottitis. *J Surg Case Rep* 2020;2020:280.
- Menashe VD, Farrehi C, Miller M. Hypoventilation and cor pulmonale due to chronic upper airway obstruction. *J Pediatr* 1965;67:198-203.
- Massumi RA, Sarin RK, Pooya M, et al. Tonsillar hypertrophy, airway obstruction, alveolar hypoventilation, and cor pulmonale in twin brothers. *Dis Chest* 1969;55:110-4.
- Ovassapian A, Glassenberg R, Randel GI, et al. The unexpected difficult airway and lingual tonsil hyperplasia: a case series and a review of the literature. *Anesthesiology* 2002;97:124-32.
- Davies S, Ananthanarayan C, Castro C. Asymptomatic lingual tonsillar hypertrophy and difficult airway management: a report of three cases. *Can J Anaesth* 2001;48:101020-1024.
- Jones DH, Cohle SD. Unanticipated difficult airway secondary to lingual tonsillar hyperplasia. *Anesth Analg* 1993;77:1285-8.
- Stone CK, Thomas SH. Upper airway obstruction from tonsillar infection in adults. *Eur J Emerg Med* 1994;1:37-41.
- Fries MR, Galindo RL, Flint PW, et al. Giant fibrovascular polyp of the esophagus. A lesion causing upper airway obstruction and syncope. *Arch Pathol Lab Med* 2003;127:485-7.
- MacDonnell SP, Timmins AC, Watson JD. Adrenaline administered via a nebulizer in adult patients with upper airway obstruction. *Anaesthesia* 1995;50:35-6.
- Gupta VK, Cheifetz IM. Heliox administration in the pediatric intensive care unit: an evidence-based review. *Pediatric Critical Care Medicine* 2005;6:204-11.
- Henderson JJ, Popat MT, Latta IP, et al. Difficult airway Society guidelines for management of the unanticipated difficult intubation. *Anaesthesia* 2004;59:675-94.
- Hillman DR, Platt PR, Eastwood PR. The upper airway during anaesthesia. *Br J Anaesth* 2003;91:31-9.
- Zasso FB, You-Ten KE, Ryu M, et al. Complications of cricothyroidotomy versus tracheostomy in emergency surgical airway management: a systematic review. *BMC Anaesthesiol* 2020;20:216.
- Asai T. Emergency Cricothyrotomy: Toward a Safer and More Reliable Rescue Method in "Cannot Intubate, Cannot Oxygenate" Situation. *Anesthesiology* 2015;123:995-6.
- Siddiqui N, Arzola C, Friedman Z, et al. Ultrasound improves cricothyrotomy success in cadavers with poorly defined neck anatomy: a randomized control trial. *Anesthesiology* 2015;123:1033-41.

Copyright 2021 BMJ Publishing Group. All rights reserved. For permission to reuse any of this content visit <https://www.bmj.com/company/products-services/rights-and-licensing/permissions/>  
BMJ Case Report Fellows may re-use this article for personal use and teaching without any further permission.

Become a Fellow of BMJ Case Reports today and you can:

- ▶ Submit as many cases as you like
- ▶ Enjoy fast sympathetic peer review and rapid publication of accepted articles
- ▶ Access all the published articles
- ▶ Re-use any of the published material for personal use and teaching without further permission

### Customer Service

If you have any further queries about your subscription, please contact our customer services team on +44 (0) 207111 1105 or via email at [support@bmj.com](mailto:support@bmj.com).

Visit [casereports.bmj.com](http://casereports.bmj.com) for more articles like this and to become a Fellow