Bilateral multifocal choroidal metastasis as the presenting feature of non-small-cell lung carcinoma

Athul Suresh Puthalath ,[1] Ramanuj Samanta ,[1] Prashant Joshi,[2] Sreeram Jayaraj[1]

[1]Ophthalmology, All India Institute of Medical Sciences - Rishikesh, Rishikesh, Uttarakhand, India
[2]Pathology, All India Institute of Medical Sciences - Rishikesh, Rishikesh, Uttarakhand, India

Correspondence to
Dr Ramanuj Samanta; ramanuj.samanta@gmail.com

Accepted 6 April 2021

To cite: Puthalath AS, Samanta R, Joshi P, *et al*. *BMJ Case Rep* 2021;**14**:e242264. doi:10.1136/bcr-2021-242264

DESCRIPTION

A 46-year-old man was referred to our centre with blurring of vision in both eyes (BE) since 1 month and breathlessness for last 1 week. He was an active smoker with 13.6 pack-years of exposure. Ocular examination revealed a best-corrected visual acuity of 20/60 and 20/80 in right and left eye, respectively. Anterior segments were unremarkable in BE. Funduscopy (figure 1A,B) showed bilateral multiple elevated creamy-yellow subretinal lesions in the postequatorial area. Localised retinal pigment epithelium (RPE) layer alteration was also noted in left eye. His medical history was insignificant. Ultrasound of BE (figure 1C,D) showed multifocal echo-dense lesions on B-scan with corresponding hyper-reflectivity in A-scan, at sites clinically correlating to the subretinal lesions. BE optical coherence tomography (figure 1E,F) showed multiple choroidal elevations with undulating RPE, adjacent hyperintense irregularities in photoreceptor layer and pockets of subretinal fluid. With a strong suspicion of choroidal metastasis from unknown primary source, detailed laboratory workup and systemic evaluation by physicians were undertaken. Chest X-ray (figure 2A) was suggestive of left sided pleural effusion with lung collapse. Contrast-enhanced CT of thorax (figure 2D–E) demonstrated bilateral multiple discrete lung nodules with interstitial thickening, left lower neck and axillary lymph nodes and subtle sclerotic lesions in D3 and D4 vertebral bodies favouring metastasis. Histopathological examination from endobronchial biopsy confirmed the diagnosis of non-small-cell lung carcinoma (NSCLC)—not otherwise specified (figure 2F–H). Complete metastatic workup was performed subsequently. Contrast-enhanced MRI of brain (figure 2B,C) revealed multiple variably sized punctate enhancing lesions in the brain parenchyma suggesting metastasis. Bone scan also revealed multiple bony metastases throughout the body. His TNM staging was T4N3M1C with final stage IV B. He was explained about the disease prognosis and was started on chemotherapy regimen including gemcitabine and carboplatin.

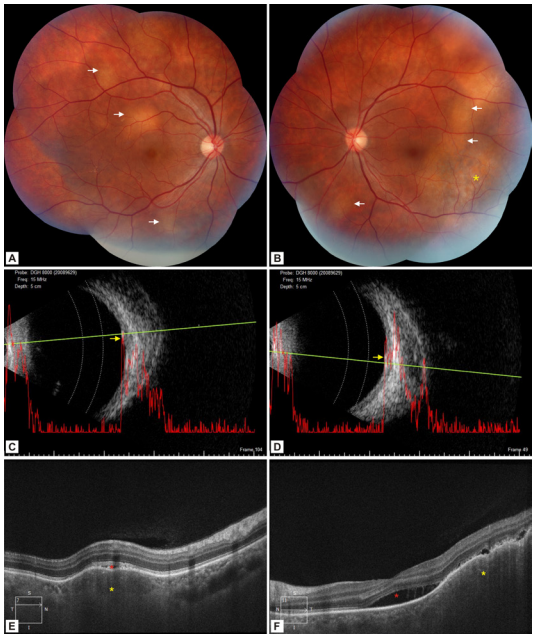

Figure 1 Fundus images of right (A) and left eye (B) showing multiple creamy yellow subretinal lesions (white arrows) with associated RPE changes (yellow star). Ultrasound B-scan images of both eyes (C, D) showing choroidal mass lesion with hyper-reflective echo in corresponding A-scan (yellow arrows). Optical coherence tomography of right (E) and left eye (F) revealing choroidal elevations (yellow star) with accompanying subretinal fluid (red star) and adjacent photoreceptor irregularities.

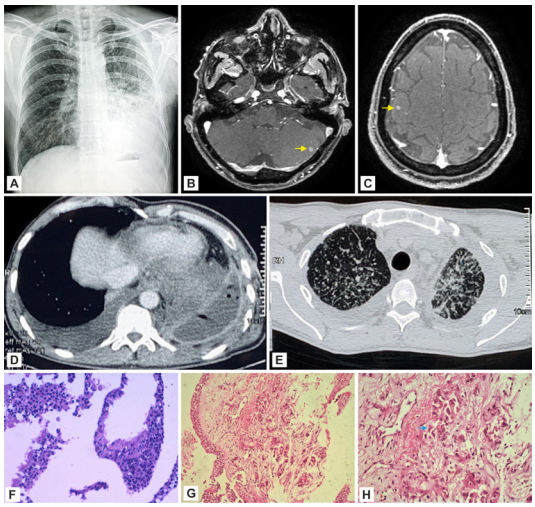

Figure 2 Chest X-ray of the patient (A) demonstrating left-sided pleural effusion with lung collapse. CEMRI brain (B, C) showing focal enhancing punctate lesions (yellow arrows) in cerebellum (B) and right frontal grey white junction (C) suggestive of brain metastasis. CECT chest (D, E) showing small free pleural effusion on right side and loculated pleural effusion with split pleura sign on left side (D); numerous micronodules in random distribution in both lung apices (E). Formalin-fixed paraffin-embedded sections examined from endobronchial biopsy (F–H) showing strips of metaplastic and dysplastic respiratory mucosa (F, H&E; ×200) and atypical cells infiltrating into the submucosal stroma (G, H&E; ×200). Few of these cells show pale blue cytoplasm, suggesting mucin, which could not be further confirmed due to paucity of these cells (blue arrow) (H, H&E; ×400).

Due to the ongoing COVID-19 pandemic, the patient was lost to follow-up.

Choroid is the most common ocular segment affected by metastasis, with lung carcinoma being the most common cause in men (40%) and breast carcinoma (68%) in women.[1] Ocular metastasis may be seen in 0.2%–7% of lung carcinoma patients.[2] Usually NSCLC progresses less rapidly and has delayed metastasis compared with the small cell type.[3] Lung carcinoma tend to have unilateral, unifocal ocular metastasis, whereas bilateral, multifocal metastases are more common in breast carcinoma.[1] However, our patient had bilateral multifocal presentation. Such a clinical manifestation has uncommonly been reported in literature.[4–6]

Blurring of vision and ocular pain are the most commonly reported ocular symptoms in choroidal metastasis from lung carcinoma.[1 7] In 44%–72% patients, uveal metastasis preceded the diagnosis of lung carcinoma.[7–9] Observation is advised for terminally ill patients with poor systemic status. Systemic chemotherapy, immunotherapy, hormone therapy or whole eye radiotherapy can be tried in bilateral multifocal choroidal metastases. Plaque radiotherapy, transpupillary radiotherapy or photodynamic therapy are reserved for solitary metastasis while enucleation can be done for painfully blind eyes.[10] The mean interval from uveal metastasis diagnosis to death varied from 7.5 months to 12 months in the literature.[7 8]

It is imperative to keep the possibility of choroidal metastasis in mind while evaluating the eyes of such patients. A multidisciplinary approach is warranted in such cases to treat and improve the quality of life.

Learning points

- Ophthalmic manifestations might be the presenting feature in patients with undiagnosed lung carcinoma and ocular features may precede systemic complaints.
- Complete ophthalmic evaluation must be followed by detailed laboratory investigations, physician evaluation and metastatic workup in suspected cases.

Twitter Athul Suresh Puthalath @asputhalath

Acknowledgements We acknowledge the patient and the departments of Pulmonology, Medical Oncology, Radiology and Pathology of our institute.

Contributors ASP: data acquisition, data analysis, drafting of the manuscript, approval of the final version of the manuscript. RS: conception of study, data interpretation, drafting and critical revision of the manuscript, approval of the final version of the manuscript. PJ: data acquisition, data interpretation, approval of the final version of the manuscript. SJ: data acquisition, data analysis and interpretation, drafting of the manuscript, approval of the final version of the manuscript. All authors have approved the final version to be published.

Funding The authors have not declared a specific grant for this research from any funding agency in the public, commercial or not-for-profit sectors.

Competing interests None declared.

Patient consent for publication Obtained.

Provenance and peer review Not commissioned; externally peer reviewed.

ORCID iDs
Athul Suresh Puthalath http://orcid.org/0000-0002-0483-7014
Ramanuj Samanta http://orcid.org/0000-0002-9737-8346

REFERENCES

1 Shields CL, Shields JA, Gross NE, *et al*. Survey of 520 eyes with uveal metastases. *Ophthalmology* 1997;104:1265–76.
2 Kreusel K-M, Wiegel T, Stange M, *et al*. Choroidal metastasis in disseminated lung cancer: frequency and risk factors. *Am J Ophthalmol* 2002;134:445–7.
3 Hoffman PC, Mauer AM, Vokes EE. Lung cancer. *Lancet* 2000;355:479–85.
4 Ascaso FJ, Castillo JM, García FJ, *et al*. Bilateral choroidal metastases revealing an advanced non-small cell lung cancer. *Ann Thorac Surg* 2009;88:1013–5.
5 Namad T, Wang J, Tilton A, *et al*. Bilateral choroidal metastasis from non-small cell lung cancer. *Case Rep Oncol Med* 2014;2014:1–5.
6 Abundo RE, Orenic CJ, Anderson SF, *et al*. Choroidal metastases resulting from carcinoma of the lung. *J Am Optom Assoc* 1997;68:95–108.
7 Shah SU, Mashayekhi A, Shields CL, *et al*. Uveal metastasis from lung cancer: clinical features, treatment, and outcome in 194 patients. *Ophthalmology* 2014;121:352–7.
8 Meziani L, Cassoux N, Le Rouic LL, *et al*. Uveal metastasis revealing lung cancer. *J Fr Ophtalmol* 2012;35:420–5.
9 Kreusel K-M, Bechrakis NE, Wiegel T, *et al*. Incidence and clinical characteristics of symptomatic choroidal metastasis from lung cancer. *Acta Ophthalmol* 2008;86:515–9.
10 Arepalli S, Kaliki S, Shields CL. Choroidal metastases: origin, features, and therapy. *Indian J Ophthalmol* 2015;63:122–7.