



OPEN ACCESS

# Pulmonary arteriovenous malformation with metal allergy

Yoshiaki Takase ,<sup>1</sup> Sachiko Nakano,<sup>2</sup> Ei Yamaki,<sup>1</sup> Osamu Kawashima<sup>1</sup>

<sup>1</sup>Thoracic Surgery, National Hospital Organization Shibukawa Medical Center, Shibukawa, Gunma, Japan  
<sup>2</sup>Nuclear Medicine, The Cancer Institute Hospital Of JFCR, Koto-ku, Tokyo, Japan

**Correspondence to**  
Dr Yoshiaki Takase;  
y.takase0315@gmail.com

Accepted 2 March 2021

## SUMMARY

We present a rare case of single pulmonary arteriovenous malformation (PAVM) with multiple metal allergies, including for platinum. A 47-year-old woman presented to our hospital without any symptoms. Enhanced computed tomography showed a single PAVM in S6 of the right lung. Interviews prompted us to suspect a history of palmoplantar pustulosis associated with metal dental filling. Dermatology patch tests for metal allergy were positive for platinum, cobalt, tin and potassium dichromate. The first choice of treatment for PAVM is endovascular treatment using a metal coil. Since the coil is composed of platinum alloy, we performed partial lung resection for PAVM without metal implants. Although metal allergy is rare for endovascular treatment, it causes an additional stress of removal of causative metal or long-term steroidal treatment. Therefore, for single PAVM with multiple metal allergies to the implants, surgical treatment without metal implants should be considered.

## BACKGROUND

Pulmonary arteriovenous malformation (PAVM) is an abnormal communication between the pulmonary artery and pulmonary vein without an intervening capillary communication. Life-threatening complications of PAVM are stroke, cerebral abscess, transient ischaemic attack, massive haemoptysis and haemothorax. Therefore, prompt treatment is essential to minimise morbidity and mortality.<sup>1</sup> Until recently, the mainstay of treatment was endovascular embolisation of the feeding artery. Currently, international guidelines by an expert panel consider that surgical management of PAVMs plays a minimal role, other than the management of life-threatening bleeding in a centre where there is no expertise in embolotherapy.<sup>2</sup> Some studies of unruptured cerebral aneurysm have reported that embolotherapy using a metal coil caused complications in a patient with metal allergy.<sup>3</sup> Regarding PAVM, there have been no reports of adverse events of metal allergy due to the coil. In the present case, we performed surgical resection without metal implants for a patient with multiple metal allergies.

## CASE PRESENTATION

A 47-year-old woman presented to us without any symptoms such as cyanosis and club fingers. Chest radiography had revealed an abnormal shadow in the right middle lung field at another hospital (figure 1A) and she was subsequently referred to our institution. Enhanced computed tomography (CT) showed a single PAVM in S6 of the right lung (figure 1B–D). This PAVM had a single feeding

artery. No AVM was detected in the brain on MRI and in the abdomen on CT. She had no family history of haemorrhagic telangiectasia (HHT). She did not meet the diagnostic criteria of HHT, the Curaçao Criteria,<sup>4</sup> which includes the presence of PAVM, recurrent epistaxis, telangiectasia and a family history of HHT.

## INVESTIGATIONS

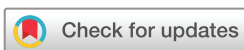Initially, we planned to perform the embolisation using a metal coil for the single PAVM. However, our interviews with her revealed that the removal of a dental filling improved the eczema of her palms. A history of palmoplantar pustulosis associated with a metal dental filling was suspected. We needed to change the strategy of treatment due to a history of palmoplantar pustulosis associated with metal allergy. Dermatology patch tests for metal allergies tested positive for platinum, cobalt, tin and potassium dichromate. Commonly, the metal coil used for blood vessels is composed of a platinum alloy.

## TREATMENT

We decided to perform pulmonary wedge resection for the PAVM without metal implants via video-assisted thoracic surgery (VATS). We used one camera port and performed a small thoracotomy (6 cm skin incision). A part of the S6 lung parenchyma, including the PAVM, was resected using two clamping forceps (DeBakey aortic aneurysm clamp) to prevent bleeding from the feeding artery and drainage vein. Stumps of the feeding artery and drainage vein were sutured with the surrounding lung parenchyma by Z-suture with 4–0 polypropylene. The residual lung parenchyma of S6 was sutured by running locking suture with 4–0 polypropylene without releasing the clamp (figure 2). We did not use biological adhesives because the patient was a young non-smoker and the intraoperative sealing test showed no air leaks.

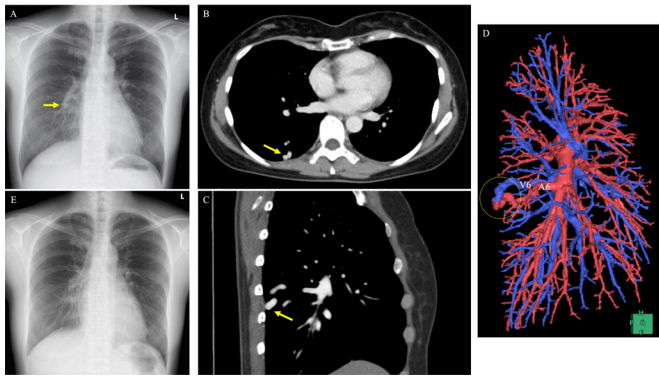
## OUTCOME AND FOLLOW-UP

The postoperative course was uneventful. There was minimal blood loss and no air leaks. The drain was removed on postoperative day 1. She was ready to be discharged on postoperative day 2 but was discharged on postoperative day 6 because she felt very anxious about being discharged early. The pathological findings revealed PAVM (figure 3). At the 2-week follow-up, the abnormal shadow of the PAVM was no longer present in the postoperative chest radiograph (figure 1E). The CT showed no recurrence of PAVM at 6 months after the surgery.



© BMJ Publishing Group Limited 2021. Re-use permitted under CC BY-NC. No commercial re-use. See rights and permissions. Published by BMJ.

**To cite:** Takase Y, Nakano S, Yamaki E, et al. *BMJ Case Rep* 2021;**14**:e240275. doi:10.1136/bcr-2020-240275

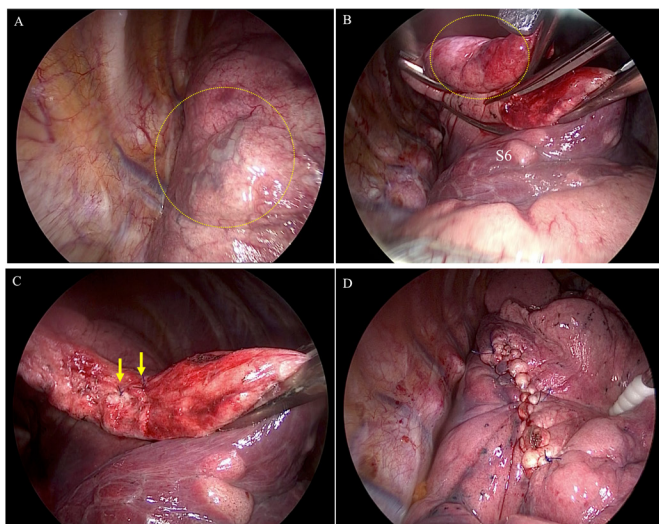


**Figure 1** (A) Chest radiograph showing an abnormal shadow at the right middle lung field (arrow). (B) CT scan on axial section. (C) CT scan on sagittal section showing a pulmonary arteriovenous malformation in the right lower lobe (arrow). (D) 3D-CT showing nidus from the feeding artery (A6) and drainage vein (V6) (dashed circle). (E) Postoperative chest radiograph acquired at 2-week follow-up.

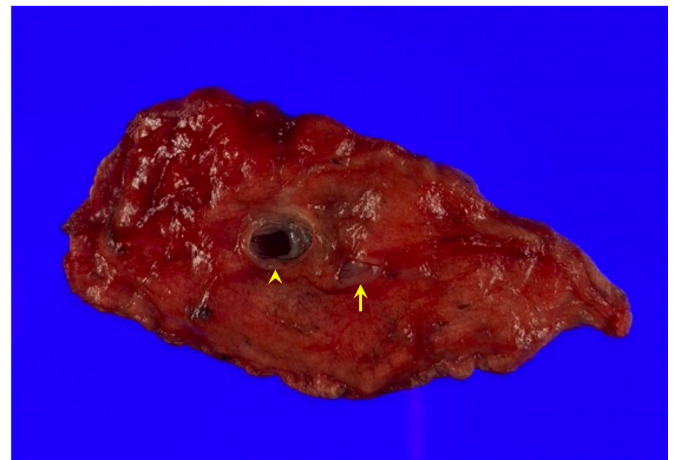
## DISCUSSION

In the field of interventional radiology, it is common to use metals as medical materials for embolisation of the brain, heart and blood vessels of the whole body. Platinum is the main component of metal coil for PAVM. Some reports have shown that endovascular treatment for patients with platinum allergy can lead to a decreased quality of life and patient satisfaction due to skin symptoms such as rash, eczema or urticaria.<sup>3–5–8</sup> Long-term administration of low-dose steroid or removal of the indwelling metals were needed for treating the skin symptoms.<sup>3–5–8</sup> The removal of the causative metal can be the first choice if it is possible anatomically.

In order to avoid unnecessary invasive treatment, careful interview of metal allergies is essential for the treatment of



**Figure 2** Findings and surgical procedures during video-assisted thoracic surgery. (A) A pulmonary arteriovenous malformation (PAVM) was detected in S6. (B) A part of S6 lung parenchyma including the PAVM was resected using two clamping forceps (DeBakey aortic aneurysm clamp). (C) Stumps of the feeding artery and drainage vein were sutured with the surrounding lung parenchyma by Z-suture with 4-0 polypropylene. (D) The residual lung parenchyma of S6 was sutured by running locking suture with 4-0 polypropylene without releasing the clamp.



**Figure 3** Pathological findings of the resected lung specimen. Cross section of the feeding artery (arrow) and drainage vein (arrow head).

PAVM. In this case, an interview with her revealed that previously an erythema on her palms improved by the removal of dental metals. Therefore, we were able to suspect a history of palmoplantar pustulosis associated with metal allergy.

Surgical resection is usually performed to treat patients with a small number of fistulas that are not suitable for catheter embolisation. For peripheral fistulas, pulmonary wedge resection is a good option because fistulas can be easily resected with stapling devices. For centrally located or large fistulas, segmentectomy or lobectomy is often used.<sup>9</sup> A previous report in 2001 showed that fistulectomy can be an alternative to segmentectomy.<sup>10</sup> However, there are few reports of fistulectomy for PAVM since then. A previous study reported six cases of PAVM in the periphery of the lung that were treated successfully with VATS. Pulmonary wedge resection via VATS is a feasible, alternative treatment for arteriovenous malformations located in the periphery of the lung parenchyma when pulmonary embolisation therapy is difficult or unsuccessful.<sup>11</sup> In our case, pulmonary wedge resection was appropriate to treat the single PAVM since it was located in the periphery of the right lower lobe.

Although surgical management of PAVMs plays a minimal role, this is a good indication for patients with metal allergy.<sup>1</sup> In the field of thoracic surgery, using stapling devices is convenient and safe to dissect the blood vessels and lung parenchyma. Currently, the available material for the staple is pure titanium or

## Learning points

- ▶ We present a surgical case of single pulmonary arteriovenous malformation (PAVM) with multiple metal allergies, including platinum.
- ▶ Since the first choice of treatment for PAVM is endovascular treatment using a metal coil, it is very important to have an interview to probe for metal allergy.
- ▶ We should keep in mind that palmoplantar pustulosis after a dental treatment is a symptom of metal allergy.
- ▶ Although metal allergies of platinum or titanium are rare, it can cause an additional stress to remove the causative metal or long-term steroidal treatment.
- ▶ In a patient with single PAVM and multiple metal allergies who is planning to undergo endovascular treatment, surgical treatment without metal implants should be considered.

a titanium alloy. In this case, a patch test had revealed no allergy for titanium. However, there is no reliable method to diagnose titanium allergy.<sup>12</sup> Rare cases of titanium allergy despite high biocompatibility of titanium have been previously reported.<sup>12</sup>

A previous report showed that patients with titanium allergy tend to be allergic to other metals as well.<sup>13</sup> Even though the titanium patch test is negative for patients with multiple metal allergies, it is safer to avoid titanium implants. In this case, we performed partial lung resection without metal implants such as stapling devices. It was a reasonable strategy to perform partial lung resection without metal implants for this patient with multiple metal allergies.

**Acknowledgements** Yoshinori Koyama MD, PhD, Department of Diagnostic Radiology National Hospital Organization Shibukawa Medical Center, provided the guidance and helpful discussions. The authors thank Editage (<https://www.editage.jp/>), for editing a draft of this manuscript.

**Contributors** YT and SN drafted the manuscript. EY and OK gave final approval of the version to be published. All authors read and approved the final manuscript.

**Funding** The authors have not declared a specific grant for this research from any funding agency in the public, commercial or not-for-profit sectors.

**Competing interests** None declared.

**Patient consent for publication** Obtained.

**Provenance and peer review** Not commissioned; externally peer reviewed.

**Open access** This is an open access article distributed in accordance with the Creative Commons Attribution Non Commercial (CC BY-NC 4.0) license, which permits others to distribute, remix, adapt, build upon this work non-commercially, and license their derivative works on different terms, provided the original work is properly cited and the use is non-commercial. See: <http://creativecommons.org/licenses/by-nc/4.0/>.

#### ORCID iD

Yoshiaki Takase <http://orcid.org/0000-0002-5159-4174>

#### REFERENCES

- 1 Tellapuri S, Park HS, Kalva SP. Pulmonary arteriovenous malformations. *Int J Cardiovasc Imaging* 2019;35:1421–8.
- 2 Faughnan ME, Palda VA, Garcia-Tsao G, et al. International guidelines for the diagnosis and management of hereditary haemorrhagic telangiectasia. *J Med Genet* 2011;48:73–87.
- 3 Uwatoko T, Tsumoto T, Wada N, et al. Dermatitis caused by metal allergy after coil embolization for unruptured cerebral aneurysm. *BMJ Case Rep* 2015;2015:bcr2015011981.
- 4 Shovlin CL, Guttmacher AE, Buscarini E, et al. Diagnostic criteria for hereditary hemorrhagic telangiectasia (Rendu-Osler-Weber syndrome). *Am J Med Genet* 2000;91:66–7.
- 5 Nagata Y, Kawakubo Y. Sutenntojyokyo ni yori hishinn ga kaizensita zennshingata-Kinnzokuarerugii [Systemic-allergy with improved rash by stent removal]. *Pract Dermatol* 2013;35:441–4.
- 6 Jetty P, Jayaram S, Veinot J, et al. Superficial femoral artery nitinol stent in a patient with nickel allergy. *J Vasc Surg* 2013;58:1388–90.
- 7 Giménez-Arnau A, Riambau V, Serra-Baldrich E, et al. Metal-induced generalized pruriginous dermatitis and endovascular surgery. *Contact Dermatitis* 2000;43:35–40.
- 8 Clague GA, McGann G, Gilbert H. An unusual allergy to platinum embolization coils. *Cardiovasc Intervent Radiol* 2012;35:215–6.
- 9 Sano A, Tsuchiya T. Thoracoscopic surgery for multiple peripheral pulmonary arteriovenous fistulas. *Ann Thorac Surg* 2015;99:1808–9.
- 10 Schröder C, Fröhlich G, Harms CP, Kleckow M, et al. Fistulectomy as an alternative to segmentectomy for pulmonary arteriovenous fistula. *J Thorac Cardiovasc Surg* 2001;122:386–8.
- 11 Nakajima J, Takamoto S, Takeuchi E, et al. Thoracoscopic surgery for pulmonary arteriovenous malformation. *Asian Cardiovasc Thorac Ann* 2006;14:412–5.
- 12 Fage SW, Muris J, Jakobsen SS, et al. Titanium: a review on exposure, release, penetration, allergy, epidemiology, and clinical reactivity. *Contact Dermatitis* 2016;74:323–45.
- 13 Kim KT, Eo MY, Nguyen TTH, et al. General review of titanium toxicity. *Int J Implant Dent* 2019;5:10.

Copyright 2021 BMJ Publishing Group. All rights reserved. For permission to reuse any of this content visit <https://www.bmj.com/company/products-services/rights-and-licensing/permissions/>  
BMJ Case Report Fellows may re-use this article for personal use and teaching without any further permission.

Become a Fellow of BMJ Case Reports today and you can:

- ▶ Submit as many cases as you like
- ▶ Enjoy fast sympathetic peer review and rapid publication of accepted articles
- ▶ Access all the published articles
- ▶ Re-use any of the published material for personal use and teaching without further permission

#### Customer Service

If you have any further queries about your subscription, please contact our customer services team on +44 (0) 207111 1105 or via email at [support@bmj.com](mailto:support@bmj.com).

Visit [casereports.bmj.com](http://casereports.bmj.com) for more articles like this and to become a Fellow