



OPEN ACCESS

# Successful thrombolysis of normotensive pulmonary embolism with life-threatening hypoxia in a young man with Klinefelter syndrome

Nuwan Dhanushka Miththinda Jasenth Kankanamage <sup>1,2</sup>, James Gome<sup>1,2</sup>

<sup>1</sup>Deakin University - Warrnambool Campus, Warrnambool, Victoria, Australia  
<sup>2</sup>Department of Medicine, South West Healthcare, Warrnambool, Victoria, Australia

## Correspondence to

Dr Nuwan Dhanushka Miththinda Jasenth Kankanamage; jkndmiththinda@gmail.com

Accepted 11 February 2021

## SUMMARY

Klinefelter syndrome (KS) affects males born with an additional X chromosome giving the genotype 47XXY classically. This syndrome has primary features of infertility and hypogonadism along with other features including a genetically hypercoagulable state. When associated with other risk factors, KS further increases the risk of venous thromboembolism and could result in life-threatening pulmonary embolism (PE). There should be a lower threshold in suspecting PE as a cause of acute respiratory failure in this patient group and thrombolysis should be considered early in normotensive PE with severe hypoxia for best patient outcomes. Furthermore, clinicians should be cautious in managing testosterone therapy in patients with KS and additional thromboembolic risk factors.

## BACKGROUND

Klinefelter syndrome (KS) is considered to be the most common sex chromosome disorder. An Australian prevalence study had reported a rate of 223 per 100 000 males, with up to 50% of cases remaining undiagnosed.<sup>1</sup> Affected males have an additional X chromosome leading to poor development of male secondary sexual characteristics. Other than these phenotypic changes, these patients are more prone to cardiovascular, endocrine and psychiatric disorders.<sup>2</sup> KS is also considered to be a genetically hypercoagulable state where affected individuals have been shown to be four times more likely to have venous thromboembolism (VTE).<sup>2</sup> The standardised incidence ratio for VTE is reported to be highest before 30 years of age at 12%.<sup>3</sup> The current hypothesis for this hypercoagulable state is the presence of increased levels of plasminogen activator inhibitor 1 (PAI-1) in KS, related to obesity and low testosterone levels. Despite this, a study by Zitzmann *et al* did not demonstrate a change in PAI-1 levels in patients who are treated with testosterone therapy.<sup>4</sup> Other hypotheses for the hypercoagulable state seen in this patient group include an increase in factor VIII and IX levels due to the genes coding for these factors being located on the X chromosome. A case series of six KS patients with deep venous thrombosis (DVT) has shown elevated factor VIII levels, but this was not significantly different from a control population with VTE.<sup>5</sup>

The Pulmonary Embolism International Thrombolysis Study (PEITHO) trial demonstrated that fibrinolytic therapy in patients with intermediate-severity pulmonary embolism (PE) prevented

haemodynamic decompensation but increased the risk of major haemorrhage and stroke.<sup>6</sup> A third of the patients in the PEITHO trial complained of persisting dyspnoea at 3-month follow-up, but over 80% had only low or intermediate probability of persisting or new-onset pulmonary hypertension at echocardiographic follow-up. Based on these data, the latest guidelines for PE by the European Society of Cardiology do not recommend routine thrombolysis for intermediate-risk PE. On the other hand, a small randomised trial of 83 patients suggested that thrombolysis in submassive PE improved the functional capacity at 3 months compared with anticoagulation alone.<sup>7</sup>

Here, we report a case of a young man with KS presenting with submassive PE complicated by pneumomediastinum and pneumopericardium with severe hypoxic respiratory failure prompting successful thrombolysis with good functional outcomes.

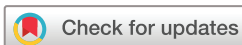## CASE PRESENTATION

A young man in his mid-20s with KS presented to the emergency department with fluctuating generalised ill health and worsening shortness of breath for 2 weeks. He had an associated persistent dry cough and mild subjective fevers. He denied any pleuritic chest pain and could not recall any preceding calf tenderness and had no identifiable risk factors for VTE except his father having experienced an unprovoked DVT in the past with a negative thrombophilia screen. The patient had been diagnosed with KS at the age of 18 months with XXYY karyotype while being investigated for developmental delay and has been on testosterone replacement since the age of 15 years with a current testosterone regimen of intramuscular testosterone undecanoate 1000 mg at 3 monthly interval. He was otherwise healthy.

On examination, he was of a lean build with a well-grown beard. He was tachypnoeic (up to 40 breaths/min), tachycardic (up to 140 beats/min), and peripherally and centrally cyanosed. His blood pressure remained stable over 100/60 mmHg. He had occasional crepitations on bilateral lung fields. His oxygen saturation (SPO<sub>2</sub>) on room air was 74% and was promptly commenced on a non-rebreather with improvement of SPO<sub>2</sub> to 85%.

## INVESTIGATIONS

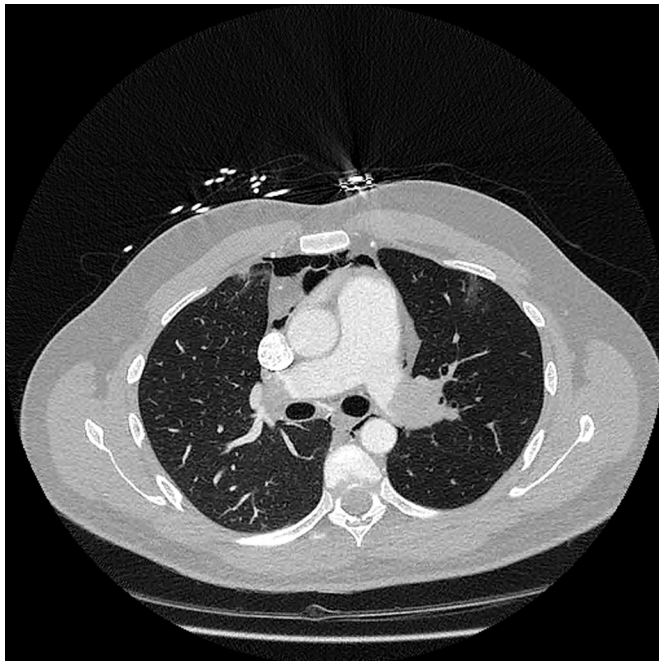
Arterial blood gas performed on admission demonstrated type 1 respiratory failure with



© BMJ Publishing Group Limited 2021. Re-use permitted under CC BY-NC. No commercial re-use. See rights and permissions. Published by BMJ.

## To cite:

Jasenth Kankanamage NDM, Gome J. *BMJ Case Rep* 2021;**14**:e240118. doi:10.1136/bcr-2020-240118



**Figure 1** Bilateral pulmonary embolism with pneumomediastinum and pneumopericardium.

PaO<sub>2</sub> of 52 mmHg. ECG showed tachycardia with S1-Q3-T3 pattern. An urgent CT pulmonary angiogram (CTPA) was performed on high suspicion of PE. This demonstrated a completely occluded left main pulmonary artery with a large embolus and another embolus in the right main pulmonary artery extending into the right middle and lower lobe arteries extensively and to the upper lobe arteries to a lesser extent. CTPA further demonstrated pneumomediastinum and pneumopericardium (figure 1). Closer evaluation of his CTPA revealed alveolar rupture leading to pneumomediastinum and pneumopericardium which was attributed to barotrauma from the persistent dry cough.

Bedside echocardiogram demonstrated ballooning of the right ventricle, suggestive of significant pulmonary hypertension and his troponin I was elevated at 162 ng/L (<21 ng/L).

### TREATMENT

He was at high risk according to the simplified PE severity index with a 30-day mortality prediction of 8.9%. Due to the high oxygen requirement and severity of clot burden with persistent tachycardia and right ventricular strain, it was decided to thrombolysate him. He received intravenous alteplase 10 mg loading followed by a 90 mg infusion. His saturation improved gradually over a 6-hour period up to 100% on room air. He received therapeutic dose subcutaneous enoxaparin for 7 days following thrombolysis and was changed to oral apixaban 5 mg two times per day for life-long therapy on discharge.

### OUTCOME AND FOLLOW-UP

His testosterone level was 25.4 nmol/L (normal range 10–35 nmol/L). This was 9 weeks after his regular testosterone undecanoate therapy. He was noted to be polycythaemic with a haemoglobin level of 209 g/L and haematocrit of 0.63. The elevated erythropoietin level at 42 mIU/mL (normal range 5–25 mIU/mL) suggests secondary polycythaemia. His haemoglobin level and haematocrit improved to 152 g/L and 0.45, respectively, at the time of discharge. A thrombophilia

screen was negative for any secondary causes including JAK2 mutation, antiphospholipid antibodies, anti nuclear antibody, extractable nuclear antigen, vasculitis screening, homocysteine level and prothrombotic gene mutations.

On follow-up at 3 months, he had returned to his baseline functional capacity and his repeat echocardiogram showed complete resolution of right ventricular strain with normal cardiac function. In the long-term management of his testosterone replacement therapy, it was decided to recommence his testosterone only when the serum testosterone level falls below 10 nmol/L.

### DISCUSSION

Our patient had multiple risk factors for VTE. KS is known to increase the risk of VTE. He had a family history of unprovoked DVT, although the thrombophilia screening for both him and his father could not identify a hereditary cause. His polycythaemia could have predisposed him to VTE and was likely multifactorial from hypoxia, dehydration and testosterone therapy. The fact that he tolerated an SPO<sub>2</sub> down to 74% in the community was remarkable and we postulate that the secondary polycythaemic response may have allowed him to tolerate such severe hypoxia. Although he was not hypotensive, severe hypoxic respiratory failure with signs of right ventricular strain prompted the decision for thrombolysis. Current guidance for PE thrombolysis mostly depends on failed haemodynamics and suggests close monitoring and consideration of rescue thrombolysis for cases like our patient.<sup>8</sup> Several researchers have highlighted the need for thrombolysis in severe hypoxic respiratory failure with preserved haemodynamics.<sup>9,10</sup> Percutaneous catheter-directed therapy is currently recommended for haemodynamically unstable PE with contraindications for thrombolysis.<sup>8</sup> As our patient did not have any contraindications for thrombolysis, this was not considered. Our patient clearly improved with thrombolysis with normalisation of his oxygenation from SPO<sub>2</sub> of 74%–100% within hours and his full recovery without any evidence of pulmonary hypertension speaks to the dramatic improvement achieved with this therapy. Polycythaemia is one of the most common side effects of testosterone therapy.<sup>11</sup> Regardless of this, a systematic review of six randomised trials and five observational studies failed to show an association between testosterone therapy and thromboembolism.<sup>12</sup> Despite this, provided the multiple risk factors our patient had for VTE, it was decided to minimise

### Learning points

- ▶ Clinicians should be cognisant about the hypercoagulable state of Klinefelter syndrome, especially when the patient has other risk factors for venous thromboembolism (VTE).
- ▶ We propose that clinicians use a cautious and closely supervised approach to testosterone replacement therapy in patients with other risk factors for VTE.
- ▶ Clinicians should be aware of the current limitations for thrombolysis recommendations in pulmonary embolism (PE) which entirely depend on haemodynamic instability, and should carefully explore the need for thrombolysis in normotensive PE with refractory hypoxic respiratory failure on a case-by-case basis, which in our case led to optimum patient outcomes both in the short and long term.

any risk testosterone-related polycythaemia could cause by targeting his testosterone therapy towards the lower limit of normal.

**Twitter** Nuwan Dhanushka Miththinda Jasenth Kankanamage @jkndmiththinda

**Contributors** NDMJK managed the acute presentation of the case and continues to follow up the case. JG provided Endocrinology input in management. NDMJK did the initial literature review, composed the original draft and prepared the images. JG contributed with literature review and provided critical feedback to the manuscript. All authors contributed to editing and finalising the manuscript and have given final approval to the version submitted and are accountable for the content submitted.

**Funding** The authors have not declared a specific grant for this research from any funding agency in the public, commercial or not-for-profit sectors.

**Competing interests** None declared.

**Patient consent for publication** Obtained.

**Provenance and peer review** Not commissioned; externally peer reviewed.

**Open access** This is an open access article distributed in accordance with the Creative Commons Attribution Non Commercial (CC BY-NC 4.0) license, which permits others to distribute, remix, adapt, build upon this work non-commercially, and license their derivative works on different terms, provided the original work is properly cited and the use is non-commercial. See: <http://creativecommons.org/licenses/by-nc/4.0/>.

#### ORCID iD

Nuwan Dhanushka Miththinda Jasenth Kankanamage <http://orcid.org/0000-0001-7497-1676>

## REFERENCES

- 1 Herlihy AS, Halliday JL, Cock ML, *et al*. The prevalence and diagnosis rates of Klinefelter syndrome: an Australian comparison. *Med J Aust* 2011;194:24–8.
- 2 Bojesen A, Juul S, Birkebaek NH, *et al*. Morbidity in Klinefelter syndrome: a Danish register study based on hospital discharge diagnoses. *J Clin Endocrinol Metab* 2006;91:1254–60.
- 3 Zöller B, Ji J, Sundquist J, *et al*. High risk of venous thromboembolism in Klinefelter syndrome. *J Am Heart Assoc* 2016;5:e003567.
- 4 Zitzmann M, Bongers R, Werler S, *et al*. Gene expression patterns in relation to the clinical phenotype in Klinefelter syndrome. *J Clin Endocrinol Metab* 2015;100:E518–23.
- 5 Glueck CJ, Jetty V, Goldenberg N, *et al*. Thrombophilia in Klinefelter syndrome with deep venous thrombosis, pulmonary embolism, and mesenteric artery thrombosis on testosterone therapy: a pilot study. *Clin Appl Thromb Hemost* 2017;23:973–9.
- 6 Meyer G, Vicaut E, Danays T, *et al*. Fibrinolysis for patients with intermediate-risk pulmonary embolism. *N Engl J Med Overseas Ed* 2014;370:1402–11.
- 7 Kline JA, Nordenholz KE, Courtney DM, *et al*. Treatment of submassive pulmonary embolism with tenecteplase or placebo: cardiopulmonary outcomes at 3 months: multicenter double-blind, placebo-controlled randomized trial. *J Thromb Haemost* 2014;12:459–68.
- 8 Konstantinides SV, Meyer G, Becattini C, *et al*. 2019 ESC guidelines for the diagnosis and management of acute pulmonary embolism developed in collaboration with the European respiratory Society (ERS). *Eur Respir J* 2019;54:1901647.
- 9 Loebinger MR, Bradley JC. Thrombolysis in pulmonary embolism: are we under-using it? *QJM* 2004;97:361–4.
- 10 D’Cruz R, Morton R, Jakes A. Respiratory failure as an indication for thrombolysis in pulmonary embolism? *Eur Respir J* 2016.
- 11 Ohlander SJ, Varghese B, Pastuszak AW. Erythrocytosis following testosterone therapy. *Sex Med Rev* 2018;6:77–85.
- 12 Houghton DE, Alsawas M, Barrionuevo P, *et al*. Testosterone therapy and venous thromboembolism: a systematic review and meta-analysis. *Thromb Res* 2018;172:94–103.

Copyright 2021 BMJ Publishing Group. All rights reserved. For permission to reuse any of this content visit <https://www.bmj.com/company/products-services/rights-and-licensing/permissions/>  
BMJ Case Report Fellows may re-use this article for personal use and teaching without any further permission.

Become a Fellow of BMJ Case Reports today and you can:

- ▶ Submit as many cases as you like
- ▶ Enjoy fast sympathetic peer review and rapid publication of accepted articles
- ▶ Access all the published articles
- ▶ Re-use any of the published material for personal use and teaching without further permission

#### Customer Service

If you have any further queries about your subscription, please contact our customer services team on +44 (0) 207111 1105 or via email at [support@bmj.com](mailto:support@bmj.com).

Visit [casereports.bmj.com](http://casereports.bmj.com) for more articles like this and to become a Fellow