




OPEN ACCESS

Self-inflicted transorbital injury by chopstick in patient with schizophrenia

Norihiro Shimizu ,^{1,2} Takayuki Baba,¹ Yoshihiro Watanabe,² Shuichi Yamamoto¹

¹Department of Ophthalmology and Visual Science, Chiba University Graduate School of Medicine, Chiba, Japan

²Department of Ophthalmology, Narita Red Cross Hospital, Narita, Japan

Correspondence to

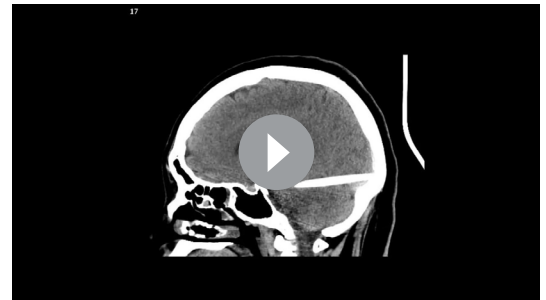
Dr Norihiro Shimizu; refrain_refrain@yahoo.co.jp

Accepted 30 October 2020

DESCRIPTION

A patient in her 40s with schizophrenia was brought to the emergency department after self-inflicted neck and wrists cuts. She was confined in a high care unit postoperatively. On the afternoon after the surgery, the nurses found that the light reflex in her left eye was absent and called us. Ophthalmological examinations revealed conjunctival haemorrhage and no direct and indirect light reflex in her left eye. We ordered a CT study, and the images showed an intracranial rod-shaped foreign body (figure 1, video 1). Later, the nurses reported that the tip of a 13 cm long chopstick had been missing after lunch, and they had been searching for it. As the patient said that she swallowed it, abdominal CT was studied, but it was not found. The 3D images and 3D CT angiography showed that the foreign body had penetrated into the brain through the optic canal and superior orbital fissure, and passed to the occipital bone. It was located on the left side of the pons (figure 2, video 1). The diameter and length of the object matched the tip of the chopstick. We assumed that she had tried to pierce her left eye with the chopstick, and it slid off the eye and passed through the orbital canal into the brain. Then, when she pulled it out violently, the tip broke off and was left in the brain.

After the incident, the patient had no remarkable changes physically and psychiatrically except for the loss of vision in her left eye due to the orbital apex syndrome. The neurosurgeons decided not to remove the tip because its location was in an area with a high risk for critical complications. The left eye lost all light perception, and the patient developed ptosis, total motility indicating a disruption of the oculomotor nerve, dilatation of the pupil and hypotropia. The optic



Video 1 CT and 3D-CT shows the foreign body clearly

disc became atrophic and the inner retina became thinner in a few months.

Early treatment of mental illness by a psychiatrist and closer surveillance might have reduced the risk of this ocular self-injury. A history of suicide attempts and deliberate self-harm, schizophrenia and suicidal thoughts have all been identified as risk factors for suicides by inpatients.¹ Additionally, the suicide attempts were found to be highest immediately after admission and also soon after discharge from the hospital.¹ In fact, the case of self-inflicted transorbital brain injury by chopsticks in a patient with psychosis in hospital had been reported in Asia.² As this case occurred under sedation, it might have been difficult to completely prevent it. A consultation with the psychiatrist and starting the treatment were

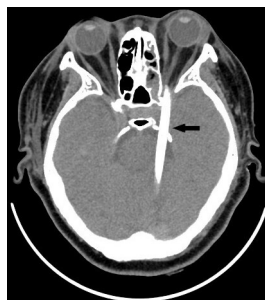

Figure 1 CT scan shows an intracranial rod-shaped foreign body. Intracerebral haemorrhage is not present (arrow).

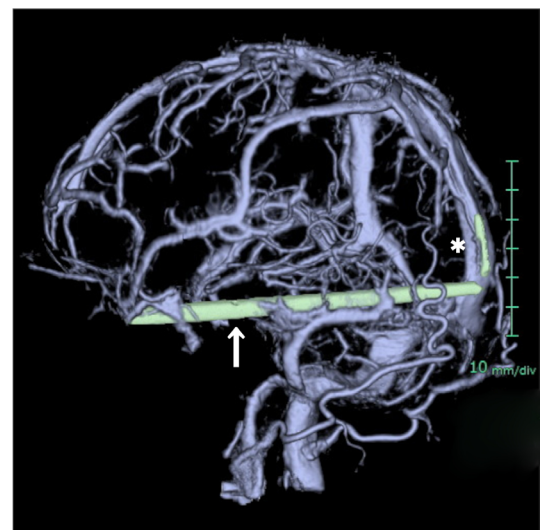
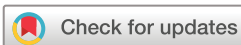

Figure 2 3D CT shows that the chopstick passed the internal carotid artery, ran along the posterior cerebral artery (arrow), and the tip was located on the left side of the pons (asterisk).



© BMJ Publishing Group Limited 2020. Re-use permitted under CC BY-NC. No commercial re-use. See rights and permissions. Published by BMJ.

To cite: Shimizu N, Baba T, Watanabe Y, et al. *BMJ Case Rep* 2020;**13**:e239721. doi:10.1136/bcr-2020-239721

Images in...

delayed because the accident occurred the day after the emergency surgery for her slashed neck and wrist.

The neurosurgeons decided not to remove the tip of the chopstick in this case. Although the incidence of central nervous system damage from transorbital penetrating objects is related to the orbital bone anatomy, and the size, shape and trajectory of the penetrating object, no fatal cases of injury by a chopstick have been reported.^{3 4} In some cases, a cerebral infection developed years after the injury but the outcome was favourable with antibiotics.⁴

Patient's perspective

When I was asked what I did at lunch, I told a lie that I have swallowed the chopstick.

Learning points

- ▶ An intracranial lesion needs to be eliminated when the light reflex is negative by CT scan.
- ▶ Early treatment by a psychiatrist and closer surveillance are necessary for patients with mental illness.
- ▶ In some cases of transorbital penetrating injury by chopstick, outcome is favourable with antibiotics even without removal.

Contributors NS and YW were involved clinical diagnosis and patient's care. NS, TB and SY drafted the manuscript, and all authors contributed substantially to its revision. NS takes responsibility for the paper as a whole.

Funding The authors have not declared a specific grant for this research from any funding agency in the public, commercial or not-for-profit sectors.

Competing interests TB: personal fees from Bayer, personal fees from Kowa, personal fees from Santen, personal fees from Senju, personal fees from Alcon, grants and personal fees from Novartis, outside the submitted work. SY: grants and personal fees from HOYA, grants and personal fees from Senju, grants and personal fees from Pfizer, grants and personal fees from Santen, grants and personal fees from Alcon Japan, grants and personal fees from Alcon Pharma, grants and personal fees from Bayer, grants and personal fees from Kowa, personal fees from Nikon, personal fees from Wakamoto, personal fees from Chuo Sangyo, personal fees from Daiichi Sankyo, personal fees from Jamex, personal fees from Sun Contact Lens, personal fees from Finedex, personal fees from Novartis, personal fees from Chugai, personal fees from AbbVie, outside the submitted work. The following authors have no financial disclosures: NS and YW.

Patient consent for publication Obtained.

Provenance and peer review Not commissioned; externally peer-reviewed.

Open access This is an open access article distributed in accordance with the Creative Commons Attribution Non Commercial (CC BY-NC 4.0) license, which permits others to distribute, remix, adapt, build upon this work non-commercially, and license their derivative works on different terms, provided the original work is properly cited and the use is non-commercial. See: <http://creativecommons.org/licenses/by-nc/4.0/>.

ORCID iD

Norihiro Shimizu <http://orcid.org/0000-0001-7169-4706>

REFERENCES

- 1 Turbin RE, Maxwell DN, Langer PD, *et al*. Patterns of transorbital intracranial injury: a review and comparison of occult and non-occult cases. *Surv Ophthalmol* 2006;51:449–60.
- 2 Lee YC, Kwan HH, Wong T, *et al*. Self-Inflicted transorbital brain injury by chopsticks in a patient with acute psychosis. *Hong Kong Med J* 2017;23:313–4.
- 3 Navin K, Kuppili PP, Menon V, *et al*. Suicide prevention strategies for General Hospital and psychiatric inpatients: a narrative review. *Indian J Psychol Med* 2019;41:403–12.
- 4 Yamasaki F, Ohge H, Tsumura R, *et al*. [Transorbital penetrating intracranial injury by a chopstick: a case report and review of the literature]. *No Shinkei Geka* 2013;41:1001–9.

Copyright 2020 BMJ Publishing Group. All rights reserved. For permission to reuse any of this content visit <https://www.bmj.com/company/products-services/rights-and-licensing/permissions/>
BMJ Case Report Fellows may re-use this article for personal use and teaching without any further permission.

Become a Fellow of BMJ Case Reports today and you can:

- ▶ Submit as many cases as you like
- ▶ Enjoy fast sympathetic peer review and rapid publication of accepted articles
- ▶ Access all the published articles
- ▶ Re-use any of the published material for personal use and teaching without further permission

Customer Service

If you have any further queries about your subscription, please contact our customer services team on +44 (0) 207111 1105 or via email at support@bmj.com.

Visit casereports.bmj.com for more articles like this and to become a Fellow