



OPEN ACCESS

Case report

Sinonasal relapses of a primary isolated extranodal NK/T-cell lymphoma of the testis

Bassel Hallak,¹ Anne Cairoli,² Salim Bouayed,¹ Grégoire Berthod³

¹Department of Otorhinolaryngology, Hospital of Sion, Sion, Switzerland
²Hematology, Centre Hospitalier Universitaire Vaudois, Lausanne, Switzerland
³Oncology, Hospital of Sion, Sion, Switzerland

Correspondence to
Dr Bassel Hallak,
bassel2004@hotmail.com

Accepted 26 June 2019

SUMMARY

WHO first recognised extranodal NK/T-cell lymphoma (ENKTCL) in 2001, thanks to technical advances in anatomopathology and immunohistochemistry. It is divided into nasal and extranasal subgroups depending on the primary site. Primary isolated NK/T-cell lymphoma of the testis is rare. Typical recurrence sites of primary testicular NK/T-cell lymphoma are the gastrointestinal tract, lymph nodes, skin, spleen and central nervous system. Nasal relapses of a primary NK/T-cell lymphoma of the testis are very rare and according to our knowledge, no other case has been reported yet in the literature. The authors report the case of a 35-year-old Caucasian man relapsing twice in the nasal cavity 1 year after initial diagnosis and treatment of a primary isolated, stage IE, ENKTCL of the testis. We report the clinical and radiological presentation of the nasal relapses and the different modalities of treatment that were applied. Sinonasal relapses of an isolated primary NK/T-cell lymphoma of the testis are very rare. ENKTCL is a very aggressive entity, even at an early stage, therefore, requiring a multimodal treatment approach including chemotherapy and radiotherapy. New strategies to treat this disease are needed.

BACKGROUND

Natural Killer (NK)/T-cell lymphoma represents less than 5% of all lymphomas. It comes from NK cells, cytolytic lymphocytes of the innate immune system, responsible for immune responses to bacterial and viral infections. It is almost always (>95%) associated with the Epstein-Barr virus (EBV),¹ which plays an important role in the lymphomagenesis. Recently, Barrionuevo *et al*² and Kuo *et al*³ detected EBV-encoded small nuclear RNA (EBER-1) by *in situ* hybridisation in all the examined extranodal NK/T-cell lymphomas (ENKTCL).

NK/T-cell lymphoma arises more frequently in Asian countries and central/South America, but is a rare entity in North America and Europe, with an incidence of less than 1/1 000 000.⁴

NK/T-cell lymphoma typically presents with involvement of the nasal cavity, nasopharynx, oropharynx and paranasal sinus as primary sites in more than 80% of the cases, referred to as 'nasal-type'. Even if most of the patients have the diagnosis at stage I/II, there is a high relapse rate after radiochemotherapy of more than 30%.⁵

Extranasal sites include the gastrointestinal tract, skin, lung, liver, bone and testis. These two subgroups share similar histological and

immunophenotypic features, expressing CD2, cytoplasmic CD3 epsilon, CD56 and TIA-1. Prognosis is worse in case of extranasal presentation and poor in relapsing and advanced stage patients.

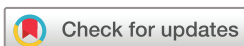Primary testicular lymphoma (PTL) is defined as the testis being the only involved site at presentation, without other nodal or organ involvement.⁶ Diffuse large B-cell lymphoma (DLBCL) constitutes more than 70% of testicular lymphomas. Compared with DLBCL, testicular ENKTCL is a rare entity whether primary or secondary.⁷

We report here a clinical case of a young patient presenting with multiple sinonasal relapses of an NK/T-cell lymphoma of the testis. Clinical, radiological presentation and the different modalities of treatment are presented.

CASE PRESENTATION

A 35-year-old Caucasian man was investigated for a right testicular mass (measuring 5, 8×5, 3×4, 5 cm) in October 2015. Classical tumour markers for testicular cancer (LDH, AFP and HCG) were negative. An orchiectomy was performed, and the diagnosis of ENKTCL was established. The immunohistochemistry showed a classical positivity for CD56, CD3, TIA-1 and EBER; CD5, CD7, CD8 and TdT were negative and the proliferation index was high with Mib-1 at 70%–80%. An initial radiological evaluation with PET-CT and bone marrow biopsy were performed that revealed a stage IE according to the Ann Arbor classification without any other nodal or extranodal localisation. Blood EBV PCR was low at 130 cop/mL (the normal detection threshold is less than 100 cop/mL). Fibroendoscopic examination of the nasal cavity was normal without any suspect lesions.

The patient was treated by radiation therapy with a total dose of 40 Gy in addition to concomitant chemotherapy (weekly cisplatin 30 mg/m²). This was followed by three cycles of chemotherapy according to the protocol SMILE (ddexamethasone, methotrexate, ifosfamide, l-asparaginase and etoposide). Radiological examination by a PET-CT 3 months post-treatment showed a complete remission of the disease. EBV PCR was still positive with 389 cop/mL. The patient presented with left-sided nasal obstruction 7 months post-treatment without any other rhinological symptoms. The fibroendoscopic examination of the nasal cavity showed a swelling of the mucosa at the level of the nasal cavity floor and lateral wall on both sides, predominating on the left side (figure 1A), with no evidence of any exophytic lesion. The CT, MRI and PET-CT



© BMJ Publishing Group Limited 2019. Re-use permitted under CC BY-NC. No commercial re-use. See rights and permissions. Published by BMJ.

To cite: Hallak B, Cairoli A, Bouayed S, *et al*. *BMJ Case Rep* 2019;**12**:e230221. doi:10.1136/bcr-2019-230221

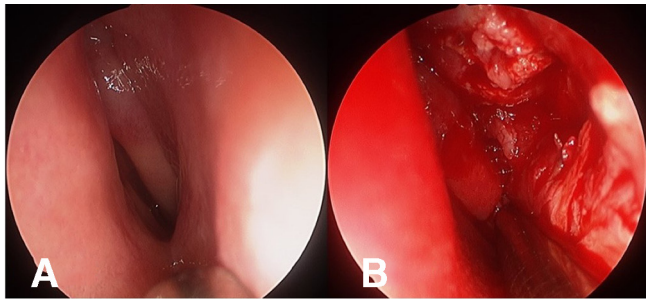


Figure 1 (A) Endoscopic view shows a swelling of the mucosa of the nasal cavity on the left side without any exophytic lesion. (B) Deep submucosal biopsy of the nasal cavity on the left side shows an important infiltration of tumorous tissues.

imaging (figure 2A,B) showed hypermetabolic activity of the nasal cavity on both side highly suggestive for recurrence; there was no evidence for testicular relapse and no other suspect nodal or extranodal lesion. Deep submucosal biopsies of the nasal cavity (figure 1B) confirmed the diagnosis of relapsing NK/T-cell lymphoma in the nasal cavity. The histological and immunohistochemistry results were similar to the primary disease of the right testis. The patient was treated by chemotherapy with three cycles according to the protocol GIDOX, (gemcitabine, ifosfamide, dexamethasone and oxaliplatin) followed by an intensification chemotherapy regimens according to the BEAM protocol (BCNU, etoposide, cytarabine and melphalan) and autologous stem-cell transplant. Radiological evaluation by PET-CT performed at the end of the treatment, showed complete response to the treatment without any residual metabolic activity

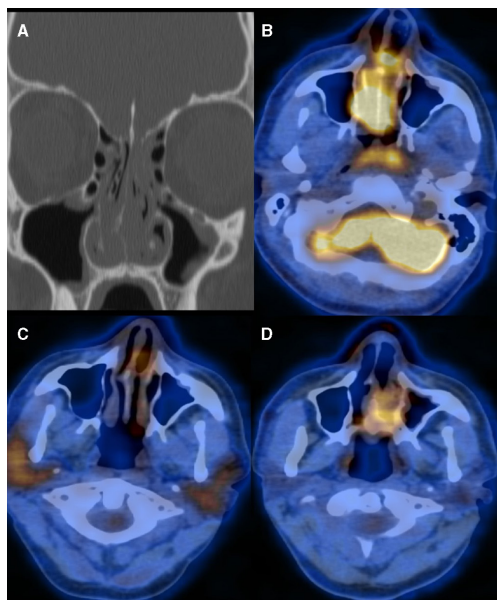


Figure 2 (A) CT showed complete opacity of the nasal cavity on both sides without any bony erosion. (B) PET-scan showed hypermetabolic activity on both sides of the nasal cavity (SUV 8, 9), suspicious of relapsing testicular lymphoma. (C) PET-scan after the treatment of the first nasal relapse showed complete remission without any residual suspicious hypermetabolic activity. (D) PET-scan performed 4 months after the end of the treatment of the nasal relapse showed hypermetabolic activity (SUV 6, 5) in the nasal cavity on the left side, highly suspicious of a second nasal relapse of the NK/T-cell lymphoma. NK, natural killer.

or appearance of other suspect lesion (figure 2C). The endoscopic examination of the nasal cavity revealed a normal appearance of the mucosa.

Four months later, a routine clinical examination reveals a second relapse in the nasal cavity with the same swelling of the mucosa, confirmed by a new biopsy. The PET-CT showed only a small slightly hypermetabolic cervical node (negative for lymphoma on biopsy) (figure 2D). Local radiotherapy (40 Gy) of the nasal cavity and the cervical area was performed, followed by an allograft. The patient is currently still in remission, 2 years after the diagnosis of the first nasal relapse of the NK/T-cell lymphoma of the testis.

OUTCOME AND FOLLOW-UP

Seven months after the treatment of a stage IE NK/T-cell lymphoma of the right testis, the patient presented a nasal relapse on the left side without a local recurrence or any other organ involvement. This relapse was treated with salvage chemotherapy and an autologous stem-cell transplantation.

Radiological and clinical evaluation at the end of the treatment of the nasal relapse showed a complete remission without any suspicious hypermetabolic activity on the PET-CT.

A routine follow-up 4 months after this remission showed a second nasal relapse on the left side with suspicion of involvement of the cervical lymph node on both sides (slightly hypermetabolic but negative for lymphoma at the biopsy) and without evidence of recurrence at the level of the testis or any other organ involvement. This new relapse was treated with locoregional radiotherapy

At 2 years after the diagnosis of the first nasal relapse of the NK/T-cell lymphoma, the patient is still in remission.

DISCUSSION

We report the case of a primary extranasal ENKTCL of the testis in a young Caucasian man with twice nasal involvement as the unique site of relapse. Due to the relapse pattern, we decide to describe this case.

Few cases of primary testicular NK/T-cell lymphoma are reported in the literature. The largest series has been described recently by Huang *et al*⁸ who collected 21 new cases in three hospitals in China. PTL represents 0.72% of all ENKTCL, during the study period. Most of the cases were Asian. Median age was 45 years. Seventy-three per cent were diagnosed at stage I/II. The 2-year overall survival of patients with de novo testicular NK/T-cell lymphoma was 34%, and the median survival was 15.3 months, putting forward the aggressiveness of this disease and the poor outcome. Even with stages I–II, the 2-year overall survival was 43%. In this review, sites of extratesticular involvement and relapse were lymph nodes, skin, contralateral testis, bone marrow, spleen, adrenal glands and the central nervous system. No nasal cavity was described as a site of relapse in those 21 cases.

Liang *et al*⁹ reported earlier a series of 31 cases of testicular NK/T-cell lymphoma with 15 cases of primary and 16 cases of non-PTL. In the primary testicular cases, the secondary dissemination sites were the contralateral testis, lymph nodes, skin, spleen, central nervous system and liver; the nasopharynx was described as a unique site of relapse in only one case. In the 16 non-primary cases, 5 were secondary to nasal-type NK/T-cell lymphoma and 11 had initially multiple organ involvement, 2 of which having nasal cavity involvement.

The exact role of autologous stem-cell transplantation remains undefined in relapsing disease, however, it seems that our patient

was in complete remission after salvage therapy. We, therefore, decided to add the stem-cell transplantation in order to offer him the maximum chance of durable response.

The prognosis of primary NK/T-cell lymphoma of the testis remains very poor and, even more so, in the nasal type. In a series of 101 patients of ENKTCL in Taiwan, published by Su *et al*,⁵ 5 years overall survival was 55% and 72% in patients with stages I–II. EBV DNA is a surrogate biomarker of the lymphoma load and should be followed during the course of the disease.¹⁰

The two relapses in the nasal cavity in our patient raise questions as to the advanced stage of a primary nasal ENKTCL with infraclinical involvement of the nasal cavity, since deep biopsies were not undertaken initially. However, this case and those described in the series mentioned above showed the need to treat these patients very aggressively, similarly to advanced stages, with polychemotherapy-containing l-asparaginase, very active in this disease and high doses of methotrexate due to the high risk of brain relapse.¹¹ New treatment and new multimodal strategies of treatment should be investigated.

Learning points

- ▶ Nasal relapse of a primary isolated natural killer (NK)/T-cell lymphoma of the testis is described for the first time, along with its presentation and applied treatment.
- ▶ Extranodal NK/T-cell lymphoma is a very rare clinical entity in Western countries and is always associated with the Epstein-Barr virus.
- ▶ Despite multimodal therapies, the prognosis is poor with very low survival rates.

Contributors BH, corresponding author, reporting. AC, coauthor, acquisition of date. SB, coauthor, design. GB, coauthor, reporting.

Funding The authors have not declared a specific grant for this research from any funding agency in the public, commercial or not-for-profit sectors.

Competing interests None declared.

Patient consent for publication Obtained.

Provenance and peer review Not commissioned; externally peer reviewed.

Open access This is an open access article distributed in accordance with the Creative Commons Attribution Non Commercial (CC BY-NC 4.0) license, which permits others to distribute, remix, adapt, build upon this work non-commercially, and license their derivative works on different terms, provided the original work is properly cited and the use is non-commercial. See: <http://creativecommons.org/licenses/by-nc/4.0/>

REFERENCES

- 1 Pine RR, Clark JD, Sokol JA. CD56 negative extranodal NK/T-cell lymphoma of the orbit mimicking orbital cellulitis. *Orbit* 2013;32:45–8.
- 2 Barrionuevo C, Zaharia M, Martinez MT, *et al*. Extranodal NK/T-cell lymphoma, nasal type: study of clinicopathologic and prognosis factors in a series of 78 cases from Peru. *Appl Immunohistochem Mol Morphol* 2007;15:38–44.
- 3 Kuo TT, Shih LY, Tsang NM. Nasal NK/T cell lymphoma in Taiwan: a clinicopathologic study of 22 cases, with analysis of histologic subtypes, Epstein-Barr virus LMP-1 gene association, and treatment modalities. *Int J Surg Pathol* 2004;12:375–87.
- 4 Kommalapati A, Tella SH, Ganti AK, *et al*. Natural Killer/T-cell Neoplasms: analysis of incidence, patient characteristics, and survival outcomes in the United States. *Clin Lymphoma Myeloma Leuk* 2018;18:475–9.
- 5 Su YJ, Wang PN, Chang H, *et al*. Extranodal NK/T-cell lymphoma, nasal type: clinical features, outcome, and prognostic factors in 101 cases. *Eur J Haematol* 2018;101:379–88.
- 6 Kiely JM, Massey BD, Harrison EG, *et al*. Lymphoma of the testis. *Cancer* 1970;26:847–52.
- 7 Sun T, Brody J, Susin M, *et al*. Aggressive natural killer cell lymphoma/leukemia. A recently recognized clinicopathologic entity. *Am J Surg Pathol* 1993;17:1289–99.
- 8 Huang Y, Shi X, Zhong P, *et al*. De Novo Testicular Extranodal NK/T-Cell Lymphoma: a clinicopathologic study of 21 cases with review of additional 18 cases in the literature. *Am J Surg Pathol* 2019;43:549.
- 9 Liang DN, Yang ZR, Wang WY, *et al*. Extranodal nasal type natural killer/T-cell lymphoma of testis: report of seven cases with review of literature. *Leuk Lymphoma* 2012;53:1117–23.
- 10 Au WY, Pang A, Choy C, *et al*. Quantification of circulating Epstein-Barr virus (EBV) DNA in the diagnosis and monitoring of natural killer cell and EBV-positive lymphomas in immunocompetent patients. *Blood* 2004;104.
- 11 Kim SJ, Oh SY, Hong JY, *et al*. When do we need central nervous system prophylaxis in patients with extranodal NK/T-cell lymphoma, nasal type? *Ann Oncol* 2010;21:2833.

Copyright 2019 BMJ Publishing Group. All rights reserved. For permission to reuse any of this content visit <https://www.bmj.com/company/products-services/rights-and-licensing/permissions/>
BMJ Case Report Fellows may re-use this article for personal use and teaching without any further permission.

Become a Fellow of BMJ Case Reports today and you can:

- ▶ Submit as many cases as you like
- ▶ Enjoy fast sympathetic peer review and rapid publication of accepted articles
- ▶ Access all the published articles
- ▶ Re-use any of the published material for personal use and teaching without further permission

Customer Service

If you have any further queries about your subscription, please contact our customer services team on +44 (0) 207111 1105 or via email at support@bmj.com.

Visit casereports.bmj.com for more articles like this and to become a Fellow