Isolated glanular gangrene; a rare sequel of priapism

Saqib Mehdi, Deepanshu Sharma, Siddharth Pandey, Satyanarayan Sankhwar

Department of Urology, King George's Medical University, Lucknow, India

Correspondence to
Dr Saqib Mehdi,
mehdisaqib79@gmail.com

Accepted 15 March 2019

DESCRIPTION

A 52-year-old man had presented to a medical facility with painful and sustained erection of penis for last 48 hours. The patient was managed with creation of a T shunt to achieve penile detumescence. A urethral catheter was placed and a circular compressive dressing was applied around the penis. The next day after surgery, the patient developed blackish discolouration of the glans penis. The patient arrived at our hospital 4 days after onset of his priapism. On examination, he was found to have a black glans penis, with a flaccid penile shaft and a Foley catheter in situ. The reasons for not removing the urethral catheter of the patient and performing a suprapubic cystotomy were not mentioned in his discharge summary. We removed his urethral catheter and performed a suprapubic cytotomy, but still the black colour of glans penis deepened over the next day and a clear line of demarcation became visible between it and the penile shaft (figure 1). Haematological investigations of the patient were unremarkable and did not reveal any underlying coagulation disorder or malignancy. The sonological examination of the urinary bladder was also unremarkable, and urine culture was sterile. The patient underwent glansectomy under spinal anaesthesia, and a Foley catheter was left in situ which was removed 7 days after surgery. The postoperative recovery of the patient was uneventful, and he was discharged 48 hours after surgery. On 3 weeks of follow-up, the patient was voiding well and had a healthy wound.

Priapism is an infrequently encountered disease with most cases being idiopathic in origin. The treatment involves resuscitation of the patient and decompression of the cavernosal bodies to achieve penile detumescence. This is aimed to prevent ischaemic complications of priapism like penile gangrene.[1 2] Various factors like urethral catheter, tight pressure bandage dressing around the penis and local infection alone or in combination have been implicated in causing penile gangrene in cases of priapism.[3] In our case too, the patient was catheterised and a compressive dressing was applied around his penis.

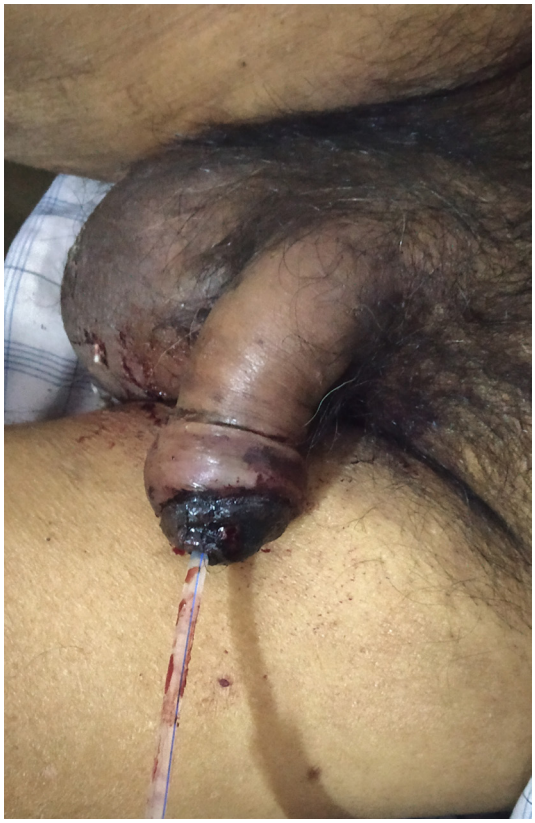

Figure 1 Clinical photograph showing blackened glans penis with flaccid penile shaft and a urethral catheter in situ.

Learning points

- Priapism although being an uncommon condition can give rise to morbid complications like penile gangrene.
- Tight compressive dressings and urethral catheterisation should be avoided in cases of priapism.
- Penile detumescence in cases of priapism should be achieved on an emergent basis to prevent its ischaemic complications.

Contributors SM conceived the case report. SM and DS were major contributors towards writing the manuscript. SNS, SP and SM treated the patient and also interpreted the patient data. DS and SP were involved in the review. All authors read and approved the final manuscript.

Funding The authors have not declared a specific grant for this research from any funding agency in the public, commercial or not-for-profit sectors.

Competing interests None declared.

Patient consent for publication Obtained.

Provenance and peer review Not commissioned; externally peer reviewed.

REFERENCES

1 Harris CF, Mydlo JH. Ischemia and Gangrene of the Penis. *J Urol* 2003;169:1795.
2 Badmus TA, Adediran IA, Adesunkanmi AR, *et al*. Priapism in southwestern Nigeria. *East Afr Med J* 2003;80:518–24.
3 Khoriaty N, Schick E. Penile gangrene: an unusual complication of priapism. How to avoid it? *Urology* 1980;16:280–3.

To cite: Mehdi S, Sharma D, Pandey S, *et al*. *BMJ Case Rep* 2019;**12**:e229432. doi:10.1136/bcr-2019-229432