

Abdominal varicocele: a new entity

Brijendra Singh,¹ Shahana Gupta²

¹Department of Surgical Gastroenterology, Regency Hospital, Kanpur, Uttar Pradesh, India

²Department of Surgery, Medical College, Kolkata, West Bengal, India

Correspondence to

Dr Shahana Gupta;
shahanagupta@yahoo.co.in

DESCRIPTION

A 26-year-old male patient presented with a history of occasional vague lower abdominal pain since childhood. He was diagnosed with a case of functional bowel disorder. There was no history of haematuria or any loin pain. Abdominal examination revealed an ill-defined 15×12 cm lump in left part of abdomen. Ultrasonography (USG) of abdomen showed a cystic collection in lower abdomen extending up to pelvis. Contrast-enhanced CT abdomen (figure 1; lower inset) suggested a diagnosis of mesenteric cyst. On exploration, a cystic, lobulated, vascular lesion ~15×15 cm in size (figure 1; upper inset), containing blood, fed by the left testicular artery and draining into left testicular vein, was found (figure 1; arrow). We call this entity abdominal varicocele. There was no evidence of any compression of the left renal vein between superior mesenteric artery and the aorta, thereby ruling out nutcracker phenomenon as a cause.^{1 2} A review of the CT scan also did not show any evidence of nutcracker phenomenon. Excision of the mass was performed after ligating its vascular pedicle. The right testicular vein showed tortuosity and was ligated. Histopathology suggested a lesion of vascular origin. Both the testes were normal on palpation and on USG. There was no evidence of any varicocele in the

left inguinal region or scrotum, clinically or on USG. The patient has normal fertility and is doing well during follow-up. There is no report in the literature on varicocele arising from intra-abdominal testicular vasculature.³ The aetiology of this condition is speculative, probably a result of abnormality in testicular vasculature.

Learning points

- ▶ Varicocele involving intra-abdominal testicular vasculature is possible.
- ▶ This diagnosis should be kept in mind when evaluating cystic abdominal masses.
- ▶ Nutcracker phenomenon must be looked for, as a cause of varicocele, on imaging as well as intraoperatively.

Acknowledgements The authors would like to acknowledge Maria Kutty Thomas and Shazia.

Competing interests None.

Patient consent Obtained.

Provenance and peer review Not commissioned; externally peer reviewed.

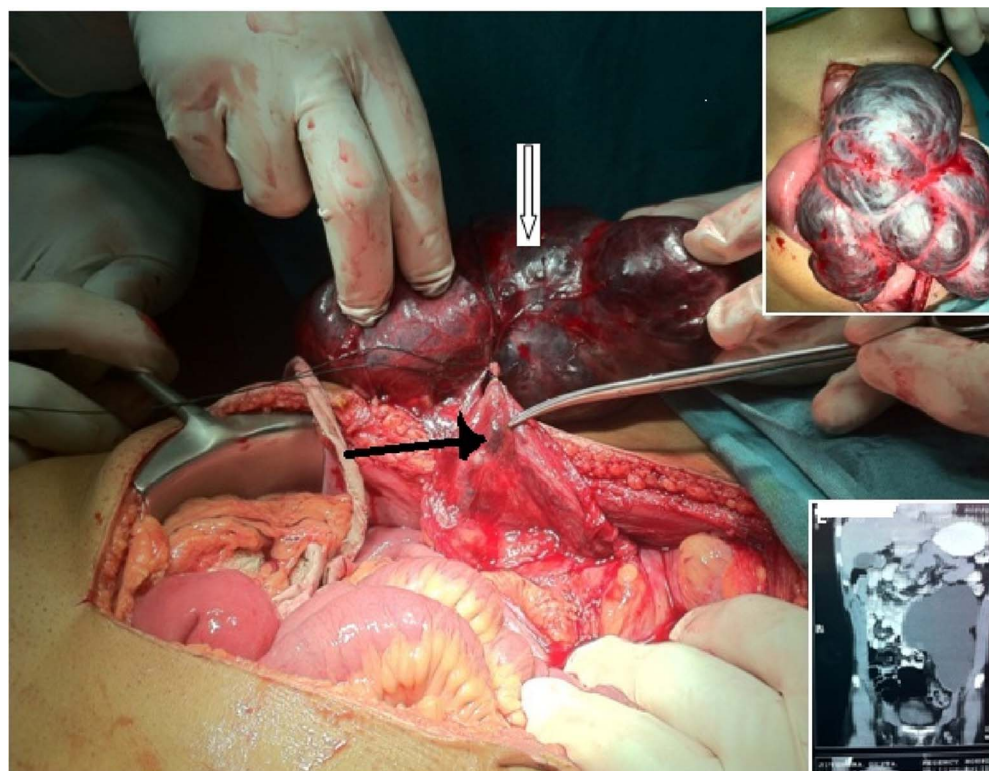


Figure 1 Abdominal varicocele: operative picture. Lower inset: CT scan of the abdomen showing a cystic mass. Upper inset: the vascular mass. Arrow: testicular vessels (L).



To cite: Singh B, Gupta S. *BMJ Case Rep* Published online: [please include Day Month Year] doi:10.1136/bcr-2013-201256

REFERENCES

- 1 Kurklinsky AK, Rooke T. Nutcracker phenomenon and nutcracker syndrome review. *Mayo Clin Proc* 2010;85:552–9.
- 2 Venkatachalam S, Bumpus K, Kapadia SR, *et al*. Basic data underlying clinical decision-making in endovascular therapy the nutcracker syndrome. *Ann Vasc Surg* 2011;25:1154–64.
- 3 Coburn M. Urologic surgery. In: Townsend Jr CM, Beauchamp RD, Evers BM, Mattox KL, eds. *Sabiston textbook of surgery: The biological basis of modern surgical practice, 19th edn*. Philadelphia: Saunders, 2012:2046–78.

Copyright 2013 BMJ Publishing Group. All rights reserved. For permission to reuse any of this content visit <http://group.bmj.com/group/rights-licensing/permissions>.
BMJ Case Report Fellows may re-use this article for personal use and teaching without any further permission.

Become a Fellow of BMJ Case Reports today and you can:

- ▶ Submit as many cases as you like
- ▶ Enjoy fast sympathetic peer review and rapid publication of accepted articles
- ▶ Access all the published articles
- ▶ Re-use any of the published material for personal use and teaching without further permission

For information on Institutional Fellowships contact consortiasales@bmjgroup.com

Visit casereports.bmj.com for more articles like this and to become a Fellow