

Cerebral venous sinus thrombosis with parieto-temporal infarct in a young woman

Rayna Patel,¹ Koshy Thomas,² Sami Khan³

¹Department of Anaesthetics, Basildon Hospital, Basildon, Essex, UK

²Basildon Hospital, Basildon, Essex, UK

³Department of Radiology, Basildon Hospital, Basildon, Essex, UK

Correspondence to

Dr Rayna Patel,
raynapatel@hotmail.com

DESCRIPTION

A 34-year-old woman presented with confusion and dysphasia, preceded by 5 days of vomiting. Her only medical history was chronic iron-deficiency anaemia secondary to menorrhagia, for which she was taking oral iron supplements. Three weeks earlier, she had started taking rigevidon, an oral contraceptive pill, for menorrhagia. Neurological examination revealed only a severe receptive dysphasia.

CT of the head demonstrated a large thrombus within the confluence of sinuses, extending into the left transverse and sigmoid sinuses. This was associated with a large haemorrhagic venous infarct involving the left parieto-temporal lobe (figure 1). MRI demonstrated extension of the thrombus into the inferior sagittal and straight sinuses (figure 2).

Treatment-dose, low-molecular-weight heparin was started in hospital and the patient fully recovered.

Cerebral venous sinus thrombosis (CVST) is a rare but important clinical entity in adults, accounting for 0.5% of stroke presentations.¹ The non-specific presentation of CVST presents difficulties in its diagnosis, which is often established only with imaging and after a median delay of 7 days.²

This has significant consequences in terms of both morbidity and mortality. CVST has previously been associated with poor outcomes and mortality of 30–50%.² The lower mortality observed in recent studies, such as the International Study on Cerebral Vein and Dural Sinus Thrombosis (8–14%

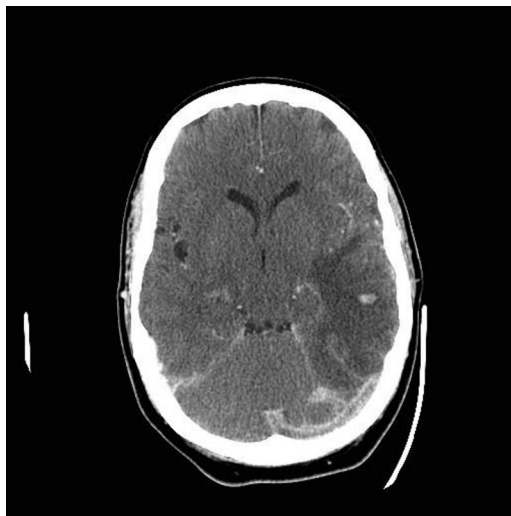

Figure 1 Contrast-enhanced CT of the head showed a large thrombus within the confluence of sinuses, extending into the left transverse and sigmoid sinuses, and a large left-sided venous infarct with haemorrhagic foci involving the left temporal and parietal lobes.

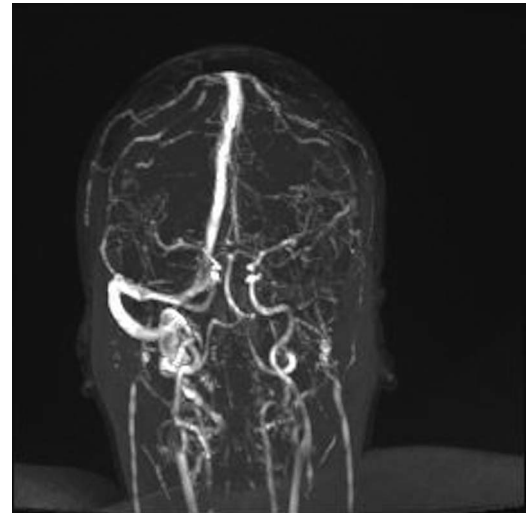


Figure 2 MR venogram showed a thrombus involving the confluence of the sinuses, left-sided transverse and sigmoid sinuses, the distal portion of the inferior sagittal sinus, and the straight sinus.

mortality),² demonstrates the substantial beneficial effect of appropriate imaging and subsequent early diagnosis in such patients.

Learning Points:

- ▶ Cerebral venous sinus thrombosis (CVST) should be considered as a rare cause of stroke in young female patients.
- ▶ CVST can often be identified early on in appropriate imaging.
- ▶ Early anticoagulation of patients with CVST significantly improves outcome.

Contributors RP researched and wrote the manuscript. KT edited the manuscript. SK provided the figures and legends. All authors read and approved the final manuscript.

Competing interests None.

Patient consent Obtained.

Provenance and peer review Not commissioned; externally peer reviewed.

REFERENCES

- 1 Filippidis A, Kapsalaki E. Cerebral venous sinus thrombosis: review of the demographics, pathophysiology, current diagnosis, and treatment. *Neurosurg Focus* 2009;27:E3.
- 2 Ferro JM, Canhão P, Stam J, et al. ISCVT Investigators. Prognosis of cerebral vein and dural sinus thrombosis: results of the International Study on Cerebral Vein and Dural Sinus Thrombosis (ISCVT). *Stroke* 2004;35:664–70.

To cite: Patel R, Thomas K, Khan S. *BMJ Case Rep* Published online: [please include Day Month Year] doi:10.1136/bcr-2013-010046

Copyright 2013 BMJ Publishing Group. All rights reserved. For permission to reuse any of this content visit <http://group.bmj.com/group/rights-licensing/permissions>.
BMJ Case Report Fellows may re-use this article for personal use and teaching without any further permission.

Become a Fellow of BMJ Case Reports today and you can:

- ▶ Submit as many cases as you like
- ▶ Enjoy fast sympathetic peer review and rapid publication of accepted articles
- ▶ Access all the published articles
- ▶ Re-use any of the published material for personal use and teaching without further permission

For information on Institutional Fellowships contact consortiasales@bmjgroup.com

Visit casereports.bmj.com for more articles like this and to become a Fellow