

## Images in...

# A misguided 'pill in the pocket' approach with flecainide leading to cardiac arrest

Daniel Kiblboeck,<sup>1</sup> Michael Braeuer-Mocker,<sup>2</sup> Peter Siostrzonek,<sup>1</sup> Johann Reisinger<sup>1</sup>

<sup>1</sup>Department of Cardiology, Hospital of the Sisters of Charity Linz (Krankenhaus Barmherzige Schwestern), Linz, Austria

<sup>2</sup>Department of Anaesthesiology, Hospital of the Sisters of Charity Linz (Krankenhaus Barmherzige Schwestern), Linz, Austria

Correspondence to Dr Daniel Kiblboeck, daniel.kiblboeck@bhs.at

## DESCRIPTION

A 67-year-old woman was initially complaining of breathlessness and had a single syncope before she went into cardiac arrest. First monitored rhythm was a slow pulseless electrical activity. Return of spontaneous circulation was achieved by cardiopulmonary resuscitation within 20 min. The ECG on admission to the intensive care unit showed an irregular rhythm due to intermittent high-degree atrioventricular block with very broad QRS complexes (figure 1). The patient was treated with oricprenaline and a temporary pacemaker. Coronary angiography did not show any coronary stenosis.

After a detailed medical history with her husband we found out that flecainide was prescribed as a 'pill in the pocket' therapy for atrial fibrillation despite a pre-existing right bundle branch block with left-anterior hemiblock. Additionally, due to a misunderstanding between the patient and her treating physician, she took flecainide 100 mg twice daily on a regular basis.

Furthermore, there was a history of chronic kidney disease (serum creatinine 1.8 mg/dl) leading to a trough plasma flecainide level of 0.8 mg/l measured in hospital 12 h after the last ingestion. This borderline high plasma

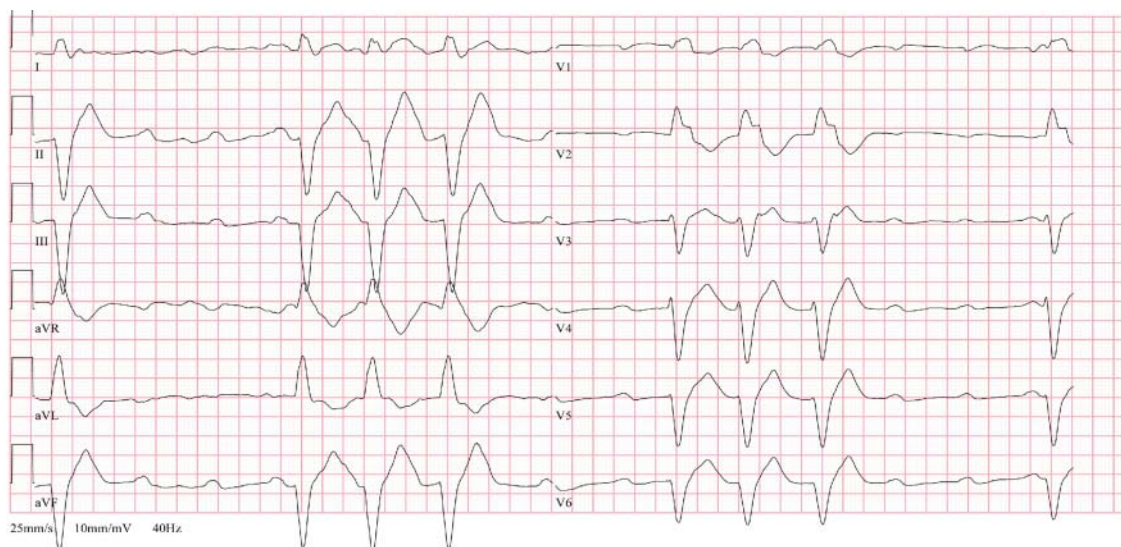
flecainide level was obviously sufficient to provoke a life-threatening situation in the setting of a pre-existing conduction disturbance.

The patient was treated with therapeutic hypothermia and remained pacemaker dependent for 24 h. During the next days, the QRS complex became narrower while still showing the pre-existing bifascicular block (figure 2). We discharged the patient from the intensive care unit in a good neurological condition after 9 days.

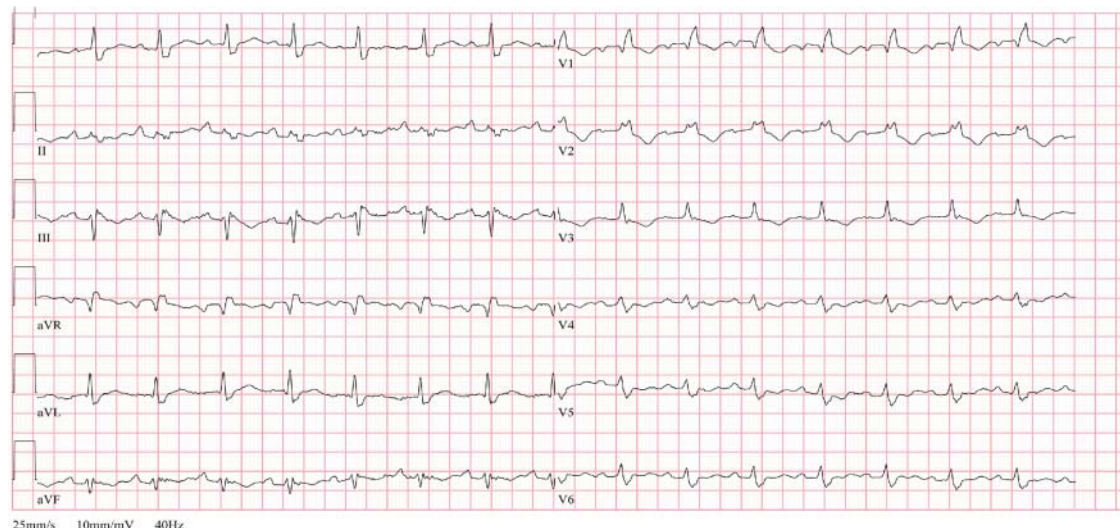
## Learning points

- ▶ Avoid flecainide in patients with pre-existing conduction disturbances.
- ▶ Be aware that the rate of flecainide elimination is slower in patients with chronic kidney disease.<sup>1</sup>
- ▶ Make sure that the patient understands correctly what is meant by a 'pill in the pocket' therapy.

Competing interests None.



**Figure 1** ECG on admission showing an irregular rhythm due to intermittent high-degree atrioventricular block with very broad QRS complexes.



**Figure 2** ECG after 5 days showing the pre-existing bifascicular block.

**Patient consent** Obtained.

## REFERENCE

1. **Conard GJ**, Ober GE. Metabolism of flecainide. *Am J Cardiol* 1984;**53**:41B–51B.

This pdf has been created automatically from the final edited text and images.

Copyright 2012 BMJ Publishing Group. All rights reserved. For permission to reuse any of this content visit

<http://group.bmj.com/group/rights-licensing/permissions>.

BMJ Case Report Fellows may re-use this article for personal use and teaching without any further permission.

Please cite this article as follows (you will need to access the article online to obtain the date of publication).

Kiblböck D, Brauer-Möcker M, Siostrzonek P, Reisinger J. A misguided 'pill in the pocket' approach with flecainide leading to cardiac arrest. *BMJ Case Reports* 2012;10.1136/bcr-2012-006868, Published XXX

Become a Fellow of BMJ Case Reports today and you can:

- ▶ Submit as many cases as you like
- ▶ Enjoy fast sympathetic peer review and rapid publication of accepted articles
- ▶ Access all the published articles
- ▶ Re-use any of the published material for personal use and teaching without further permission

For information on Institutional Fellowships contact [consortiasales@bmjgroup.com](mailto:consortiasales@bmjgroup.com)

Visit [casereports.bmj.com](http://casereports.bmj.com) for more articles like this and to become a Fellow