



OPEN ACCESS

# Autoimmune limbic encephalitis mimicking inferior myocardial infarction on ECG

Armen Zeitjian ,<sup>1</sup> Benjamin Noor,<sup>2</sup> Robin Chand<sup>2</sup>

<sup>1</sup>Internal Medicine, Harbor-UCLA Medical Center, Torrance, California, USA

<sup>2</sup>Cardiovascular Medicine, Harbor-UCLA Medical Center, Torrance, California, USA

## Correspondence to

Dr Armen Zeitjian;  
azeitjian@dhs.lacounty.gov

Accepted 23 March 2023

## SUMMARY

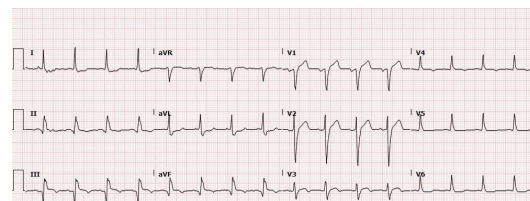
A man in his 60s with prior history of coronary artery bypass graft was found collapsed, unresponsive on the floor by family. ECG demonstrated an inferior ST elevation myocardial infarction. However, coronary angiography was negative for a culprit lesion. A faciobrachial dystonic seizure was witnessed during his hospitalisation, ultimately leading to a diagnosis of leucine-rich glioma-inactivated 1 (LGI-1) autoimmune encephalitis. It is likely that neurogenic stunned myocardium led to this presentation.

## BACKGROUND

ST segment elevation on ECG is a critical and time-sensitive finding that may signify an acute myocardial infarction, which needs emergent coronary revascularisation. However, clinicians should be aware of alternative processes that may mimic acute ST elevation myocardial infarction. One such condition is neurogenic stunned myocardium, a phenomenon in which an acute neurological insult leads to myocardial injury and resultant ECG abnormalities.<sup>1</sup> Once ST elevation myocardial infarction has been excluded, clinicians may be left solving for the underlying cause of the patient presentation. This case highlights an example of neurogenic stunned myocardium, which after exclusion of acute myocardial infarction and further investigation, led to the diagnosis and subsequent treatment of autoimmune limbic encephalitis.

## CASE PRESENTATION

A man in his 60s was found collapsed on the floor at home, awake, but unresponsive by family and brought in by emergency medical services to the hospital emergency department (ED) for evaluation. The field ECG (figure 1) demonstrated inferior ST segment elevations and Q waves with lateral ST depressions consistent with an acute inferior myocardial infarction. The patient denied any symptoms of chest pain or shortness of breath.

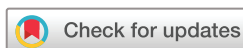

**Figure 2** First hospital ECG in ED. Decrease in amplitude of ST elevations in leads II, III, and aVF, and resolution of ST depressions in leads I and aVL. ED, emergency department.

The patient's medical history was notable for coronary artery disease (CAD) status post coronary artery bypass graft (CABG) 6 years prior and ischaemic cardiomyopathy with an ejection fraction of 25%–30%. His medications included aspirin 81 mg daily, clopidogrel 75 mg daily, carvedilol 12.5 mg two times per day, atorvastatin 40 mg daily and lisinopril 10 mg daily. The patient's social and family histories were unremarkable. On physical examination, blood pressure was 110/80 mm Hg with a heart rate of 75 beats per minute. The patient was mildly confused, oriented to name and location, but not to date. Cardiopulmonary and neurological exams were otherwise unremarkable. Repeat ECG in the emergency room demonstrated persistent inferior ST segment elevations (figure 2) but with a decrease in the amplitude of elevation concerning for dynamic ischaemic changes. The patient was taken emergently for cardiac catheterisation.

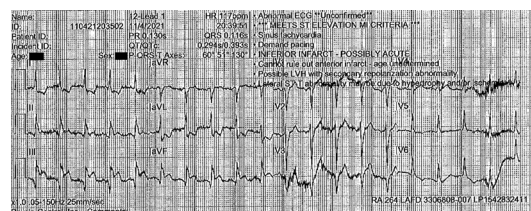
## INVESTIGATIONS

Coronary angiography demonstrated evidence of prior CABG with creation of two bypass conduits (widely patent left internal mammary artery to second diagonal artery, 100% chronic total occlusion of saphenous venous graft to right coronary artery), chronic total occlusions (proximal left anterior descending artery and ostial right coronary artery) and several other non-culprit lesions (50% left main artery lesion and 50% left circumflex lesion). However, a culprit coronary lesion was not identified. Patient was admitted to the cardiac care unit for further management. After cardiac catheterisation, the initial troponin-I level drawn in the ED resulted, and troponin-I level peaked at 0.095 ng/mL (normal <0.04 ng/mL) and declined in a repeat measure 4 hours later before the initiation of any additional intervention. Labs were otherwise notable for a white cell count of  $12 \times 10^9/L$  and sodium of 126 mmol/L. Repeat ECG 30 min after cardiac catheterisation demonstrated resolution of ST segment deviations (figure 3). Transthoracic

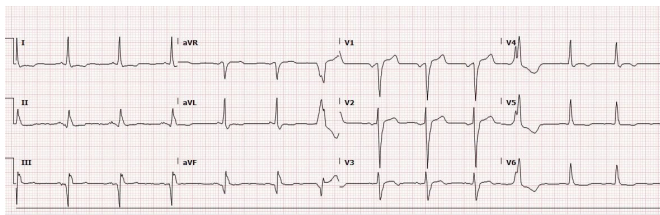


© BMJ Publishing Group Limited 2023. Re-use permitted under CC BY-NC. No commercial re-use. See rights and permissions. Published by BMJ.

**To cite:** Zeitjian A, Noor B, Chand R. *BMJ Case Rep* 2023;**16**:e253754. doi:10.1136/bcr-2022-253754



**Figure 1** Field ECG. ST elevations in leads II, III and aVF with reciprocal ST depressions in leads I and aVL concerning for inferior ST elevation myocardial infarction.



**Figure 3** Second hospital ECG shortly after cardiac catheterisation. Resolutions of ST elevations in II, III and aVF and reciprocal ST depressions in leads I and aVL.

echocardiogram findings were unchanged from prior, demonstrating a left ventricular ejection fraction of 25%–30% with akinesis of the inferior, inferolateral and inferoseptal walls and hypokinesis of the apical myocardium.

Collateral history from the patient's family revealed that the patient had been having progressive short-term memory loss and intermittent episodes of right-hand tremors with non-purposeful eye movements followed by several minutes of somnolence for the past 2 months prior to presentation. Neurology was consulted given the patient's initial presentation and concern for seizure-like activity. Initial electroencephalogram demonstrated mild background slowing. While being interviewed by the neurology team, the patient had a witnessed faciobrachial dystonic seizure, which is pathognomonic for LGI-1 autoimmune encephalitis.<sup>2</sup> MRI brain demonstrated possible T2/fluid attenuated inversion recovery (FLAIR) hyperintensity of bilateral mesial temporal lobes. Both serum and cerebrospinal fluid were positive for LGI-1 immunoglobulin G. Patient was diagnosed with LGI-1 autoimmune encephalitis.

### TREATMENT

High-dose steroids, intravenous immunoglobulins and valproic acid were initiated with improvement in seizure activity and mild improvement in cognitive status. Patient was discharged on prednisone 60 mg daily and levetiracetam 1000 mg two times per day with outpatient neurology follow-up.

### OUTCOME AND FOLLOW-UP

One year after discharge, the patient continues to do well without any symptoms or recurrent seizure episodes.

### DISCUSSION

Central nervous system pathology, namely subarachnoid haemorrhage, but also ischaemic stroke and seizure have previously been associated with abnormal ECG findings that may mimic ischaemia or acute coronary syndrome. There are numerous case reports of patients ultimately diagnosed with subarachnoid haemorrhage whose initial ECG had ST elevations concerning for acute coronary syndrome but with no culprit lesion identified on coronary angiography.<sup>3 4</sup> Ischaemic stroke has also presented with diffuse ST segment elevations, where subsequent coronary angiography did not demonstrate evidence of obstruction or vasospasm.<sup>5</sup> Lastly and notably, a similar case in which a patient with multivessel CAD status post CABG and numerous stent placements was found to have inferior ST elevations after a seizure event, and coronary angiography with optical coherence tomography was negative for acute plaque rupture.<sup>6</sup>

The mechanism by which a primary neurological insult leads to cardiac pathology has been hypothesised in the literature. Subarachnoid haemorrhage, ischaemic stroke and seizure have been associated with sympathetic overactivity and ECG changes

that can resemble widespread myocardial ischaemia.<sup>7</sup> Stimulation of various neural areas including the limbic cortex, which is thought to have influence over the autonomic system, has demonstrated similar effects.<sup>7</sup> Specifically, structures of the limbic system such as the hippocampus and putamen have been implicated by imaging in LGI-1 autoimmune limbic encephalitis.<sup>2</sup> Interestingly, structural differences in the limbic system also including the hippocampal and putamen regions have been seen in patients with a history of Takotsubo cardiomyopathy when compared with healthy controls.<sup>8</sup> Thus recognising this connection, it is possible that LGI-1 autoimmune limbic encephalitis and Takotsubo cardiomyopathy share a similar underlying pathogenesis that is driven by sympathetic overactivity leading to transient myocardial injury, as both disease processes affect similar limbic system structures, namely the hippocampus and putamen. This phenomenon is referred to as neurogenic stunned myocardium, which can manifest in the form of left ventricular dysfunction, ECG changes and/or elevation in serum troponin levels.<sup>1</sup>

How sympathetic overactivity ultimately leads to cardiac injury is still under investigation.<sup>1</sup> One proposed mechanism is that a surge of catecholamines leads to a direct toxic effect on cardiomyocytes on a cellular level through myofibrillar degeneration. The pathophysiology is thought to resemble the mechanism seen in cardiac reperfusion injury. Specifically, norepinephrine has been found to interfere with calcium channels resulting in an influx of calcium ions and induces a release of free radicals, both of which lead to myocardial injury. This leads to disturbances in the cardiac membrane causing ST segment abnormalities that can resemble myocardial ischaemia and infarction.<sup>7</sup> Other proposed mechanisms of neurogenic stunned myocardium include sympathetically driven coronary vasospasm<sup>1 9 10</sup> and increased myocardial demand leading to ischaemia.<sup>1</sup>

This case presentation is most consistent with a faciobrachial dystonic seizure due to LGI-1 autoimmune encephalitis in a patient with obstructive coronary disease presenting with ECG findings mimicking acute myocardial infarction. While ECG demonstrated findings consistent with an inferior ST elevation myocardial infarction (STEMI), diagnostic workup including coronary angiography did not demonstrate evidence of a culprit lesion. Current literature suggests that central nervous system pathology, especially disease that affects structures of the limbic system such as the hippocampus and putamen, may trigger a pathological level of sympathetic overactivity with toxic effects on myocardial tissue, which can manifest in the form of ischaemic ECG findings. Clinicians should be aware of this relationship and consider neurological workup once acute coronary syndrome has been ruled out.

### Learning points

- ▶ To be able to recognise neurogenic stunned myocardium as a potential mimic of acute myocardial infarction on ECG.
- ▶ To understand the underlying pathophysiology of neurogenic stunned myocardium.
- ▶ To understand the importance of keeping a broad differential and revisiting the history and physical when a unifying diagnosis has not presented itself.

**Twitter** Armen Zeitjian @a\_zeitjian

**Contributors** AZ performed detailed literature review, wrote draft of full manuscript and made all revisions, formatted text, formatted works cited and obtained consent from the patient. BN acquired history and physical exam, helped

with conception and design and revisions of manuscript. RC helped with conception and design of case and revisions of manuscript.

**Funding** The authors have not declared a specific grant for this research from any funding agency in the public, commercial or not-for-profit sectors.

**Competing interests** None declared.

**Patient consent for publication** Consent obtained directly from patient(s).

**Provenance and peer review** Not commissioned; externally peer reviewed.

**Open access** This is an open access article distributed in accordance with the Creative Commons Attribution Non Commercial (CC BY-NC 4.0) license, which permits others to distribute, remix, adapt, build upon this work non-commercially, and license their derivative works on different terms, provided the original work is properly cited and the use is non-commercial. See: <http://creativecommons.org/licenses/by-nc/4.0/>.

Case reports provide a valuable learning resource for the scientific community and can indicate areas of interest for future research. They should not be used in isolation to guide treatment choices or public health policy.

#### ORCID iD

Armen Zeitjian <http://orcid.org/0000-0002-2383-9373>

#### REFERENCES

- 1 Biso S, Wongrakpanich S, Agrawal A, *et al*. A review of neurogenic stunned myocardium. *Cardiovasc Psychiatry Neurol* 2017;2017:5842182.
- 2 Irani SR, Michell AW, Lang B, *et al*. Faciobrachial dystonic seizures precede LGI1 antibody limbic encephalitis. *Ann Neurol* 2011;69:892–900.
- 3 Park I, Kim YJ, Ahn S, *et al*. Subarachnoid hemorrhage mimicking ST-segment elevation myocardial infarction after return of spontaneous circulation. *Clin Exp Emerg Med* 2015;2:260–3.
- 4 Hirsch GA, Heldman AW, Wittstein IS, *et al*. ST-segment elevation in an unresponsive patient. *Circulation* 2003;108.
- 5 Chiam P, Ong C, Kwok BWK. Images in cardiology. widespread ST segment elevation caused by cerebral infarction. *Heart* 2006;92:535.
- 6 Mously H, Wazzan M, Alkhatlan AZ, *et al*. Seizure-associated st elevation myocardial infarction in absence of plaque rupture. *Case Rep Med* 2018;2018:6186521.
- 7 Samuels MA. The brain-heart connection. *Circulation* 2007;116:77–84.
- 8 Hiestand T, Hänggi J, Klein C, *et al*. Takotsubo syndrome associated with structural brain alterations of the limbic system. *J Am Coll Cardiol* 2018;71:809–11.
- 9 Wang T-D, Wu C-C, Lee Y-T. Myocardial stunning after cerebral infarction. *Int J Cardiol* 1997;58:308–11.
- 10 Lanza GA, Careri G, Crea F. Mechanisms of coronary artery spasm. *Circulation* 2011;124:1774–82.

Copyright 2023 BMJ Publishing Group. All rights reserved. For permission to reuse any of this content visit <https://www.bmj.com/company/products-services/rights-and-licensing/permissions/>  
BMJ Case Report Fellows may re-use this article for personal use and teaching without any further permission.

Become a Fellow of BMJ Case Reports today and you can:

- ▶ Submit as many cases as you like
- ▶ Enjoy fast sympathetic peer review and rapid publication of accepted articles
- ▶ Access all the published articles
- ▶ Re-use any of the published material for personal use and teaching without further permission

#### Customer Service

If you have any further queries about your subscription, please contact our customer services team on +44 (0) 207111 1105 or via email at [support@bmj.com](mailto:support@bmj.com).

Visit [casereports.bmj.com](http://casereports.bmj.com) for more articles like this and to become a Fellow