



OPEN ACCESS

Inferior vena cava agenesis: a rare cause of deep vein thrombosis

Gareth John Williams ^{1,2}, Peter Chowdhury,³ Stuart Packham⁴

¹Department of Infection, Immunity and Cardiovascular Disease, The University of Sheffield, Sheffield, UK

²General Medicine, Swansea Bay University Health Board, Swansea, UK

³Radiology, Swansea Bay University Health Board, Swansea, UK

⁴Respiratory Medicine, Swansea Bay University Health Board, Swansea, UK

Correspondence to
Dr Gareth John Williams;
garethw512@doctors.net.uk

Accepted 14 November 2022

SUMMARY

The development of deep vein thrombosis (DVT) is influenced by a myriad of risk factors which are seen across a wide spectrum of healthcare settings. We present a previously fit and well male in his early 40s with extensive bilateral lower limb DVT associated with total inferior vena cava (IVC) agenesis. The diagnosis was made with contrast-enhanced CT imaging of the abdomen and pelvis. With no demonstrable subhepatic IVC, the majority of the venous drainage was via large azygous veins and distended collateral vessels. Lifelong anticoagulation was advised by both haematology and vascular surgery teams. IVC agenesis represents a very rare and largely unknown clinical entity within the medical community with currently no firmly established pathogenesis, guideline for future VTE prophylaxis or standardised follow-up strategy.

BACKGROUND

The assessment and management of deep vein thrombosis (DVT) is seen in a variety of primary and secondary care settings. With an annual incidence of 1–2 per 1000 in the general population of the UK, virtually all clinicians can expect to see this condition in their practice. A variety of risk factors contribute to the formation of a venous thrombus which adhere to the Virchow's triad principle of clot formation.¹ Since the presence of a DVT can lead to the sequelae of pulmonary embolism (PE), a potentially life-threatening migration of thrombus from the clot formation site to the pulmonary arteries via the right heart, prompt identification and treatment is paramount to improve outcomes for patients. The initiation of oral anticoagulation therapy represents the cornerstone of DVT management, with follow-up arrangements to investigate for the presence of important underlying conditions, including malignancy, thrombophilia and genetic risk factors.

CASE PRESENTATION

A man in his early 40s presented to his general practitioner with a 2-week history of bilateral leg pain and swelling, along with lower back pain. The initial symptoms were described as an intense 'sciatica-like' shooting pain down the left leg which occurred at rest. This event lasted approximately 30 min with a '10/10' severity, followed by a spontaneous gradual improvement in discomfort. The pain became a dull ache which was reported to reside at the lower back radiating to both legs. Over the following days, the patient noticed a gradual swelling in both lower limbs, describing

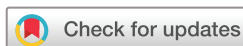both calves and eventually thighs as feeling tight, reducing mobility significantly. The patient denied any recent significant trauma or prolonged period of immobility, although he did report a reduction in his outdoor exercise frequency due to the pandemic social isolation restrictions. The patient was otherwise fit and well, having never suffered any serious medical illness in the past and was not taking any regular medication. The only history of note was the presence of varicose veins in both lower limbs which had been present from his teenage years, for which he had taken to wearing compression stockings in the past. He denied any chest pain, shortness of breath, cough or haemoptysis.

On presenting to his general practitioner, it was found on examination that this male had gross bilateral pitting oedema to his thighs with superficial vessels noted and tenderness along the posterior aspect of both thighs. The legs did not visually appear erythematous on examination and no visible signs of bruising or trauma were apparent. The remainder of his physical examination was normal, with no features suggestive of infection or vasculitis present. A pretest clinical probability Well's score for this male's presentation was 3, placing him at high risk of a DVT.

INVESTIGATIONS

Routine bloods demonstrated a new normocytic anaemia with a significant iron deficiency and a mild derangement of his clotting time. A raised C reactive protein level and ferritin level was also observed (table 1). Doppler ultrasound scanning was unable to compress or demonstrate flow in either common femoral vein, which was attempted using two separate machines (see figure 1). The appearances were suggestive of bilateral DVTs, with no discernible upper limit demonstrated. In addition, the inferior vena cava (IVC) could not be visualised. A chest X-ray was reported as having normal lung fields with a normal cardiac silhouette.

A contrast-enhanced CT scan of the abdomen and pelvis was performed on the same day of the ultrasound scan to assess the extent of the thrombotic disease and to investigate for underlying malignancy. The study demonstrated marked thrombosis of both superficial, common femoral and iliac veins (figures 2 and 3). Furthermore, there was no demonstrable subhepatic IVC, with the majority of venous drainage to the heart seemingly provided by dilated azygous veins (see figure 4). A solitary low density focal lesion was noted on the liver capsule, which is likely to be a simple cyst or haemangioma.



© BMJ Publishing Group Limited 2022. Re-use permitted under CC BY-NC. No commercial re-use. See rights and permissions. Published by BMJ.

To cite: Williams GJ, Chowdhury P, Packham S. *BMJ Case Rep* 2022;**15**:e250511. doi:10.1136/bcr-2022-250511

Table 1 Initial blood test results on admission

Test	Result	Normal values
Haemoglobin (g/L)	110	130–180
White cell count ($\times 10^9/L$)	8.7	4.0–11.0
Platelet count ($\times 10^9/L$)	566	150–400
Haematocrit (L/L)	0.34	0.40–0.52
Mean cell volume	90	80–100
Neutrophil count ($\times 10^9/L$)	5.4	1.7–7.5
Lymphocyte count ($\times 10^9/L$)	2.0	1.0–4.5
Prothrombin time (seconds)	11.1	9.0–12.5
APTT (seconds)	21.9	22.1–30.9
Clauss fibrinogen level (g/L)	6.1	2.0–4.0
Urea and electrolytes	All results within normal ranges	
Liver function tests	All results within normal ranges	
C reactive protein (mg/L)	111	<5
Ferritin (ug/L)	1142	15–300
Transferrin (g/L)	1.9	2.0–4.0
Transferrin saturations	10.5%	20%–50%
Iron (umol/L)	5	10–30
Vitamin B ₁₂ (ng/L)	181	200–900
Folate (ug/L)	12.6	>3

DIFFERENTIAL DIAGNOSIS

The diagnosis of chronic IVC occlusion was considered as an alternative diagnosis given the original CT findings. However, on specialist radiology consultant review of the images, the lack of any demonstrable thrombus superior to the iliac veins along with the well-developed azygous collateral venous drainage were characteristic of a diagnosis of IVC agenesis (IVCA).

TREATMENT

Given the man's high pretreatment clinical risk score, apixaban had been initiated by his general practitioner 2 days prior to the doppler ultrasound scan appointment. Following the result of the CT scan, a discussion with the haematology team advised continuing the apixaban treatment indefinitely.

OUTCOME AND FOLLOW-UP

The patient was discharged from hospital with apixaban following inpatient medical review. A review of the case details

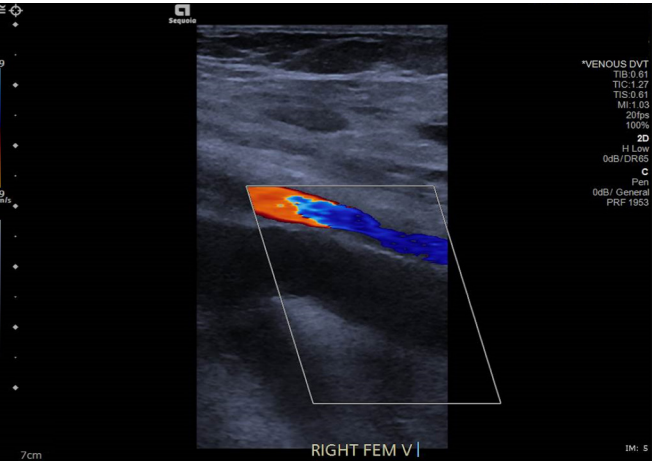


Figure 1 Ultrasound scan image of right femoral vessels: common femoral vein is distended by thrombus and there is absent Doppler flow; normal femoral artery doppler flow. DVT, deep vein thrombosis.

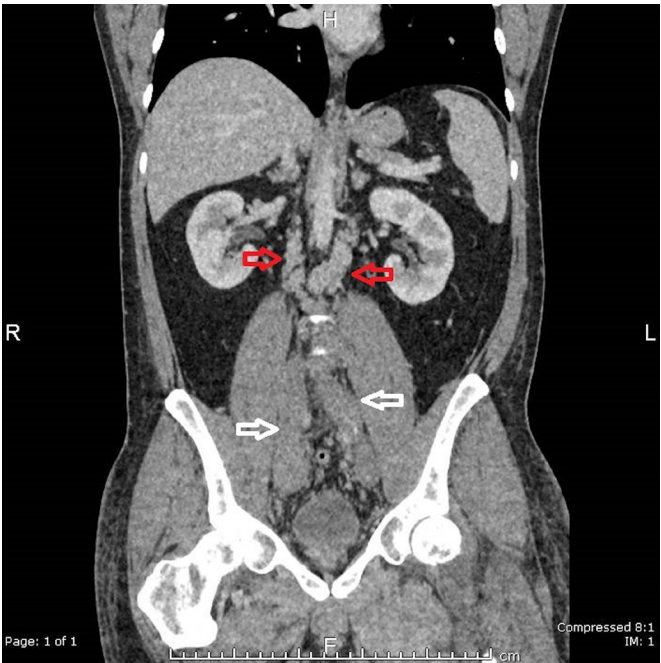


Figure 2 Coronal CT image of the abdomen and pelvis. The white arrows indicate thrombosed iliac veins, the red arrows indicate multiple distended collateral veins.

and CT images by the local vascular surgery multidisciplinary team agreed with the diagnosis and management plan and advised further review if the patient developed phlegmasia. A gastroenterology referral was arranged to follow up the finding of normocytic anaemia associated with iron deficiency and venous thromboembolism in order to rule out a gastrointestinal tract malignancy as a source of blood loss.

A follow-up CT study of the abdomen and pelvis at 3 months demonstrated complete resolution of the iliac vein thromboses,

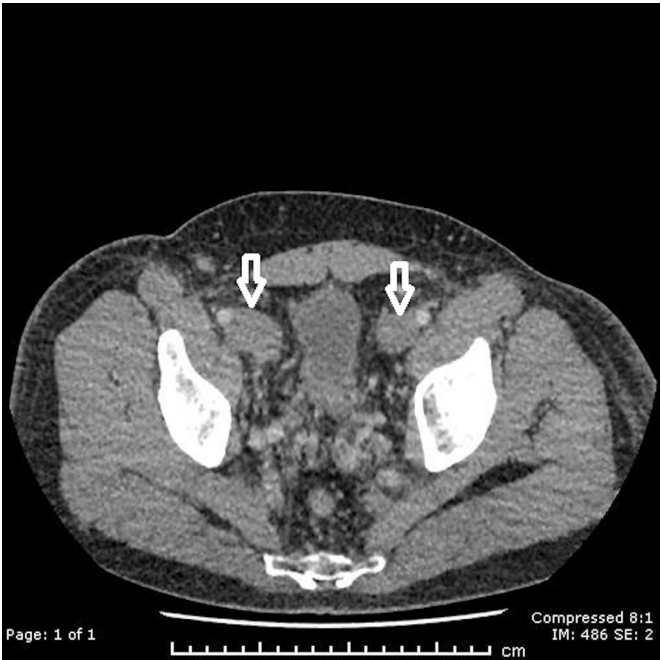


Figure 3 Axial CT images of the abdomen and pelvis. The white arrows indicate thrombosed iliac veins.

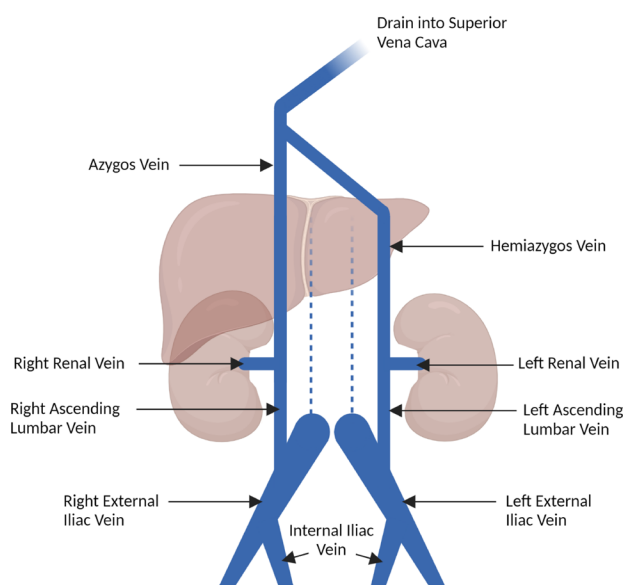


Figure 4 Illustration of proposed venous drainage observed in this case report, with key vessels highlighted. The broken blue line indicates the typical location of the inferior vena cava, which is not visible in this case. (Created by GJW with Biorender.com).

with no demonstrable IVC structure visible. The images were reviewed by an interventional vascular radiology consultant, who confirmed the diagnosis of IVCA with no additional assessments or treatments advised. During a follow-up discussion 6 months after his presentation, the patient reported a complete resolution of his lower limb oedema and a return to his normal levels of physical activity.

DISCUSSION

The occurrence of major structural abnormalities of the deep venous system are widely described, with an estimated prevalence of around 0.5% within the general population.² As the largest venous structure within the body, the embryogenesis of the IVC arises from a number of vessels within the supracardinal system, which begins development between 6th and 8th week of gestation.³ From cranial to caudal, the anastomosis and regression of the subcardinal, supracardinal and posterior cardinal veins form the subhepatic IVC. Congenital variations of the adult IVC structure were first described over two centuries ago, with a number of variant structures described.⁴ Examples of significant IVC anatomical variations include left-sided IVC, double IVC and absence of the IVC, either partial or complete. Examples of partial absence of the IVC are theorised to be the failure of one segment of the primitive IVC to connect with another; examples include absence of hepatic IVC (or azygous continuation of IVC) and absence of the infrarenal IVC, implying failures in development between subcardinal-hepatic vein and the posterior cardinal-supracardinal vein anastomoses, respectively.⁵ Given the significant variations possible from the normal adult structure, congenital deviations of IVC structure can present significant challenges for many clinical, diagnostic and surgical procedures.

Congenital absence of the entire IVC represents a particularly peculiar phenomenon. Given its embryological origin, a failure in formation of the entire IVC implies agenesis and failure in anastomosis of several venous structures. The exact pathological

mechanism by which multiple venous systems fail to form the single largest vein within the body is unknown. IVCA is historically quoted to have an annual incidence of as low as 0.0005% within the general population, with accurate estimations lacking due to the largely asymptomatic nature of the condition.⁶ While its presence within the general population is unclear, it has been largely observed in patients who present with DVT as an incidental finding, particularly in young adults. Anatomical venous anomalies are well known to be associated with the development of DVT, with around 5%–6.7% of patients between 20 and 40 years of age presenting with DVT observed as having some form of structural abnormality of the IVC.² This represents a 10-fold increase in the estimated prevalence of IVC abnormalities in the general population. Furthermore, the presence of bilateral limb

Patient's perspective

'Before all the changes with the Coronavirus Lockdown, I was a fairly active person. I had a structured daily exercise routine which involved regularly walking every morning with the dog, getting ready for work, and cycling 25 miles on most weekends. Recent changes in my daily routine: working from home, walking less each day, has led me to be more sedentary than usual.'

'Before all of this, I've never had any problems with my health, no issues with clots or leg swelling. I had a large varicose vein in my right leg removed a number of years ago for aesthetic and comfort reasons, with some smaller ones present in both legs since my teenage years.'

'I initially had some lower back pain and lower abdominal pain, which I tried to walk off with the dog, but it never seemed to go away. A few days later I felt an almighty shooting pain down my back to my left leg, which felt like a massive spasm that I thought was a muscle pain or sciatica. That episode lasted for a full week, by which time both my legs started swelling up to the top of my thighs towards my groin and I went to see my doctor.'

'It's still a complete shock, I can't believe that I have this condition. I've never felt like I've had any issues with my body, especially that a major part of my body seems to be missing! I really didn't know how this would affect the rest of my life, or what I would or wouldn't be able to do. I didn't really know how to process the news, as I didn't know something like this could happen.'

'I've been doing far more reading on clots in the body, which I've taken a great interest in how it affects the body. I appreciate that I could be on tablets for the rest of my life because of this. My friend, who is a physiotherapist, couldn't understand how I could develop this double leg swelling out of the blue. She identified it could be a potential clot and to see my GP immediately. My family and people from my work have been really shocked, finding out that a major vein in my body is missing. Since taking the Apixaban, it took around 5 days to start feeling a benefit. It feels like I'm getting back to normal, with my right leg practically back to normal. It's still taking time to get back to normal after a few weeks, but I feel lucky that things are improving and that within 3 months I'm hoping to be back to my usual routine.'

'I'd like to thank everyone for my treatment, for reacting quickly to my condition and arranging all the scans so well. I didn't think all this could still happen so well during the lockdown, and I'm grateful for all the care from across all the different teams.'

Case report

Learning points

- Congenital inferior vena cava abnormalities represent a rare and highly significant risk factor for the development of deep vein thrombosis (DVT), particularly in younger patients.
- Unprovoked DVT requires thorough consideration and investigations for subtle underlying conditions.
- A multidisciplinary approach with haematology and vascular surgery services is required to ensure that the assessment and management of patients with rare venous malformations is balanced with the best available evidence and clinical expertise.

DVT within this cohort was also observed in 35.4%–62.5% of patients, compared with up to 8.6% of all acute DVT presentations.⁷ Therefore, while there are unanswered questions regarding the pathogenesis and true prevalence within the general population, the association of congenital IVC anomalies within younger patients presenting with bilateral DVT requires significant consideration, particularly in the follow-up investigations for underlying risk factors.

The management of patients with IVCA represents a significant challenge to clinicians. The reported diagnosis of the condition in the literature frequently describes previously fit and healthy individuals with no other recognisable risk factors for DVT who present with extensive lower limb venous thromboembolism, making early identification of the condition challenging.⁸ In one case, a military serviceman presenting with a lower limb DVT was subsequently diagnosed with IVCA, who presumably underwent multiple medical and fitness examinations with no concerns raised prior to their presentation.⁹ Due to the sporadic incidence of the condition being reported within case reports and case series, there is currently no well-established guidelines or recommendations on the optimal diagnostic criteria or management of these patients. The diagnosis of IVCA is usually made incidentally during follow-up investigations for DVT, with the possibility for MR venography or diagnostic angiography to further confirm the anatomical variation. Patients have been successfully managed with a variety of initial anticoagulation strategies, including intravenous unfractionated heparin, oral anticoagulation (either with warfarin or direct oral anticoagulants), thrombolysis and catheter-guided thrombolysis.^{8–12} Despite the variation in initial anticoagulation strategy, there is general agreement that lifelong anticoagulation is advised in these patients. Long-term outcomes in the above case reports have not reported a significant recurrence rate of DVT while taking long-term anticoagulation. Surgical reconstruction of an IVCA has been reported, although this was in a case where the presenting complaint was recurring venous ulceration rather than thromboembolic disease.¹³ A final consideration is the development of PE, the potentially fatal evolution of DVT. Despite the extensive and often bilateral nature of thrombotic disease observed in this cohort, the rate of concurrent PE has been reported at 9.7%, compared with 56%–61% of all presentations of DVT.^{14 15} A potential theory offered to explain this phenomenon is the relatively smaller diameter azygous veins

which act as filters for larger embolisms. Given the rarity of total IVCA, a prolonged multicentre study would likely be needed to provide further evidence as to the optimal approach to patient management.

Twitter Gareth John Williams @DrGarethJW

Contributors GJW: medical registrar involved in patient's care during admission and follow up; writing of original manuscript and revision of manuscript as per coauthor and reviewer feedback. PC: reviewed manuscript and provided feedback; provided clinical input on imaging as radiology consultant on call during patient's admission. SP: consultant on call during patient's admission; reviewed manuscript versions and provided feedback.

Funding The authors have not declared a specific grant for this research from any funding agency in the public, commercial or not-for-profit sectors.

Competing interests None declared.

Patient consent for publication Consent obtained directly from patient(s).

Provenance and peer review Not commissioned; externally peer reviewed.

Open access This is an open access article distributed in accordance with the Creative Commons Attribution Non Commercial (CC BY-NC 4.0) license, which permits others to distribute, remix, adapt, build upon this work non-commercially, and license their derivative works on different terms, provided the original work is properly cited and the use is non-commercial. See: <http://creativecommons.org/licenses/by-nc/4.0/>.

Case reports provide a valuable learning resource for the scientific community and can indicate areas of interest for future research. They should not be used in isolation to guide treatment choices or public health policy.

ORCID iD

Gareth John Williams <http://orcid.org/0000-0002-7356-3889>

REFERENCES

- Anderson FA, Spencer FA. Risk factors for venous thromboembolism. *Circulation* 2003;107:19–16.
- Chee Y-L, Culligan DJ, Watson HG. Inferior vena cava malformation as a risk factor for deep venous thrombosis in the young. *Br J Haematol* 2001;114:878–80.
- Malaki M, Willis AP, Jones RG. Congenital anomalies of the inferior vena cava. *Clin Radiol* 2012;67:165–71.
- Abernethy J, Banks J. Account of two instances of uncommon formation, in the viscera of the human body. *Philos Trans R Soc Lond* 1793;83:59–66.
- Bass JE, Redwine MD, Kramer LA, et al. Spectrum of congenital anomalies of the inferior vena cava: cross-sectional imaging findings. *RadioGraphics* 2000;20:639–52.
- Sneed D, Hamdallah I, Sardi A. Absence of the retrohepatic inferior vena cava: what the surgeon should know. *Am Surg* 2005;71:502–4.
- Rance A, Emmerich J, Guedj C, et al. Occult cancer in patients with bilateral deep-vein thrombosis. *The Lancet* 1997;350:1448–9.
- Ruggeri M, Tosetto A, Castaman G, et al. Congenital absence of the inferior vena cava: a rare risk factor for idiopathic deep-vein thrombosis. *The Lancet* 2001;357:441.
- Kim S, Kunkel S, Broske K. Absent inferior vena cava leading to recurrent lower extremity deep vein thrombosis in a United States marine. *Mil Med* 2018;183:e172–4.
- Iqbal J, Nagaraju E. Congenital absence of inferior vena cava and thrombosis: a case report. *J Med Case Rep* 2008;2:46.
- Chew RR, Lim AH, Toh D. Congenital absence of inferior vena cava: an under recognised cause of unprovoked venous thromboembolism. *QJM Int J Med* 2018;111:117–8.
- Tarazi M, Bashir A, Khan K, et al. A literature review and case series of DVT patients with absent IVC treated with thrombolysis. *Ann Vasc Surg* 2020;67:521–31.
- Grieff AN, Shafritz R, Beckerman WE. Extravascular reconstruction of a congenitally absent inferior vena cava. *J Vasc Surg Cases Innov Tech* 2020;6:681–5.
- Lambert M, Marboeuf P, Midulla M, et al. Inferior vena cava agenesis and deep vein thrombosis: 10 patients and review of the literature. *Vasc Med Lond Engl* 2010;15:451–9.
- Cordeanu E-M, Lambach H, Heitz M, et al. Pulmonary embolism and coexisting deep vein thrombosis: a detrimental association? *J Clin Med* 2019;8:899.

Copyright 2022 BMJ Publishing Group. All rights reserved. For permission to reuse any of this content visit <https://www.bmj.com/company/products-services/rights-and-licensing/permissions/>
BMJ Case Report Fellows may re-use this article for personal use and teaching without any further permission.

Become a Fellow of BMJ Case Reports today and you can:

- ▶ Submit as many cases as you like
- ▶ Enjoy fast sympathetic peer review and rapid publication of accepted articles
- ▶ Access all the published articles
- ▶ Re-use any of the published material for personal use and teaching without further permission

Customer Service

If you have any further queries about your subscription, please contact our customer services team on +44 (0) 207111 1105 or via email at support@bmj.com.

Visit casereports.bmj.com for more articles like this and to become a Fellow