

See-saw nystagmus in giant craniopharyngioma

Gunjan Saluja,¹ Asha Samdani,¹ Priyavrat Bhatia²

¹Dr Rajendra Prasad Centre for Ophthalmic Sciences, All India Institute of Medical Sciences, New Delhi, India
²Vitreo-Retina, Sadguru Netra Chikitsalaya, Chitrakoot, India

Correspondence to

Dr Gunjan Saluja;
gunjansaluja2015@gmail.com

Accepted 29 April 2020

DESCRIPTION

See-saw nystagmus is a rare but a typical symptom, and has been reported with an array of pathologies which include suprasellar tumours,^{1,2} congenital achiasma,³ congenital anomalies of brainstem like Arnold Chiari malformation,⁴ multiple sclerosis⁵ and Wallenberg syndrome.⁶ But see saw nystagmus with giant craniopharyngioma and giant pituitary adenoma has been sparsely reported.⁷⁻⁹ We hereby report a case of a child who presented with see saw nystagmus and was eventually diagnosed with giant craniopharyngioma.

The parents of a 4-year-old child presented to us with symptoms that their child was not following light and objects which they noticed since last 6 months, they also noted that child had jerky eye movements along with this associated with outward deviation of eye. The child was then shown to a nearby primary centre and was later referred to our centre for further investigations. There was no history of fever, trauma and birth history was normal with normal milestones. On examination the child was not following light and objects in both eyes. Pupils in both eyes were sluggishly reacting. Ocular movements revealed a typical pattern of movements, wherein one eye was elevating and intorting and other eye depressing and extorting at the same time, suggestive of typical see saw nystagmus (video 1). Fundus examination revealed bilateral secondary optic atrophy.

Contrast enhanced MRI was advised which revealed the presence of a large supra sellar solid cystic mass compressing the third ventricles and causing dilatation of bilateral lateral ventricles suggestive of craniopharyngioma (figure 1).

The child was immediately referred to the neurosurgery department of the institute. The child was lost to follow-up.

See saw nystagmus was first described by Maddox.¹⁰ The nystagmus has a unique characteristic feature, in the first phase of nystagmus one

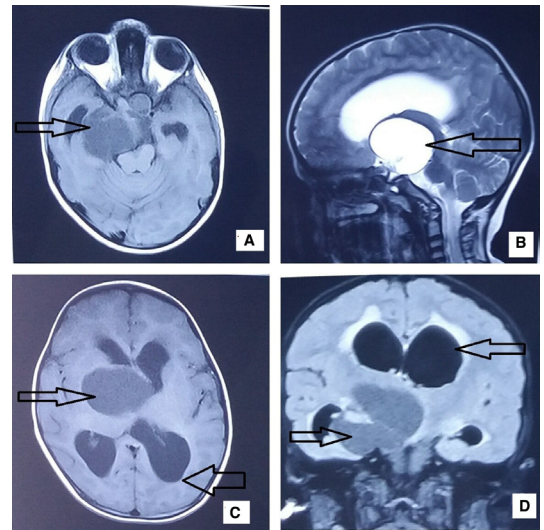


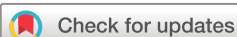Figure 1 Axial (A, C), sagittal (B) and coronal (D) view of contrast enhanced MRI showing a large suprasellar solid cystic mass, compressing the third ventricle. Note the dilated lateral ventricle.

eye elevates and intorts and other eye depresses and extorts, while in the second phase this pattern of nystagmus is reversed. The exact pathogenesis of this peculiar nystagmus in cases of suprasellar lesions is still not known and has been hypothesised to be due to associated visual disturbances.¹¹ See saw nystagmus has also been associated with brainstem pathologies and is believed to result from the dysfunction of intestinal nucleus of Cajal, medial longitudinal fasciculus or vestibular nucleus.¹²

In our case see saw nystagmus can be explained by the presence of the giant craniopharyngioma. Craniopharyngiomas are epithelial tumours arising from the residual cells of Rathke's pouch, and account for 5.6%–13% of all intracranial childhood tumours.¹³ Trejos *et al* have defined giant craniopharyngiomas as the ones having suprasellar or frontal extension with a volume of >100 cm³. The classification system helps to determine the prognosis and recurrence of tumour after surgery.¹⁴



Video 1 See-saw nystagmus, note that one eye is elevating and intorting, while the other eye is depressed and is extorting



© BMJ Publishing Group Limited 2020. No commercial re-use. See rights and permissions. Published by BMJ.

To cite: Saluja G, Samdani A, Bhatia P. *BMJ Case Rep* 2020;**13**:e235435. doi:10.1136/bcr-2020-235435

Learning points

- ▶ See saw nystagmus can be associated with a large number of aetiologies in the chiasmal and brainstem region.
- ▶ Presence of see saw nystagmus in a child must be considered as a red flag, and imaging must be advised in all cases.

Twitter Priyavrat Bhatia @priyavratbhatia

Contributors GS and AS worked up the case. PB critically reviewed the manuscript.

Funding The authors have not declared a specific grant for this research from any funding agency in the public, commercial or not-for-profit sectors.

Competing interests None declared.

Patient consent for publication Parental/guardian consent obtained.

Provenance and peer review Not commissioned; externally peer reviewed.

REFERENCES

- 1 Fein JM, Williams DB. See-Saw nystagmus. *J Neurol Neurosurg Psychiatry* 1969;32:202–7.
- 2 Moura FC, Gonçalves ACP, Monteiro MLR. Seesaw nystagmus caused by giant pituitary adenoma: case report. *Arq Neuropsiquiatr* 2006;64:139–41.
- 3 Prakash S, Dumoulin SO, Fischbein N, et al. Congenital achiasma and see-saw nystagmus in VACTERL syndrome. *J Neuroophthalmol* 2010;30:45–8.
- 4 Zimmerman CF, Roach ES, Troost BT. See-Saw nystagmus associated with Chiari malformation. *Arch Neurol* 1986;43:299–300.
- 5 Sandramouli S, Benamer HT, Mantle M, et al. See-Saw nystagmus as the presenting sign in multiple sclerosis. *J Neuroophthalmol* 2005;25:56–7.
- 6 Porta-Etessam J, Casanova I, Pajuelo B, et al. See-Saw nystagmus in a patient with Wallenberg syndrome. *J Neuroophthalmol* 2009;29:73–4.
- 7 Daroff RB. Nystagmus S. See-Saw nystagmus. *Neurology* 1965;15:874–7.
- 8 Druckman R, Ellis P, Kleinfeld J, et al. Seesaw nystagmus. *Arch Ophthalmol* 1966;76:668–75.
- 9 Safran AB, Berney J, Panchaud A. [See-saw nystagmus in a case of giant adenoma of the hypophysis]. *Rev Med Suisse Romande* 1980;100:343–7.
- 10 Maddox E. See-Saw nystagmus with bitemporalhemianopia. *Proc R Soc Med* 1914;7:12–13.
- 11 Slatt B, Nykiel F, Nystagmus S. See-Saw nystagmus. *Am J Ophthalmol* 1964;58:1016–21.
- 12 Nakada T, Kwee IL. Seesaw nystagmus. Role of visuovestibular interaction in its pathogenesis. *J Clin Neuroophthalmol* 1988;8:171–7.
- 13 Karavitaki N, Brufani C, Warner JT, et al. Craniopharyngiomas in children and adults: systematic analysis of 121 cases with long-term follow-up. *Clin Endocrinol* 2005;62:397–409.
- 14 Trejos H, Caceres A, Segura JL. Monstrous craniopharyngioma. Case presentations and term proposal. *Childs Nerv Syst* 2005;21:1049–53.

Copyright 2020 BMJ Publishing Group. All rights reserved. For permission to reuse any of this content visit <https://www.bmj.com/company/products-services/rights-and-licensing/permissions/>
BMJ Case Report Fellows may re-use this article for personal use and teaching without any further permission.

Become a Fellow of BMJ Case Reports today and you can:

- ▶ Submit as many cases as you like
- ▶ Enjoy fast sympathetic peer review and rapid publication of accepted articles
- ▶ Access all the published articles
- ▶ Re-use any of the published material for personal use and teaching without further permission

Customer Service

If you have any further queries about your subscription, please contact our customer services team on +44 (0) 207111 1105 or via email at support@bmj.com.

Visit casereports.bmj.com for more articles like this and to become a Fellow