

# Erection of pinna

Aswin Chandran , Hitesh Verma , Jithin C Shaji, Pirabu Sakthivel 

Otorhinolaryngology & Head and Neck Surgery, All India Institute of Medical Sciences, New Delhi, India

**Correspondence to**  
Dr Pirabu Sakthivel;  
pirabusakthivel@gmail.com

Accepted 13 November 2020

## DESCRIPTION

A 6-year-old child was brought to the otorhinolaryngology emergency by his parents with 3 days history of fever, and painful right-sided postauricular swelling. They denied any history of ear discharge, trauma, surgery or previous bouts of acute otitis media. On physical examination, a tender, erythematous and fluctuant postaural swelling was seen with pinna pushed forwards, downwards and outwards (erection of pinna) appearance (figure 1A,B). The otoscopy showed a whitish mass medial to the intact hyperaemic tympanic membrane. High-resolution CT (HRCT) of the temporal bone revealed complete opacification of the right mastoid air cells with erosion of mastoid cortex and subperiosteal collection (figure 1C,D) confirming a diagnosis of acute mastoiditis with subperiosteal abscess due to congenital cholesteatoma. The child underwent emergency canal wall down modified radical mastoidectomy with removal of cholesteatoma from mastoid and middle ear and preservation of intact ear ossicles along with drainage of postaural abscess under perioperative antibiotic coverage. The child had an uneventful recovery and remained asymptomatic at 1-year follow-up visit.

Congenital cholesteatoma is a rare entity of temporal bone comprising 2%–5% of all cholesteatoma and is diagnosed by the presence of a pearly white mass medial to an intact tympanic membrane without any history of otorrhea, perforation or previous otological surgery. It usually presents with otalgia, hearing loss and rarely postauricular

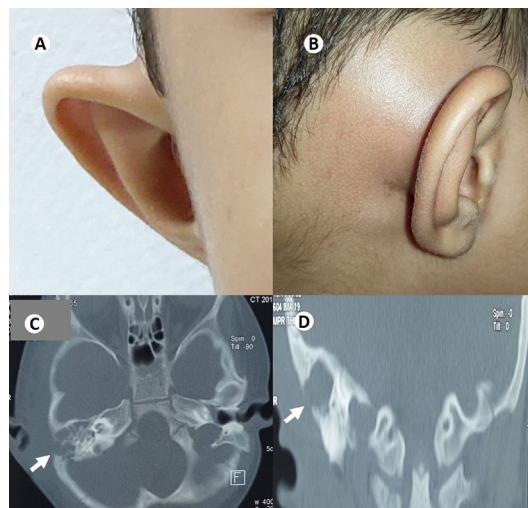
swelling in the advanced stage due to erosion of mastoid cortex.<sup>1</sup> Acute mastoiditis is the most common intratemporal complication of otitis media in children, rarely occur due to congenital cholesteatoma, and presents with postauricular tender swelling, erythema and pinna protrusion.<sup>2</sup> The subperiosteal abscess occurs as a complication of untreated acute mastoiditis as the infection spread by erosion of the mastoid cortex, or along the tympanomastoid suture or through vascular channel into the subperiosteal space. Younger children because of their immature immunity and higher risk factors for otitis media are vulnerable to acute mastoiditis and subperiosteal abscess. The pinna proptosis or ‘erection of pinna’ is a tell-tale sign of acute mastoiditis complicated by subperiosteal abscess as pinna is pushed forward, and downward, and outwards.<sup>2</sup> Acute mastoiditis should be differentiated from postauricular furunculosis or suppurative lymphadenitis, otitis externa

## Patient’s relative perspective

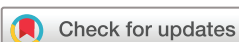‘I noticed a swelling behind the right ear of my child for the last few days which has become increased in size, more reddish and painful for last 2 days which compelled me to bring him to the emergency. He never had an ear discharge, ear pain in the past. His ear position was altered compared with the other ear. The doctors suggested that my child is having infection with pus collection behind my child’s right ear and they advised for immediate surgery after 2 days of antibiotics. My child underwent surgery for the same and had good recovery at the hospital with the shape of pinna returning to normal in a months’ time. My doctors had advised for a regular follow-up after discharge from hospital and warned me regarding the possibility of recurrence of infection in the ear.’

## Learning points

- ▶ The erection of pinna along with a tender postaural swelling in a child should point towards a diagnosis of acute mastoiditis.
- ▶ Owing to its possible intracranial and extracranial complication acute mastoiditis is a serious life-threatening complication of otitis media in children and should be promptly treated.
- ▶ The treatment of choice is broad-spectrum antibiotics or mastoid exploration and the latter is reserved for non-responsive cases or those with more complications.



**Figure 1** Clinical image depicting the pinna position (A), fluctuant postaural swelling (B). Axial and coronal high-resolution CT scans of the temporal bones showing complete opacification of the right mastoid air cells with erosion of mastoid cortex (indicated by arrow in C and D).



© BMJ Publishing Group Limited 2020. No commercial re-use. See rights and permissions. Published by BMJ.

**To cite:** Chandran A, Verma H, Shaji JC, et al. *BMJ Case Rep* 2020;**13**:e239745. doi:10.1136/bcr-2020-239745

and rare causes like granulomatous polyangitis, tuberculosis, lymphoma, fungal mastoiditis, and Langerhans cell histiocytosis.<sup>3</sup> An untreated acute mastoiditis may cause significant and life-threatening complications like facial paralysis, suppurative labyrinthitis, lateral sinus thrombophlebitis, meningitis, epidural and subdural abscess, brain abscess, and otitic hydrocephalus. The decision to perform diagnostic imaging in acute mastoiditis is based on the clinical presentation of the individual patient, HRCT of the temporal bone with or without contrast-enhanced CT of the brain or contrast-enhanced MRI of the brain are suggested in complicated cases of acute mastoiditis, the latter especially to rule out intracranial complications.<sup>4</sup> Acute mastoiditis with subperiosteal abscess due to congenital or acquired cholesteatoma is managed by modified radical mastoidectomy aiming at the removal of disease and preservation of hearing status.<sup>1</sup> All uncomplicated acute mastoiditis are treated by adequate intravenous parenteral antibiotic coverage and myringotomy or in combination with needle aspiration or incision and drainage of subperiosteal abscess.<sup>4-6</sup> Simple mastoidectomy is reserved for non-responsive cases, unsuccessful subperiosteal abscess drainage or the presence of intracranial complications.<sup>5,6</sup> A long-term follow-up is mandatory after recovery from acute mastoiditis because of recurrent otitis media, development of cholesteatoma and hearing impairment.

**Contributors** AC: design, drafting the article. HV and JCS: acquisition of data, literature review. PS: conception, critical revisions, literature review. All were involved in the clinical care of the patient and read and approved the final version of the article.

**Funding** The authors have not declared a specific grant for this research from any funding agency in the public, commercial or not-for-profit sectors.

**Competing interests** None declared.

**Patient consent for publication** Parental/guardian consent obtained.

**Provenance and peer review** Not commissioned; externally peer reviewed.

#### ORCID iDs

Aswin Chandran <http://orcid.org/0000-0003-3829-9872>

Hitesh Verma <http://orcid.org/0000-0001-7905-3073>

Pirabu Sakthivel <http://orcid.org/0000-0002-6941-9892>

#### REFERENCES

- Warren FM, Bennett ML, Wiggins RH, *et al.* Congenital cholesteatoma of the mastoid temporal bone. *Laryngoscope* 2007;117:1389–94.
- van den Aardweg MTA, Rovers MM, de Ru JA, *et al.* A systematic review of diagnostic criteria for acute mastoiditis in children. *Otol Neurotol* 2008;29:751–7.
- Abdelaziz AA, Sadek AA, Talaat M. Differential diagnosis of post auricular swelling with mastoid bone involvement. *Indian J Otolaryngol Head Neck Surg* 2019;71:1374–6.
- Bartov N, Lahav Y, Lahav G, *et al.* Management of acute mastoiditis with immediate needle aspiration for subperiosteal abscess. *Otol Neurotol* 2019;40:e612–8.
- Psarommatis IM, Voudouris C, Douros K, *et al.* Algorithmic management of pediatric acute mastoiditis. *Int J Pediatr Otorhinolaryngol* 2012;76:791–6.
- Anne S, Schwartz S, Ishman SL, *et al.* Medical versus surgical treatment of pediatric acute mastoiditis: a systematic review. *Laryngoscope* 2019;129:754–60.

Copyright 2020 BMJ Publishing Group. All rights reserved. For permission to reuse any of this content visit <https://www.bmj.com/company/products-services/rights-and-licensing/permissions/>  
BMJ Case Report Fellows may re-use this article for personal use and teaching without any further permission.

Become a Fellow of BMJ Case Reports today and you can:

- ▶ Submit as many cases as you like
- ▶ Enjoy fast sympathetic peer review and rapid publication of accepted articles
- ▶ Access all the published articles
- ▶ Re-use any of the published material for personal use and teaching without further permission

#### Customer Service

If you have any further queries about your subscription, please contact our customer services team on +44 (0) 207111 1105 or via email at [support@bmj.com](mailto:support@bmj.com).

Visit [casereports.bmj.com](http://casereports.bmj.com) for more articles like this and to become a Fellow