Large preaxial polydactyly with intraepidermal bulla: an unusual form of polydactyly

Jia Deng,[1] Pooja Agarwal Jayagobi,[2] Wen Quan Derrick Lian,[3] Suresh Chandran[4,5,6,7]

[1]Yong Loo Lin School of Medicine, National University of Singapore, Singapore
[2]Department of Neonatology, KK Women's and Children's Hospital, Singapore
[3]Department of Pathology and Laboratory Medicine, KK Women's and Children's Hospital, Singapore
[4]Department of Neonatology, KK Women's and Children's Hospital, Singapore
[5]NUS, Yong Loo Lin School of Medicine, Singapore
[6]Duke - NUS Medical School, Singapore
[7]Lee Kong Chian School of Medicine, Singapore

Correspondence to
Professor Suresh Chandran, schandran1312@yahoo.co.uk

Accepted 12 December 2018

DESCRIPTION

Polydactyly is a condition in which the supernumerary digits or duplications of digital parts manifest either as an integral part or in association with ~300 well-defined syndromes. Polydactyly is the most frequently observed congenital limb anomaly at birth. The reported incidence of polydactyly ranges from 0.3 to 3.6/1000 live births, where males are twice more likely to be affected than females.[1] Polydactyly can be classified into preaxial (PPD, radial), postaxial (ulnar) and central. Temtamy and McKusick[2] has defined four types of PPDs: PPD-I, duplication of one or more skeletal components of a biphalangeal thumb; PPD-II, polydactyly of a triphalangeal thumb; PPD-III, polydactyly of an index finger; and PPD-IV, a polysyndactyly. Wassel[3] further subdivided PPD-I into six subtypes according to its depth of osseous duplication.[4] However, some types of thumb duplication cannot be classified based on these criteria. Polydactyly cases vary from a small, raised bump to a complete finger. In most cases, it is smaller than the other digits and not well formed. The extra digit is sometimes the only skin that connects to the hand or foot with only a narrow stalk of tissue. If the digit is better formed, it may consist of bone, muscles, blood vessels and nerves. Here, we present an unusual case of a large PPD with intraepidermal bulla.

A male infant was born at 37 weeks with a birth weight of 3452 g. He was diagnosed with left hand PPD measuring 2.5×1.8×1.5 cm, with the cystic area of the skin at 1.6×1.5×0.8 cm. There was a generous soft tissue pedicle and a superficial bulla, with no other bony deformities (figure 1). At 4 hours of life, an X-ray of the left hand showed a large pedunculated soft tissue mass arising from the radial aspect of the left thumb base without any osseous elements (figure 2). A division of the polydactyly with cyst was done under local anaesthesia (figure 3). Histopathological examination (figure 4) showed a polypoidal piece of fibrovascular tissue covered with skin and intraepidermal bulla, with no central core of bone or cartilage.

Unlike the better formed polydactyly that typically has similar anatomy and histology of a finger, our patient was diagnosed with PPD without osseous element, but with an intraepidermal bulla. Ochi *et al* reported a similar neonatal case with a preaxial grossly oedematous

Figure 2 X-ray of the left hand with a large pedunculated soft tissue mass arising from the radial aspect of the left thumb base with no osseous elements.

Figure 1 Preaxial polydactyly of the left hand with intraepidermal bulla.

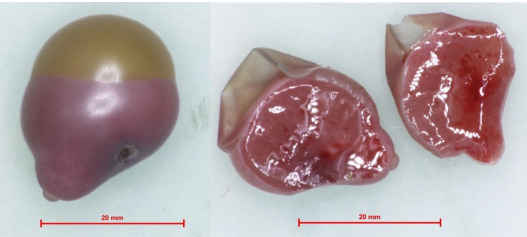

Figure 3 Gross images of the specimen and the cut surfaces.

To cite: Deng J, Agarwal Jayagobi P, Lian WQD, *et al*. *BMJ Case Rep* 2019;**12**:e228183. doi:10.1136/bcr-2018-228183

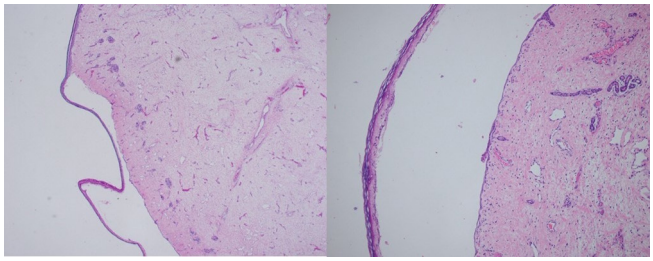

Figure 4 Low-power and high-power views of the histology, showing fibrovascular tissue covered by skin and the presence of an intraepidermal bulla.

appendage on the radial aspect of the left thumb.[5] In this case, there was a marked interstitial oedema in its connective tissue with cartilage, neuron and other elements. They reported it as 'Pacifier PPD' since it fulfilled the definition of a large oedematous digital duplication attached by a soft tissue-stalk.[5] Pacifier polydactyly was originally described in postaxial polydactyly.[6] The histology of our reported case did not show gross oedema. Therefore, it cannot be classified as Pacifier PPD.

Since blunt amputation by ligation may result in amputation neuroma, sharp resection is usually recommended for PPD treatment.[5] We used a similar approach in our case and showed that stalk resection with a curved iris scissors following diathermy resulted in positive outcomes without the formation of rudimentary polydactyly.

In conclusion, our PPD case has a fibrovascular mass and an intraepidermal bulla that has never been reported. Although the genetics of this case has not been studied, it may represent a stochastic developmental error caused by sequence variants in the sonic hedgehog enhancer, called zone of polarising activity regulatory sequence.[7]

Learning points

- Polydactyly is the most frequently observed congenital limb anomaly at birth.
- Preaxial polydactyly can be presented as a cystic lesion containing serous fluid with polypoidal piece of fibrovascular tissue covered by skin with an intraepidermal bulla.
- Sharp resection of the preaxial polydactyly remains a recommended treatment that will not result in the formation of rudimentary polydactyly.

Acknowledgements We would like to thank Dr Eddy Saputra Leman, PhD, Sr Scientific Editor, Duke-NUS Medical School, Singapore for editing the manuscript.

Contributors JD: manuscript preparation and review of literature. WQDL: pathology report and review of manuscript. PAJ and SC: manuscript preparation and finalisation of the manuscript.

Funding The authors have not declared a specific grant for this research from any funding agency in the public, commercial or not-for-profit sectors.

Competing interests None declared.

Patient consent Parental/guardian consent obtained.

Provenance and peer review Not commissioned; externally peer reviewed.

REFERENCES

1 Malik S. Polydactyly: phenotypes, genetics and classification. *Clin Genet* 2014;85:203–12.
2 Temtamy SA, McKusick VA. The genetics of hand malformations. *Birth Defects Orig Artic Ser* 1978;14:1–28.
3 Wassel HD. The results of surgery for polydactyly of the thumb. A review. *Clin Orthop Relat Res* 1969;64:175–93.
4 Zguricas J, Heus H, Morales-Peralta E, *et al*. Clinical and genetic studies on 12 preaxial polydactyly families and refinement of the localisation of the gene responsible to a 1.9 cM region on chromosome 7q36. *J Med Genet* 1999;36:32–40.
5 Ochi K, Horiuchi Y, Takayama S, *et al*. Duplicated thumb with enormous soft-tissue oedema - pacifier type of thumb duplication. *Hand Surg* 2011;16:91–3.
6 Kanter WR, Upton J. "Pacifier polydactyly": a transitional form between pedunculated polydactyly and rudimentary polydactyly. *Plast Reconstr Surg* 1989;84:136–9.
7 Perez-Lopez LM, la Iglesia DG, Cabrera-Gonzalez M. Radial polydactyly. what's new? *Curr Pediatr Rev* 2018;14:91–6.