

# When things are not quite what they seem!

Wern Yew Ding,<sup>1,2</sup> Khaled Albouaini,<sup>1</sup> Simon Modi<sup>1</sup>

<sup>1</sup>Department of Cardiology, Liverpool Heart and Chest Hospital, Liverpool, Merseyside, UK

<sup>2</sup>University of Liverpool, Liverpool, UK

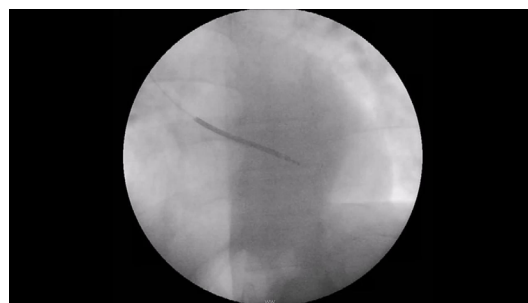## Correspondence to

Dr Wern Yew Ding, wding@nhs.net

Accepted 9 October 2018

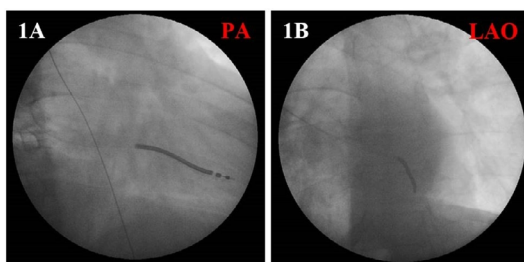
## DESCRIPTION

A 61-year-old man presented with recurrent presyncope, 12-lead ECG and echocardiographic features of a right ventricular (RV) cardiomyopathy, and non-sustained ventricular tachycardia on Holter monitoring. During defibrillator implant for presumed arrhythmogenic RV cardiomyopathy, ventricular pacing parameters were satisfactory and the following images were obtained (figure 1). The implantable cardioverter defibrillator lead appeared well sited in the RV apex on posterior-anterior fluoroscopy (figure 1A). However, screening in the left anterior oblique (LAO) projection raised doubts about the true lead position (figure 1B). On-table echocardiography and 12-lead ECG confirmed lead placement within the left ventricle (LV). Pullback of the lead, while screening, suggested passage to the systemic circulation via an atrial septal defect (ASD; figure 2A–D and video 1). Attempts to reposition the lead by advancing it from the superior vena cava (SVC) revealed an anomalous connection to a right pulmonary vein (figure 2E). The lead was eventually placed within the RV apex (figure 2F,G). Prior MRI imaging commented on the suspicion of

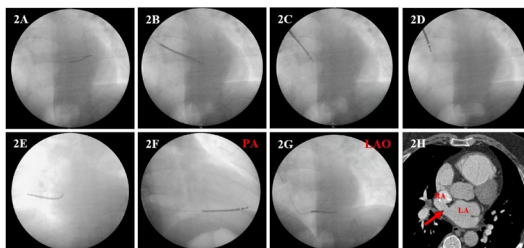


**Video 1** Pullback of implantable cardioverter defibrillator (ICD) lead during screening demonstrates passage of the lead to the systemic circulation via an atrial septal defect.

a connection between the right and left heart, and possible ASD. The ventricular measurements were: RV ejection fraction (EF) of 48% (range 49%–73%), indexed RV end-diastolic volume (EDV) of 124 mL/m<sup>2</sup> (range 67–111 mL/m<sup>2</sup>), indexed RV end-systolic volume (ESV) of 63 mL/m<sup>2</sup> (range 20–48 mL/m<sup>2</sup>); LVEF of 55% (range 59%–83%), indexed LVEDV of 83 mL/m<sup>2</sup> (range 53–97 mL/m<sup>2</sup>), indexed LVESV of 38 mL/m<sup>2</sup> (range 10–34 mL/m<sup>2</sup>). Subsequent CT with contrast confirmed the presence of partial anomalous pulmonary venous drainage of the right upper and middle pulmonary veins into the SVC and superior sinus venosus defect (figure 2H). Our patient subsequently underwent successful surgical patch repair of his superior sinus venosus defect and baffling of the right upper and middle pulmonary veins to the left atrium. The overall incidence of partial anomalous pulmonary venous drainage is approximately 0.5%.<sup>1</sup> About 80% of patients with the condition have concomitant ASD,<sup>2</sup> most commonly with sinus venosus defect near the SVC orifice.<sup>3</sup> This case reinforces the importance of



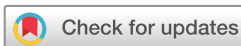**Figure 1** Fluoroscopy of implantable cardioverter defibrillator (ICD) lead in posterior-anterior (PA) (A) and left anterior oblique (LAO) (B) projections.



**Figure 2** Fluoroscopy showing pullback of implantable cardioverter defibrillator (ICD) lead (A–D); anomalous right pulmonary vein connection to the superior vena cava (SVC) (E); repositioning of ICD lead in the right ventricular (RV) apex (F, G); CT with contrast showing superior sinus venosus defect (red arrow, H). LA, left atrium; LAO, left anterior oblique; PA, posterior-anterior; RA, right atrium.

## Learning points

- ▶ It is important to adopt a meticulous approach during implantable cardioverter defibrillator (ICD) insertion and lead positioning should be confirmed using both posterior-anterior and left anterior oblique projections on fluoroscopy.
- ▶ If in doubt about the ICD lead position despite fluoroscopy, other methods should be employed such as 12-lead ECG and on-table echocardiography.
- ▶ Remember to assess for possible intracardiac shunts in patients who present with suspected right ventricular cardiomyopathies, including detailed assessment of any prior cardiac imaging.



© BMJ Publishing Group Limited 2018. No commercial re-use. See rights and permissions. Published by BMJ.

**To cite:** Ding WY, Albouaini K, Modi S. *BMJ Case Rep* Published Online First: [please include Day Month Year]. doi:10.1136/bcr-2018-226118

accounting for possible intracardiac shunts with suspected RV cardiomyopathies and for detailed assessment of this during cardiac imaging. In addition, it highlights the relevance of screening in the LAO projection for RV apical lead positioning.

**Contributors** WYD collected the data and drafted the manuscript. SM and KA critically revised the manuscript. Final approval of the manuscript was agreed upon by all authors.

**Funding** The authors have not declared a specific grant for this research from any funding agency in the public, commercial or not-for-profit sectors.

**Competing interests** None declared.

**Patient consent** Obtained.

**Provenance and peer review** Not commissioned; externally peer reviewed.

## REFERENCES

- 1 Demos TC, Posniak HV, Pierce KL, *et al*. Venous anomalies of the thorax. *AJR Am J Roentgenol* 2004;182:1139–50.
- 2 Gustafson RA, Warden HE, Murray GF, *et al*. Partial anomalous pulmonary venous connection to the right side of the heart. *J Thorac Cardiovasc Surg* 1989;98(5 Pt 2):861–8.
- 3 Oliver JM, Gallego P, Gonzalez A, *et al*. Sinus venosus syndrome: atrial septal defect or anomalous venous connection? A multiplane transoesophageal approach. *Heart* 2002;88:634–8.

Copyright 2018 BMJ Publishing Group. All rights reserved. For permission to reuse any of this content visit <http://group.bmj.com/group/rights-licensing/permissions>.

BMJ Case Report Fellows may re-use this article for personal use and teaching without any further permission.

Become a Fellow of BMJ Case Reports today and you can:

- ▶ Submit as many cases as you like
- ▶ Enjoy fast sympathetic peer review and rapid publication of accepted articles
- ▶ Access all the published articles
- ▶ Re-use any of the published material for personal use and teaching without further permission

For information on Institutional Fellowships contact [consortiasales@bmjgroup.com](mailto:consortiasales@bmjgroup.com)

Visit [casereports.bmj.com](http://casereports.bmj.com) for more articles like this and to become a Fellow