

# Fever of unknown origin due to primary tubercular splenic abscess in a low-income/middle-income country

Jasmine Sethi,<sup>1</sup> Abhinav Shrivastava,<sup>2</sup> Krishan Lal Gupta<sup>1</sup>

<sup>1</sup>Nephrology, Postgraduate Institute of Medical Education and Research, Chandigarh, Punjab, India

<sup>2</sup>Internal Medicine, Postgraduate Institute of Medical Education and Research, Chandigarh, Punjab, India

## Correspondence to

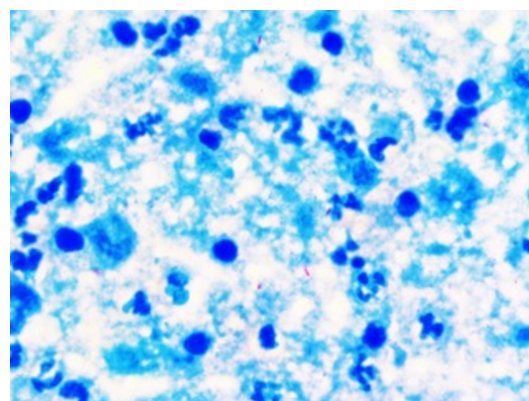
Professor Krishan Lal Gupta, klgupta@hotmail.com

Accepted 1 August 2018

## DESCRIPTION

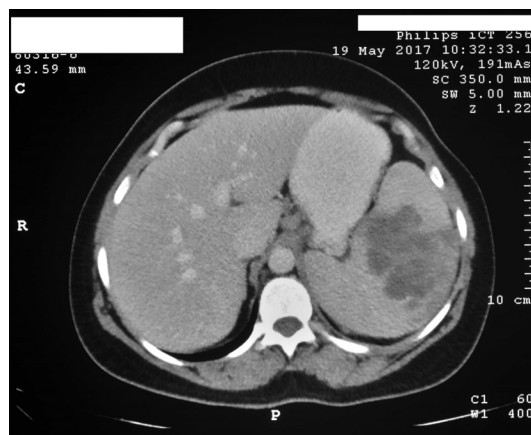A 49-year-old non-diabetic woman was admitted to our hospital with complaints of fever of unknown origin (FUO) of 2 months' duration. The patient has no recent history of exposure to tuberculosis (TB). Systemic examination revealed pallor and tender splenomegaly. Blood investigations revealed a microcytic hypochromic anaemia with haemoglobin of 7.5 g/dL, total leucocyte count of  $12.7 \times 10^9/L$  and a raised erythrocyte sedimentation rate (ESR) (62 mm/hour). The rest of the FUO work-up, including blood cultures, serologies, chest radiograph, Mantoux and echocardiography, was unremarkable. Contrast-enhanced CT of the abdomen revealed multiple splenic abscesses (figure 1), from which a diagnostic and therapeutic single time aspiration was done. Around 10 mL of pus was aspirated which showed smear positivity for *Mycobacterium tuberculosis* (figure 2). The patient was subsequently started on four-drug antitubercular treatment. The fever subsided and repeat serial ultrasound imaging showed resolution of splenic abscess. Primary splenic TB in an immunocompetent patient is a rare entity but should be considered as a diagnostic possibility especially in a country where TB is endemic.

Splenic abscess has a very low incidence (0.1%–0.7% on autopsy) and tubercular splenic abscess is even rarer.<sup>1</sup> Usually spleen is involved in disseminated TB, and primary splenic TB is extremely uncommon with only few cases published in the literature.<sup>1–4</sup> Splenic abscess is mostly seen in patients with underlying immunocompromised



**Figure 2** Smear from pus aspirated from splenic abscess showing degenerated neutrophils, macrophages in a background of necrosis and stained positive for acid-fast bacilli.

state, which includes diabetes, transplant recipients, intravenous drug abuse and retroactivity.<sup>1</sup> It is most commonly caused by Gram-negative organisms, with *Klebsiella* as the most commonly isolated organism.<sup>5</sup> CT differentials of the splenic abscess include splenic lymphoma, metastasis, parasitic cyst, infarction, haemangioma, sarcoidosis and trauma. Differentiating tubercular from pyogenic splenic abscess on CT can sometimes be difficult; however, unilocular abscess, rim enhancement and gas formation within the lesion favour pyogenic abscess.<sup>6</sup> Treatment consists of antitubercular therapy and spleen-saving surgery such as percutaneous single time aspiration.<sup>5</sup> The above case is presented because of the rarity of occurrence of primary splenic TB and its successful management with single time splenic aspiration and antitubercular drugs.

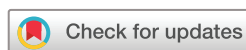

**Figure 1** CT scan of the abdomen showing multiple conglomerating hypodense lesions in the splenic parenchyma suggestive of abscesses.

## Learning points

- ▶ Splenic tuberculosis should be considered in patients with fever of unknown origin and splenomegaly especially in our country where tuberculosis is endemic.
- ▶ Ultrasonography of the abdomen can be a useful and cost-effective mode to suspect this rare entity.

**Contributors** JS and AS: writing, concept, image acquisition. KLG: proof-reading, corrections.



© BMJ Publishing Group Limited 2018. No commercial re-use. See rights and permissions. Published by BMJ.

**To cite:** Sethi J, Shrivastava A, Gupta KL. *BMJ Case Rep* Published Online First: [please include Day Month Year]. doi:10.1136/bcr-2018-225990

**Funding** The authors have not declared a specific grant for this research from any funding agency in the public, commercial or not-for-profit sectors.

**Competing interests** None declared.

**Patient consent** Obtained.

**Provenance and peer review** Not commissioned; externally peer reviewed.

## REFERENCES

- 1 Agarwala S, Bhatnagar V, Mitra DK, *et al.* Primary tubercular abscess of the spleen. *J Pediatr Surg* 1992;27:1580–1.
- 2 Kumar S, Pai AG, Tungenwar PN, *et al.* Isolated primary tuberculosis of spleen-A rare entity in the immuno-competent patient. *Int J Surg Case Rep* 2017;30:93–6.
- 3 Hamizah R, Rohana AG, Anwar SA, *et al.* Splenic tuberculosis presenting as pyrexia of unknown origin. *Med J Malaysia* 2007;62:70–1.
- 4 Neki NS, Batra KS, Sharma RK, *et al.* Isolated tubercular splenic abscess. *J Assoc Physicians India* 2001;49:759–60.
- 5 Chang KC, Chuah SK, Changchien CS, *et al.* Clinical characteristics and prognostic factors of splenic abscess: a review of 67 cases in a single medical center of Taiwan. *World J Gastroenterol* 2006;12:460–4.
- 6 Karlo CA, Stolzmann P, Do RK, *et al.* Computed tomography of the spleen: how to interpret the hypodense lesion. *Insights Imaging* 2013;4:65–76.

Copyright 2018 BMJ Publishing Group. All rights reserved. For permission to reuse any of this content visit <http://group.bmj.com/group/rights-licensing/permissions>.  
BMJ Case Report Fellows may re-use this article for personal use and teaching without any further permission.

Become a Fellow of BMJ Case Reports today and you can:

- Submit as many cases as you like
- Enjoy fast sympathetic peer review and rapid publication of accepted articles
- Access all the published articles
- Re-use any of the published material for personal use and teaching without further permission

For information on Institutional Fellowships contact [consortiasales@bmjgroup.com](mailto:consortiasales@bmjgroup.com)

Visit [casereports.bmj.com](http://casereports.bmj.com) for more articles like this and to become a Fellow