

# Sebaceous adenitis of the vulva responsive to antiandrogens

Delwyn Dyall-Smith,<sup>1</sup> James Scurry<sup>2,3</sup>

<sup>1</sup>Riverina Dermatology, Wagga Wagga, New South Wales, Australia

<sup>2</sup>Pathology North, Newcastle, New South Wales, Australia

<sup>3</sup>Faculty of Health and Medicine, University of Newcastle, Newcastle, New South Wales, Australia

**Correspondence to**  
Dr Delwyn Dyall-Smith,  
delwynds@gmail.com

Accepted 15 May 2018

## DESCRIPTION

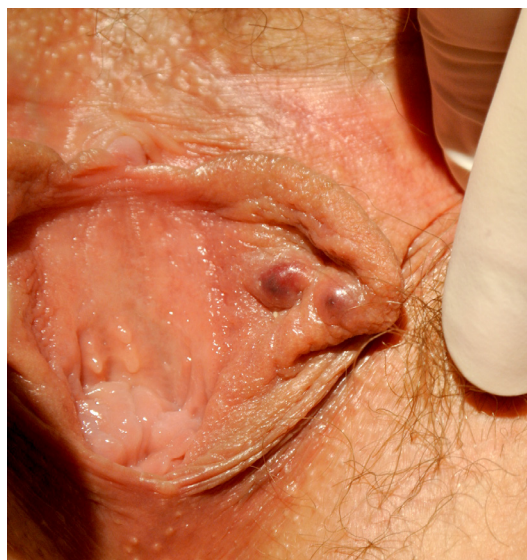Sebaceous adenitis is an inflammatory dermatosis most commonly reported in animals. There have been rare reports in humans, mostly on the face and chest, with possible aetiological factors proposed including photodermatitis and Demodex mite. A hormone-response form of sebaceous adenitis occurring on the vulvar labia minora, clinically resembling hidradenitis suppurativa, has been postulated to be an unrelated and distinct condition.<sup>1,2</sup>

A 37-year-old woman presented with a 10-year history of intermittent, sometimes painful, labial cysts. These could resolve spontaneously or rupture. There was no obvious relationship to her menstrual cycle, but sometimes cysts became apparent after sexual intercourse. No treatment had been tried.

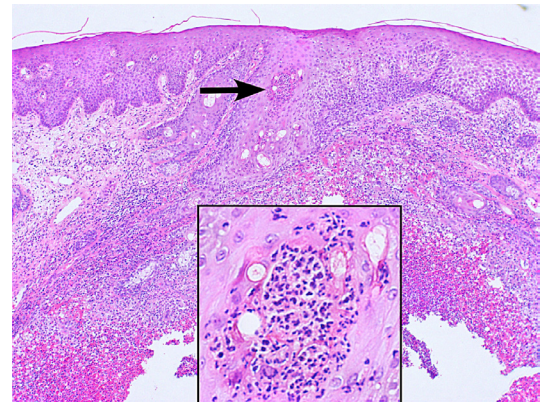
On examination, there were three firm smooth cysts on the inner mucosal aspect of the left labium minorum (figure 1). No surface change was visible.

One cyst was excised. The specimen of hairless skin showed a superficial dermal abscess centred on a sebaceous gland (figure 2). A sebaceous lobule in the wall of the abscess contained a pustule. Epithelial membrane antigen was positive in sebaceous epithelium on immunoperoxidase stain. No Gram-positive bacteria were seen in a Gram stain, and no yeast or fungi were seen on a periodic acid-schiff (PAS). A pathological diagnosis of sebaceous adenitis was made.

An antiandrogenic contraceptive pill/oral contraceptives (cyproterone acetate 2000 µg,



**Figure 1** Clinical: two smooth bluish cysts on the inner aspect of the left labium minorum.



**Figure 2** Histology: heavy perisebaceous and periadnexal inflammation. Arrow indicates inflammation directed against sebaceous glands.

ethinylestradiol 35 µg) was prescribed, and in the subsequent 6 months of treatment, no further cysts had developed.

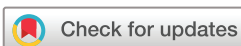Vulvar sebaceous adenitis has been reported as a chronic relapsing condition, often over many years, in premenopausal adult women, typically with luteal phase exacerbation and resolution with the onset of menstrual flow. It is characterised by recurrent tender papules or nodules localised in the mucosal inner aspect of the labia minor. The nodules may discharge pus, swabs of which are typically negative for pathogens. In many cases, topical and oral corticosteroids, antiherpetics, antibiotics and anticandidal medications have been trialled unsuccessfully. However, in all reported cases, there has been an excellent response to oral tetracyclines

## Patient's perspective

I have been living with this uncomfortable condition for as long as I can remember. Finally seeing the right doctor and getting a real diagnosis that was so easily fixed feels like a miracle. The results were clear within a week and within a month, completely disappeared.

## Learning points

- ▶ Sebaceous adenitis of the vulva has been rarely reported and is probably distinct from the facial/truncal form.
- ▶ Sebaceous adenitis of the vulva responds well to antiandrogens or tetracyclines, so it is an important diagnosis to consider.



**To cite:** Dyall-Smith D, Scurry J. *BMJ Case Rep* Published Online First: [please include Day Month Year]. doi:10.1136/bcr-2018-225655

(usually minocycline) or antiandrogen therapy such as spironolactone or cyproterone acetate.<sup>1,2</sup>

**Contributors** DD-S was the dermatologist who cared for the patient. JS was the pathologist who made the diagnosis on biopsy.

**Funding** The authors have not declared a specific grant for this research from any funding agency in the public, commercial or not-for-profit sectors.

**Competing interests** None declared.

**Patient consent** Obtained.

**Provenance and peer review** Not commissioned; externally peer reviewed.

© BMJ Publishing Group Ltd (unless otherwise stated in the text of the article) 2018. All rights reserved. No commercial use is permitted unless otherwise expressly granted.

## REFERENCES

- 1 Dixit S, Olsson A, Fischer G. A case series of 11 patients with hormone-responsive sebaceous adenitis of the labia minora. *Australas J Dermatol* 2014;55:80–3.
- 2 Tohyama M, Matsumoto K, Sayama K. Two cases of genital neutrophilic sebaceous adenitis. *J Dermatol* 2016;43:1221–3.

Copyright 2018 BMJ Publishing Group. All rights reserved. For permission to reuse any of this content visit <http://group.bmj.com/group/rights-licensing/permissions>.  
BMJ Case Report Fellows may re-use this article for personal use and teaching without any further permission.

Become a Fellow of BMJ Case Reports today and you can:

- ▶ Submit as many cases as you like
- ▶ Enjoy fast sympathetic peer review and rapid publication of accepted articles
- ▶ Access all the published articles
- ▶ Re-use any of the published material for personal use and teaching without further permission

For information on Institutional Fellowships contact [consortiasales@bmjgroup.com](mailto:consortiasales@bmjgroup.com)

Visit [casereports.bmj.com](http://casereports.bmj.com) for more articles like this and to become a Fellow