

Unusual case of hypocalcaemia

Vinuta Mohan,¹ Rishitha Yelisetti,² Robert Lind³

¹Department of Endocrinology, Saint Francis Medical Center, Trenton, New Jersey, USA

²Department of Internal Medicine, Saint Francis Medical Center, Trenton, New Jersey, USA

³Department of Endocrinology, Hunterdon Medical Center, Flemington, New Jersey, USA

Correspondence to

Dr Vinuta Mohan,
vmohan@stfrancismedical.org

Accepted 11 May 2018

DESCRIPTION

A 33-year-old woman presented with 1 week of dizziness and bilateral leg and hand cramps with associated numbness and tingling. She stated she was diagnosed with hypocalcaemia when she was approximately 8 years old, but could not elaborate further. She was a poor historian with learning disabilities and admittedly was non-compliant with treatment.

Physical examination revealed a round face, short stature (4'10") and obesity (body mass index 39) with no neck scars. Her extremities were notable brachydactyly of her feet (figure 1) as well as brachydactyly of her fourth and fifth fingers (figure 2) with a positive Archibald's sign (figure 3). X-ray of her hands was significant for shortening of the fourth and fifth metacarpals (figure 4). EKG was remarkable for prolonged QT interval (figure 5). Brain CT revealed extensive calcification in the basal ganglia (figure 6), consistent with chronic hypocalcaemia.

Her lab tests were remarkable for calcium of 5.7 mg/dL (8.6–10), phosphorus of 5.3 mg/dL (2.7–4.5) and magnesium of 1.5 mg/dL (1.5–2.6). 25-hydroxy vitamin D was 28 ng/mL (30–100), blood urea nitrogen was 11 mg/dL (6–20) and creatinine was 0.88 mg/dL (0.5–0.9). Thyroid Stimulating Hormone (TSH) was 3.73 U/mL (0.3–4). Parathyroid hormone (PTH) was markedly elevated at 192 pg/mL (14–64) and the diagnosis of pseudohypoparathyroidism (PHP) was made. She was started on intravenous and

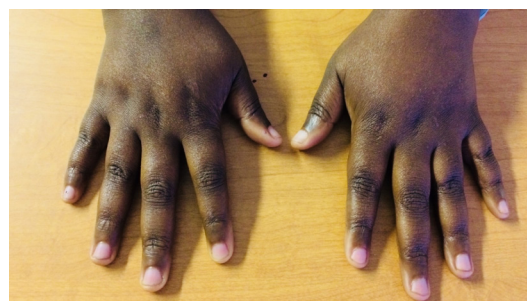

Figure 2 Brachydactyly of the fourth and fifth digits.

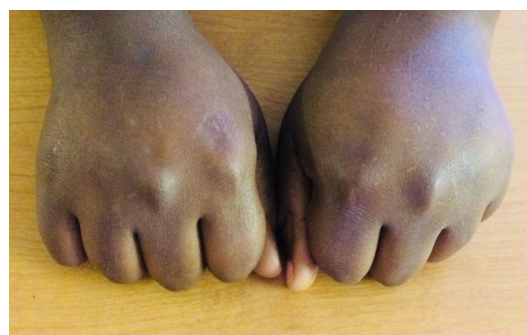

Figure 3 Archibald's sign (absence of the fourth and fifth knuckles on clenched fists).

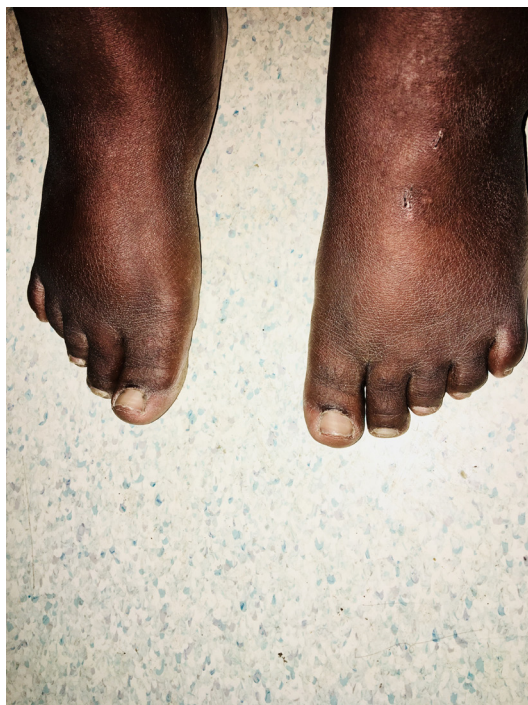

Figure 1 Brachydactyly of the feet.

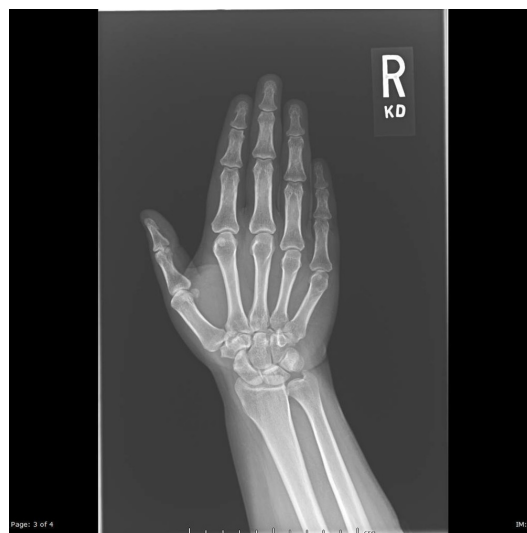
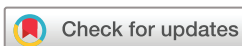
Figure 4 X-ray of hand showing shortening of fourth and fifth metatarsals.

oral calcium and calcitriol with improvement of her serum calcium and symptoms.

PHP is an extremely rare cause of hypocalcaemia, with an incidence of 0.79 per 100 patients and is more common in females than males. It is caused by defects of the *GNAS1* gene which lead to PTH



To cite: Mohan V, Yelisetti R, Lind R. *BMJ Case Rep* Published Online First: [please include Day Month Year]. doi:10.1136/bcr-2018-225452

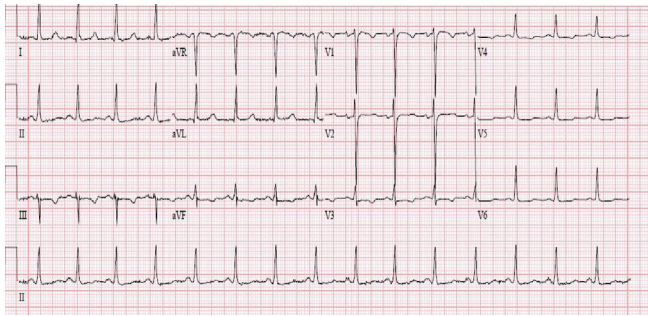


Figure 5 EKG demonstrating prolonged QT interval.

resistance. When PHP is present with clinical features consistent with Albright's hereditary osteodystrophy such as round facies, obesity, short stature, brachydactyly and intellectual deficiencies, the patient is classified as PHP1a. These patients

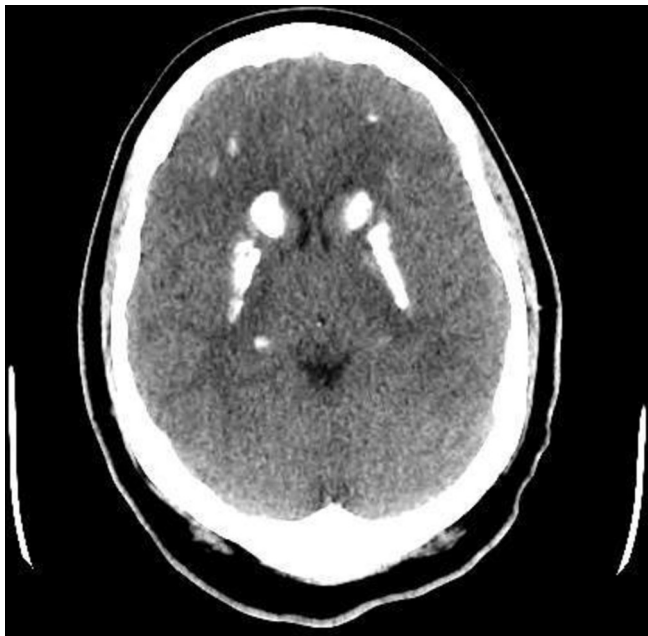

Figure 6 CT of brain showing extensive basal ganglia calcifications.

may develop resistance to other hormones such as thyroid stimulating hormone and gonadotropins, so periodic screening is important. The mainstay of treatment for patients with PHP1a is to correct and prevent complications from hypocalcaemia with oral calcium and 1 α -hydroxylated vitamin D metabolites.^{1,2}

Learning points

- ▶ Pseudohypoparathyroidism (PHP) is an extremely rare disease associated with hypocalcaemia and hyperphosphataemia, with elevated parathyroid hormone and normal renal function.
- ▶ Patients with PHP1a have round facies, short stature, central obesity, subcutaneous calcifications, brachydactyly and mental deficiencies which are features of Albright's Hereditary Osteodystrophy.
- ▶ The long-term treatment for patients with PHP1a involves maintaining normal serum calcium values with calcium and active vitamin D metabolites, and also regular screening for other associated hormone resistance conditions such as hypothyroidism and hypogonadism.

Acknowledgements The authors would like to acknowledge Dr Sara Wallach, Chief and Chairperson of the Department of Medicine at Saint Francis Medical Center, Trenton, New Jersey, USA for her support of the Department of Endocrinology at our institution.

Contributors VM is the primary author of the paper. VM, RL and RY reviewed all the literature and images and edited the original manuscript to prepare for submission.

Funding The authors have not declared a specific grant for this research from any funding agency in the public, commercial or not-for-profit sectors.

Competing interests None declared.

Patient consent Obtained.

Provenance and peer review Not commissioned; externally peer reviewed.

© BMJ Publishing Group Ltd (unless otherwise stated in the text of the article) 2018. All rights reserved. No commercial use is permitted unless otherwise expressly granted.

REFERENCES

- 1 Lemos MC, Thakker RV. GNAS mutations in Pseudohypoparathyroidism type 1a and related disorders. *Hum Mutat* 2015;36:11–19.
- 2 Mantovani G. Pseudohypoparathyroidism: Diagnosis and Treatment. *Int J Clin Endocrinol Metab* 2011;96:3020–30.

Copyright 2018 BMJ Publishing Group. All rights reserved. For permission to reuse any of this content visit <http://group.bmj.com/group/rights-licensing/permissions>.

BMJ Case Report Fellows may re-use this article for personal use and teaching without any further permission.

Become a Fellow of BMJ Case Reports today and you can:

- ▶ Submit as many cases as you like
- ▶ Enjoy fast sympathetic peer review and rapid publication of accepted articles
- ▶ Access all the published articles
- ▶ Re-use any of the published material for personal use and teaching without further permission

For information on Institutional Fellowships contact consortiasales@bmjgroup.com

Visit casereports.bmj.com for more articles like this and to become a Fellow