

# Management of complete tracheal rings in a neonate with tetralogy of Fallot

Jonathon Nelson,<sup>1</sup> Hoyon Lee,<sup>1</sup> Pranava Sinha,<sup>2</sup> Nina Deutsch<sup>1</sup>

<sup>1</sup>Anesthesiology, Pain, and Perioperative Medicine, Children's National Health System, Washington, District of Columbia, USA

<sup>2</sup>Cardiovascular Surgery, Children's National Health System, Washington, District of Columbia, USA

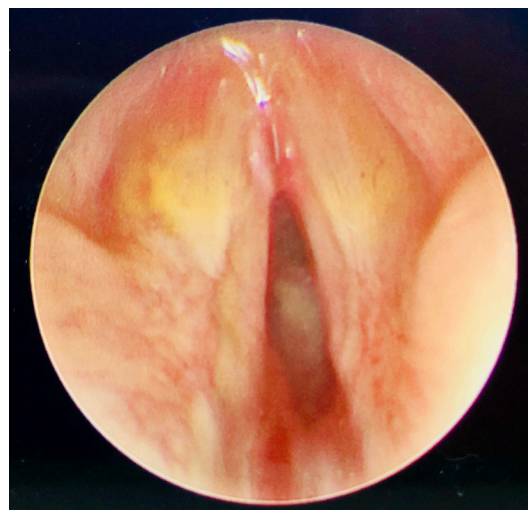Correspondence to  
Dr Nina Deutsch,  
ndeutsch@cnmc.org

Accepted 17 April 2018

## DESCRIPTION

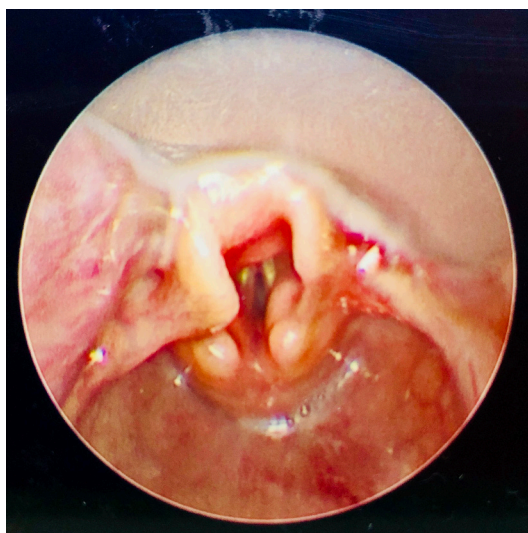
A 3-day-old full-term female infant was postnatally diagnosed with tetralogy of Fallot with severe subpulmonary and pulmonary valve obstruction, ventricular septal defect with right to left shunt and patent ductus arteriosus (PDA). She was stable on room air with an intravenous prostaglandin infusion while awaiting surgical repair. On day 3 of life, she was found unresponsive with significant desaturation to 30%. Following successful bag-mask ventilation and recovery of her saturation, multiple attempts to intubate the patient yielded a grade I view (figure 1). However, 3.0, 2.5 or 2.0 endotracheal tubes were unable to be passed due to an obstruction immediately distal to the vocal cords (figure 2). Mask ventilation was maintained without difficulty between each attempt. Transthoracic echocardiogram was performed at bedside in order to confirm adequate pulmonary blood flow through the PDA. The patient was transported to the operating room with mask ventilation for emergent direct laryngoscopy and bronchoscopy.

Otolaryngology was unable to insert a rigid 2.5 mm bronchoscope into the trachea though a 1.9 mm bronchoscope was able to be passed. Complete tracheal rings were seen immediately distal to the vocal cords down to carina (figure 3). The surgeon was also unable to intubate the patient with a 2.0 endotracheal tube. Tracheostomy was not an option due to complete tracheal rings throughout the entire length of the trachea; therefore, the airway was temporised with a laryngeal

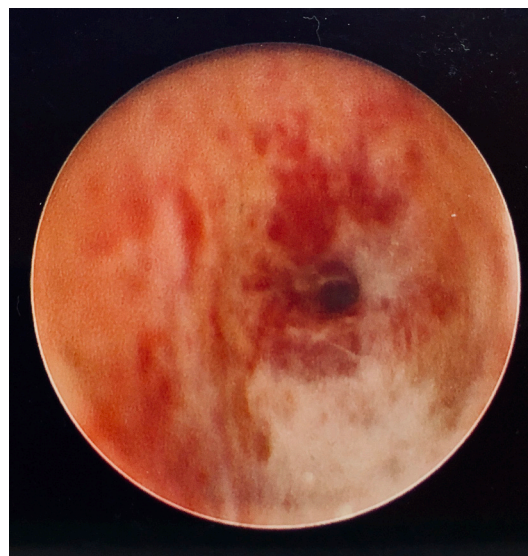


**Figure 2** Obstructive tissue can be visualised beyond the vocal cords.

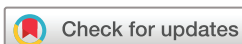mask airway to maintain ventilation. With no other options for a more definitive airway, the cardiac surgeon cannulated the patient's right internal jugular vein and carotid artery for arteriovenous extracorporeal membrane oxygenation (ECMO). To prevent fluid overload to the lungs, the arterial cannula was inserted with the tip in the descending aorta to minimise flow through the PDA, and the prostaglandin drip was discontinued. Two days



**Figure 1** Normal vocal cords are visualised on direct laryngoscopy.



**Figure 3** The severity of the complete tracheal rings is indicated by airway narrowing to less than 1.9 mm in diameter.



**To cite:** Nelson J, Lee H, Sinha P, et al. *BMJ Case Rep* Published Online First: [please include Day Month Year]. doi:10.1136/bcr-2018-225392

## Images in...

later, the patient was taken to the operating room for complete repair of her tetralogy of Fallot and slide tracheoplasty on cardiopulmonary bypass.

Oxygenation and ventilation were particularly concerning in this patient due to potential risk of tet spells triggered by hypoxia, hypercarbia and acidosis. In addition to complications of ECMO, including infection, bleeding and neurological injury, there were other factors to consider for this patient. First, in the setting of a PDA, ECMO would result in significant pulmonary overflow at the expense of systemic blood flow. By inserting the arterial cannula into the right common carotid artery and advancing it past the PDA to the descending aorta, the PDA could be bypassed and prostaglandin could be discontinued.

### Learning points

- ▶ Despite severe tracheal stenosis secondary to complete rings, adequate ventilation via mask or laryngeal mask airway may be possible while more definitive airway options are determined.
- ▶ Extracorporeal membrane oxygenation (ECMO) can be used successfully as a bridge to slide tracheoplasty or other tracheal reconstruction in patients who cannot be conventionally ventilated due to severe or long-segment stenosis.
- ▶ With ductal-dependent congenital heart disease, the implications of ECMO must be considered, and modifications in cannula placement may be necessary to best allow for adequate circulation.

Second, the patient would require cardiopulmonary bypass for the tetralogy of Fallot repair and slide tracheoplasty. Surgeons note improved surgical exposure and more precise surgical repair without an endotracheal tube obstructing the field.

Congenital tracheal anomalies usually present as respiratory distress, stridor or respiratory tract infections during the first days of life, but can be asymptomatic in some patients.<sup>1</sup> Long-segment tracheal stenosis can be life-threatening and can require emergent airway management with mechanical ventilation. If this is not possible prior to surgical repair, ECMO or stenting may be considered as temporising measures to oxygenate and ventilate.<sup>2</sup>

**Contributors** ND, JN, HL and PS were clinical providers for the patient presented in the manuscript. ND, JN and HL were responsible for the initial manuscript preparation and image acquisition. ND, JN, HL and PS all edited the manuscript. ND was responsible for preparing the manuscript and images for submission to journal. ND, JN, HL and PS approved the final manuscript.

**Funding** The authors have not declared a specific grant for this research from any funding agency in the public, commercial or not-for-profit sectors.

**Competing interests** None declared.

**Patient consent** Parental/guardian consent obtained.

**Provenance and peer review** Not commissioned; externally peer reviewed.

© BMJ Publishing Group Ltd (unless otherwise stated in the text of the article) 2018. All rights reserved. No commercial use is permitted unless otherwise expressly granted.

### REFERENCES

- 1 Schweiger C, Cohen AP, Rutter MJ. Tracheal and bronchial stenoses and other obstructive conditions. *J Thorac Dis* 2016;8:3369–78.
- 2 Kunisaki SM, Fauza DO, Craig N, *et al*. Extracorporeal membrane oxygenation as a bridge to definitive tracheal reconstruction in neonates. *J Pediatr Surg* 2008;43:800–4.

Copyright 2018 BMJ Publishing Group. All rights reserved. For permission to reuse any of this content visit <http://group.bmj.com/group/rights-licensing/permissions>.  
BMJ Case Report Fellows may re-use this article for personal use and teaching without any further permission.

Become a Fellow of BMJ Case Reports today and you can:

- ▶ Submit as many cases as you like
- ▶ Enjoy fast sympathetic peer review and rapid publication of accepted articles
- ▶ Access all the published articles
- ▶ Re-use any of the published material for personal use and teaching without further permission

For information on Institutional Fellowships contact [consortiasales@bmjgroup.com](mailto:consortiasales@bmjgroup.com)

Visit [casereports.bmj.com](http://casereports.bmj.com) for more articles like this and to become a Fellow