



OPEN ACCESS

CASE REPORT

Ureterosciatic hernia treated with ureteral stent placement

Yusuke Nakazawa, Nobuyo Morita, Ippei Chikazawa, Katsuhito Miyazawa

Urology, Kanazawa Medical University, Kahoku-gun, Japan

Correspondence to
Dr Yusuke Nakazawa,
nkzw-y@kanazawa-med.ac.jp

Accepted 19 April 2018

SUMMARY

A 92-year-old female with a history of asthma and chronic heart failure presented with left lumbar back pain. Physical examination revealed knocking tenderness at the left costal-vertebral angle. Laboratory test results were within normal limits. Abdominal CT showed a left hydroureteronephrosis and an obstruction of the left distal ureter with herniation into the sciatic foramen. A ureteral stent was inserted into the left ureter and was removed after 2 months. She has not complained of pain or showed symptoms since the removal. Our case suggests that doctors consider the possibility of ureterosciatic hernias when examining older patients complaining of lower back pain.

BACKGROUND

Ureteral herniation is uncommon, and its location in the sciatic foramen is also rare. CT is useful for diagnosing ureterosciatic hernias. We report a case of ureterosciatic herniation with left lumbar back pain and hydronephrosis, which was diagnosed with CT and treated with ureteral stent placement.

CASE PRESENTATION

A 92-year-old female was referred to the Department of Urology, Kanazawa Medical University Hospital due to left lumbar back pain. She had a history of asthma and chronic heart failure. She had no fever on arrival at the hospital. Physical examination revealed left costal-vertebral angle (CVA) knocking pain.

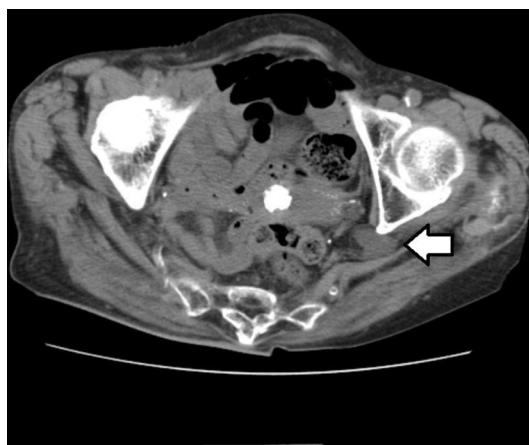


Figure 1 Abdominal CT showed a left distal ureter with herniation into the sciatic foramen. (arrow).

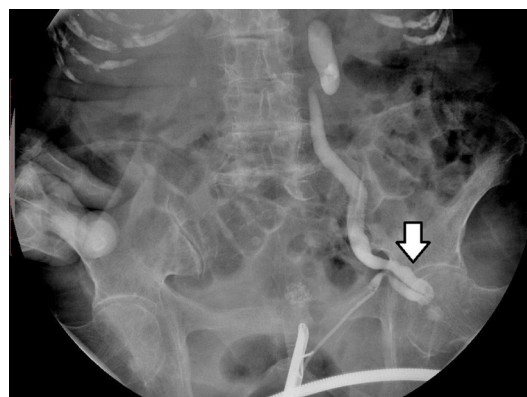


Figure 2 Retrograde ureterography reveals tortuosity of the left ureter. (arrow).

INVESTIGATIONS

Abdominal CT showed a left hydroureteronephrosis and obstruction of the left distal ureter with herniation into the sciatic foramen. (figure 1)

She underwent retrograde ureterography (RP), which showed definite tortuosity of the left ureter in the sciatic foramen. (figure 2)

TREATMENT

A guidewire was inserted into the left ureter and was linearized. A retro-grade placement of the 6Fr ureteral stent.

OUTCOME AND FOLLOW-UP

No recurrence of the ureterosciatic hernia was observed after the ureteral stent was removed at 12 month follow-up.

DISCUSSION

Cases of ureterosciatic hernias are uncommon. Indeed, only 30 cases have been reported previously.^{1,2} Ureterosciatic hernias are more likely to develop on the left side of elderly females because of their large pelvis and subsequent increase in abdominal pressure due to constipation and pregnancy.¹ Ureterosciatic hernias develop as a result of the loss of partial pelvic fascia, atrophy of the piriformis, adhesions, or congenital deformity. Radiographic studies, including intravenous urography (IVU) or RP, and CT are useful for diagnosis of ureterosciatic hernias.¹ IVU and RP showed an obstruction of the distal ureter with U-shaped tortuosity, known as a curlicue sign.³ The choice of treatment includes fixation of a ureter with surgery and placement of ureteral stents.¹ In this case the patient was elderly and had concurrent diseases.

Check for updates

To cite: Nakazawa Y, Morita N, Chikazawa I, et al. *BMJ Case Rep* Published Online First: [please include Day Month Year]. doi:10.1136/bcr-2017-222908

Therefore we selected placement of a ureteral stent. She has had no recurrence for 12 months after stent removal, and we consider this treatment to have been effective. However, there is potential for recurrence after stent removal. She needs to be monitored in the future and should be evaluated for surgical therapy at the time of recurrence.²

Learning points

- ▶ Radiographic studies, including IVU or RP, and CT, are useful for the diagnosis of ureterosciatic hernias.
- ▶ Placement of a stent is considered a preferred choice of treatment for ureterosciatic hernias because it is less invasive.
- ▶ Placement of a ureteral stent is not curative therapy; therefore, patients need to be monitored and followed up.
- ▶ Although uncommon, cases of ureterosciatic hernias do exist, so it is necessary to carefully examine, diagnose and treat older patients complaining of lower back pains.

Contributors YN reviewed the literature and wrote the manuscript. NM followed the patient in the outpatient setting and helped write the manuscript. IC and KM reviewed the literature and the contents of the manuscript.

Funding The authors have not declared a specific grant for this research from any funding agency in the public, commercial or not-for-profit sectors.

Competing interests None declared.

Patient consent Obtained.

Provenance and peer review Not commissioned; externally peer reviewed.

Open Access This is an Open Access article distributed in accordance with the Creative Commons Attribution Non Commercial (CC BY-NC 4.0) license, which permits others to distribute, remix, adapt, build upon this work non-commercially, and license their derivative works on different terms, provided the original work is properly cited and the use is non-commercial. See: <http://creativecommons.org/licenses/by-nc/4.0/>

© BMJ Publishing Group Ltd (unless otherwise stated in the text of the article) 2018. All rights reserved. No commercial use is permitted unless otherwise expressly granted.

REFERENCES

- 1 Yanagi K, Kan A, Sejima T, *et al*. Treatment of ureterosciatic hernia with a ureteral stent. *Case Rep Nephrol Dial* 2015;5:83–6.
- 2 Whyburn JJ, Alizadeh A. Acute renal failure caused by bilateral ureteral herniation through the sciatic foramen. *Urology* 2013;81:e38–e39.
- 3 Loffroy R, Bry J, Guiu B, *et al*. Ureterosciatic hernia: a rare cause of ureteral obstruction visualized by multislice helical computed tomography. *Urology* 2007;69:385.e1–385.e3.

Copyright 2018 BMJ Publishing Group. All rights reserved. For permission to reuse any of this content visit <http://group.bmj.com/group/rights-licensing/permissions>.
BMJ Case Report Fellows may re-use this article for personal use and teaching without any further permission.

Become a Fellow of BMJ Case Reports today and you can:

- ▶ Submit as many cases as you like
- ▶ Enjoy fast sympathetic peer review and rapid publication of accepted articles
- ▶ Access all the published articles
- ▶ Re-use any of the published material for personal use and teaching without further permission

For information on Institutional Fellowships contact consortiasales@bmjgroup.com

Visit casereports.bmj.com for more articles like this and to become a Fellow