



OPEN ACCESS

CASE REPORT

Successful treatment of postural orthostatic tachycardia and mast cell activation syndromes using naltrexone, immunoglobulin and antibiotic treatment

Leonard B Weinstock,^{1,2} Jill B Brook,³ Trisha L Myers,⁴ Brent Goodman⁵

¹Medicine, Washington University, Saint Louis, Missouri, USA

²Gastroenterology, Specialists in Gastroenterology, Saint Louis, MO, USA

³Biostatistics, Private Practice, Anchorage, Alaska, USA

⁴Gastrointestinal Department, Specialists in Gastroenterology, Saint Louis, Missouri, USA

⁵Department of Neurology, Mayo Clinic Arizona, Scottsdale, Arizona, USA

Correspondence to

Dr Leonard B Weinstock, lw@gidocor.net

Accepted 22 December 2017

SUMMARY

A patient with severe postural orthostatic tachycardia syndrome (POTS) and mast cell activation syndrome (MCAS) received immunotherapy with low-dose naltrexone (LDN) and intravenous immunoglobulin (IVIg) and antibiotic therapy for small intestinal bacterial overgrowth (SIBO). A dramatic and sustained response was documented. The utility of IVIg in autoimmune neuromuscular diseases has been published, but clinical experience with POTS is relatively unknown and has not been reported in MCAS. As a short-acting mu-opioid antagonist, LDN paradoxically increases endorphins which then bind to regulatory T cells which regulate T-lymphocyte and B-lymphocyte production and this reduces cytokine and antibody production. IVIg is emerging as a promising therapy for POTS. Diagnosis and treatment of SIBO in POTS is a new concept and appears to play an important role.

BACKGROUND

These syndromes are generally regarded as rare or are never diagnosed owing to lack of awareness by physicians. The prevalence of postural orthostatic tachycardia syndrome (POTS) is at least 170/100 000, and the prevalence of mast cell activation syndrome (MCAS) is estimated between 1% and 17%.^{1 2} The confusing magnitude of symptoms led to delay in diagnosis and disability in our patient as is the case for the majority of patients with these syndromes.¹⁻⁴ Fatigue, muscle pain, presyncope/syncope, headache, itching, urticaria, paraesthesia, nausea, chills, oedema, eye irritation, dyspnoea and heartburn are experienced by ≥50% of patients with MCAS.² Postural lightheadedness especially in the morning, palpitations, presyncope, headache, blurry vision, memory problems are experienced by ≥50% of patients with POTS.⁴ To further complicate matters, 17 of 48 MCAS symptoms overlap with 33 POTS symptoms which is explained by comorbidity of the syndromes, where 30% of patients with POTS also have MCAS.⁵ Gastrointestinal (GI) symptoms are common in both syndromes.^{1-4 6} GI symptoms in MCAS can be explained by inappropriate release of mediators from mast cells (MCs) with KIT mutations whereas GI motility disorders in POTS may be due to active autoimmune muscarinic antibodies causing autonomic imbalance in some patients (S Vernino, personal communication, 2017).² Physicians may

erroneously attribute these frequent GI symptoms in undiagnosed MCAS and POTS patients to irritable bowel syndrome (IBS) and psychological disturbances as was the case in our patient.

POTS is generally divided into two categories: neuropathic and hyperadrenergic; the latter is difficult to treat and is thought in part to be associated with MC as a driving force in some patients.^{5 7} POTS therapy has historically focused on treating orthostatic intolerance which does not address other systems (eg, GI tract, urinary bladder sphincter, ocular and central nervous system). MCAS therapy is directed at MC stabilisation, which is complicated by the fact that MC can release 200 mediators many of which have a wide array of triggers.² Small intestinal bacterial overgrowth (SIBO) causes abdominal pain, bloating and abnormal bowel function—these symptoms are prevalent in both syndromes yet a specific investigation has not been reported. The dramatic response to therapy in this patient is remarkable and could help others who suffer from POTS and MCAS.

CASE PRESENTATION

Case

A 43-year-old Caucasian female experienced MCAS symptoms at age 18: specific foods and odours caused flushing, rashes, itching, wheezing, dizziness and nausea. At age 20, she noted problems with postprandial bloating/pain, constipation, evacuating stool and flatus with rotten egg odour. Restless legs syndrome (RLS) gradually developed. At age 23, she developed orthostatic lightheadedness and tachycardia, body pain, generalised weakness and painful dependent leg oedema. Ultimately, she suffered from 45 individual clinically significant symptoms (table 1). For 6 years, she became disabled owing to orthostatic symptoms, fatigue and body pain. Faecal evacuation resulted in syncope with efforts >3 min. Early satiety led to a liquid diet. Pressure-induced hives and angioedema, paraesthesia and nocturnal urination (seven times nightly) interfered with sleep. Over 16 years, 19 physicians failed to diagnose POTS and MCAS which were established at a second location of the Mayo Clinic. Supine pulse of 80 beats/min increased to 160 after standing 10 min. Facial rash and oedema, cold, blue hands, Terry's fingernails and dermatographism were present (figure 1).



CrossMark

To cite: Weinstock LB, Brook JB, Myers TL, et al. *BMJ Case Rep* Published Online First: [please include Day Month Year]. doi:10.1136/bcr-2017-221405

Novel treatment (new drug/intervention; established drug/procedure in new situation)

Table 1 Syndrome severity and frequency scores before and after 1 year of immunotherapy and 2 weeks of antibiotic therapy

	Severity score		Frequency score	
	Before	After	Before	After
POTS symptoms				
Orthostatic lightheadedness	0			
Difficulty passing stool	10	0	10	0
Early satiety	10	0	10	0
Depression*	10	0	10	0
Problems sleeping	10	0	10	0
Swelling	10	0	10	0
Tinnitus	10	0	10	0
Visual sensitivity to light	10	0	10	0
Abdominal pain*	10	1	10	1
Dry mouth	10	1	10	1
Bloating*	10	1	10	2
Nocturnal urination (>1×)	10	1	10	2
Whole body pain	10	1	10	2
Frequent daytime urination	10	1	10	4
Leg pain	10	2	10	4
Extremities change colour	10	3	10	5
Sensitivity to heat and odour	10	3	10	5
Fainting	10	0	9	0
Fatigue*	10	0	9	0
Orthostatic tachycardia	10	0	9	0
Numbness and tingling	10	3	9	4
Facial flushing*	10	0	8	0
Vertigo	9	0	8	0
Hand pain	8	0	10	0
Headache*	8	0	10	0
Blurred vision	8	0	8	0
Joint pain	8	0	8	0
Muscular weakness	8	0	8	0
Shortness of breath*	8	0	7	0
Nausea	7	0	8	0
Dry eyes	6	0	8	0
Rashes*	6	0	8	0
Brain fog*	4	0	8	0
Total	300	17	305	30
MCAS symptoms				
Constipation (<3/week)*	10	0	10	0
Depression*	10	0	10	0
Insomnia*	10	0	10	0
Lightheaded (any position)	10	0	10	0
Chills	10	1	10	0
Abdominal pain*	10	1	10	1
Oedema*	10	2	10	0
Pressure-induced swelling	10	2	10	5
Heat intolerance	10	3	10	5
Fatigue*	10	0	9	0
Flushing*	10	0	8	0
Anxiety	10	0	8	0
Itching/hives	10	0	7	0
Sudden palpitations	10	0	7	0
Headaches*	8	0	10	0
Shortness of breath*	8	0	7	0
Environmental allergies	7	1	8	1
Nausea*	7	2	6	0

Continued

Table 1 Continued

	Severity score		Frequency score	
	Before	After	Before	After
Panic attacks	7	0	4	0
Muscle pain*	6	0	10	0
Rashes*	6	0	8	0
Chest pain	6	0	4	0
Poor healing	5	0	4	0
Brain fog*	4	0	8	0
Total	204	12	198	12
SIBO symptoms				
Abdominal pain*	10	1	10	1
Foul and excessive flatus	10	1	10	1
Bloating*	10	1	10	2
Constipation (<3/week)*	8	0	10	0
Total	38	3	40	4

*Symptoms that are shared by other syndromes.

MCAS, mast cell activation syndrome; POTS, postural orthostatic tachycardia syndrome; SIBO, small intestinal bacterial overgrowth.

The patient is a biostatistician who did not smoke or drink. The family history was unremarkable.

INVESTIGATIONS

The tilt table test demonstrated the presence of hyperadrenergic POTS (increase in heart rate >30 beats/min, rise in systolic blood pressure ≥10 mm Hg and serum norepinephrine level ≥600 pg/mL). The standing serum norepinephrine was 754 pg/mL (normal 119–451 pg/mL). Sudomotor testing revealed diminished postganglionic sympathetic function in feet. Abnormal tests included leukocytes $3.1 \times 10^9/L$ (normal $3.4\text{--}10.6/10^9/L$), platelets $113 \times 10^9/L$ (normal $149\text{--}375/10^9/L$), low T4 and T3, and elevated 24-hour urine leukotriene E4 523 pg/mg creatinine (normal <104 pg/mg) and 11β -prostaglandin-F2α 1796 ng/mmol creatinine (normal <1000 ng/mmol creatinine). Normal tests included chemistry panels, lactate, cold agglutinins, tryptase, ferritin and 24-hour urine levels of metanephrine, N-methylhistamine and 5-hydroxyindoleacetic acid (5-HIAA). The antithyroid peroxidase antibody was the only positive autoantibody. Nineteen other commercially available autoantibodies (including Sjogren's, lupus and coeliac antibodies) that can be linked to, but not mechanistically active in POTS were absent.

The diagnosis of MCAS was established by: (1) presence of the major MCAS criterion: presence of a constellation of complaints attributable to pathologically increased MC activity in ≥2 organ systems and (2) presence of ≥1 of 4 minor criteria.² The patient had 47 of the 48 known MCAS symptoms with dysfunction of the cardiovascular, respiratory and GI systems as well as symptomatic involvement of the skin, eyes and nose (table 1). The patient had biochemical evidence for MC activity (two urine assays) and she ultimately had response to medical therapy directed against MC.

DIFFERENTIAL DIAGNOSIS

Differential diagnosis in POTS includes: cardiac arrhythmia, venous insufficiency, chronic fatigue syndrome, anxiety and various GI disorders including acid reflux disease, gastric emptying disorders, pelvic floor dysfunction, IBS, carcinoid syndrome and pheochromocytoma. For this patient, all specific diseases and triggers known to cause POTS were excluded.¹ Specifically, there was no history, physical findings, radiographic

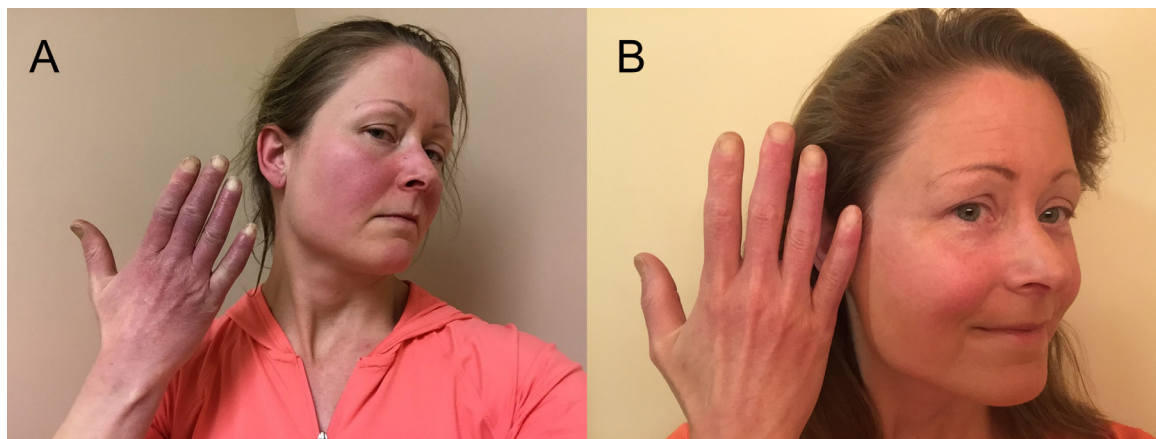

Figure 1 (A) Vasospasm with cyanosis and oedema, Terry's nails, and facial flushing, rash and oedema; (B) After third intravenous immunoglobulin infusion, face returned to normal and hand colour, swelling and temperature improved. The patient gave her permission to use uncensored photographs.

data or serological evidence of traumatic brain and electrical injury, Lyme's disease, human papillomavirus vaccination, pregnancy, median arcuate ligament syndrome, hypermobile Ehlers-Danlos syndrome (EDS) (present in 30% of POTS), coeliac disease, Sjogren's syndrome, antiphospholipid syndrome, rheumatoid arthritis, lupus and common variable immunodeficiency. The norepinephrine was elevated but not to the level seen in pheochromocytoma. Differential diagnosis of MCAS includes: chronic fatigue syndrome, fibromyalgia, generalised allergies, asthma, sinusitis, rosacea, anxiety, IBS, interstitial cystitis, carcinoid syndrome and pheochromocytoma. The duration of the illness and the 5-HIAA measurement excludes carcinoid syndrome.

TREATMENT

Thyroid replacement led to resolution of RLS. Hypothyroidism is a known cause for this syndrome. POTS vasoactive medications (midodrine, amphetamine and droxidopa), MCAS medications including cromolyn sodium, montelukast, antihistamines (hydroxyzine and all over-the-counter H1 and H2 blockers) and acetylsalicylic acid, support stockings, high salt diet and thyroid supplementation failed to give the patient any relief.

The patient studied low-dose naltrexone (LDN) and intravenous immunoglobulin (IVIg) on the Internet as alternative therapy for pain and POTS. As a scientist, the patient tracked symptoms which were later divided into three syndromes (table 1). In the absence of validated scoring systems for MCAS and POTS, the severity and frequency scores for symptoms were established by the authors as 10-point Likert scales: (A) Frequency: 0=never, 1=once a month or less, 2=1–3 times a month, 3=once a week, 4=a few times a week, 5=most days, 6=once a day, 7=a few times per day, 8=most of the time, 9=nearly constantly, 10=constantly, without exception and (B) Severity: 0=nonexistent, 1=very mild, 2=rather mild, 3=mild, 4=low moderate, 5=moderate, 6=high moderate, 7=starting to be severe, 8=severe, 9=extremely severe, 10=most severe possible. IBS studies have used Likert scores as well. More recently a combined response that includes a decrease in pain of 30% or more and improvement in stool form over a period of time have been used in drug studies; however, this was not felt to be as helpful in this single case report.

Her internist prescribed ultra-low-dose naltrexone (1 mg every night as opposed to dose escalation to ideal dose of 4.5 mg)

while waiting for insurance approval for IVIg to be used for the Food and Drug Administration-approved indication of pressure-induced urticaria. Ultra-low-dose naltrexone for 6 weeks improved body pain, mood, memory, sleep, flushing, food and odour sensitivities and paraesthesia: 7% decrease in POTS and 17% decrease in MCAS severity scores. Subsequently, IVIg 1.5 g/kg (Privigen) and 125 mg methylprednisolone were administered monthly. Naltrexone was continued at 1 mg every night. Six days after the first IVIg infusion, syncope, tinnitus, anal outlet disorder and vascular spasm ceased. Capillary refill time was >1 min before IVIg and reduced to <2 s. The next two infusions further improved body pain, weakness, vertigo, ability to eat and facial changes. Subsequent infusions maintained symptomatic improvement but the efficacy did not improve further (figure 2). The platelet counts normalised when measured after the sixth infusion.

After GI consultation, the naltrexone dose was increased and a lactulose breath test (LBT), an indirect test for SIBO, was obtained.⁸ The LBT had a flat-line pattern suggesting excretion of hydrogen sulfide (H_2S) which was confirmed by a prototype H_2S breath test machine (Commonwealth Labs, Boston, Massachusetts, USA). Rifaximin 550 mg tablet per os three times a day for 2 weeks and a low sulfate/sulfide diet eliminated postprandial bloating, abdominal pain, constipation and foul gas. Subsequent dose escalations of LDN and short-term rifaximin improved therapeutic response curves: 24% decrease in POTS and 43% decrease in MCAS severity scores (figure 2).

OUTCOME AND FOLLOW-UP

After 10 IVIg treatments, a previously scheduled appointment at Mayo Clinic Scottsdale included autonomic testing which showed resolution of tachycardia with head-up tilt along with improvement in sudomotor function. At the time of submission of this report, the patient has had 20 IVIg treatments with a maximum of 5 weeks without one because the effects start to wear off. A trial of mycophenolate mofetil led to immune suppression. The next plan is to add new mast cell therapies in combination with IVIg and LDN.

DISCUSSION

A patient with severe POTS, MCAS and SIBO responded to a combination of LDN, IVIg and antibiotic therapy. We theorise

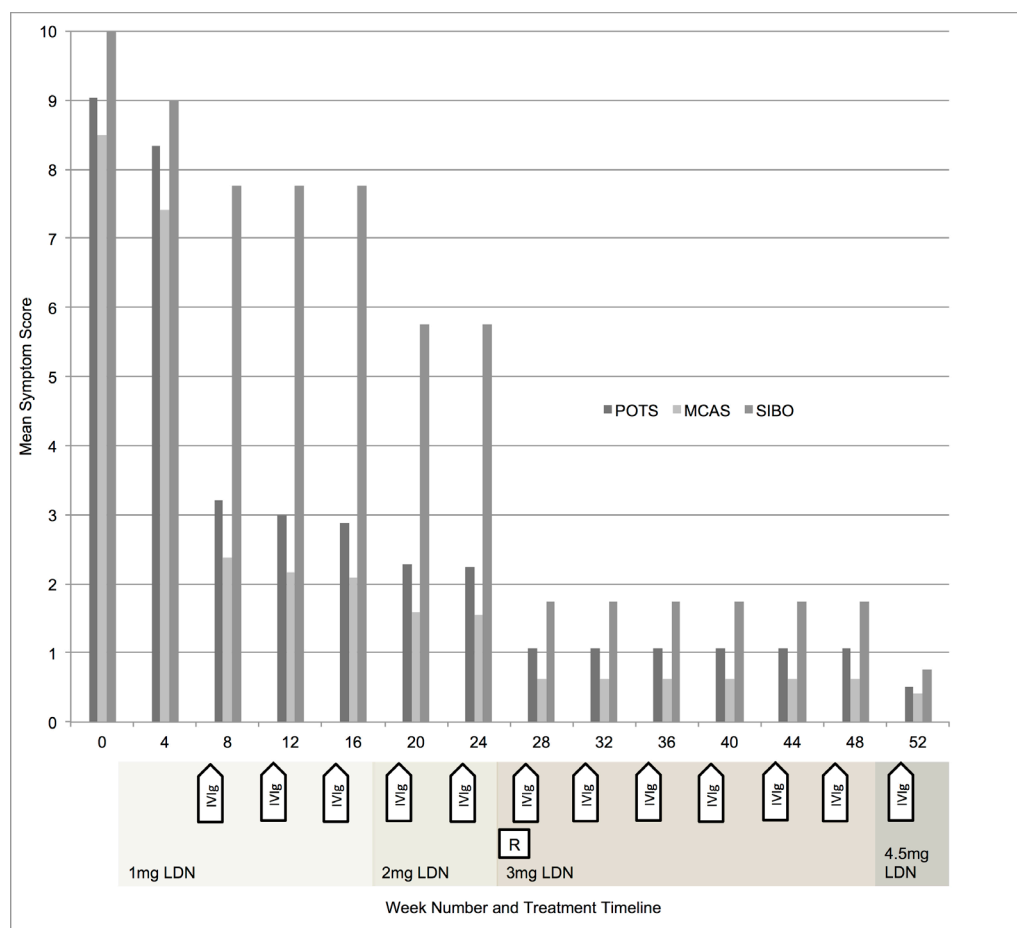


Figure 2 Change in mean syndrome symptom indexes with continuous administration of low-dose naltrexone (LDN) with dose escalation, monthly intravenous immunoglobulin (IVIg) starting 2 months later and a 2-week course of rifaximin. MCAS, mast cell activation syndrome; POTS, postural orthostatic tachycardia syndrome; SIBO, small intestinal bacterial overgrowth.

that pre-existing MCAS was the driving force for hyperadrenergic POTS in this patient. This is the first case to our knowledge where immunotherapy with IVIg led to significant and sustained improvement in MCAS as has been seen in publications of autoimmune neuromuscular diseases and a single case of POTS.^{9 10} Other patients with MCAS have had response in their MC symptoms to IVIg.² To our knowledge, this is also the first reported case of LDN improving symptoms of POTS and MCAS. Antibiotic therapy with rifaximin led to cessation of two decades of significant GI problems in our patient. Huang *et al* reported that 7/12 patients with POTS had dilated and/or air-fluid levels in the small intestine.¹¹ We theorise that sustained sympathetic activity suppresses peristalsis, leading to stasis and development of SIBO in some patients with POTS. Alternative explanations for SIBO in POTS or MCAS who have concomitant EDS include presence of droopy small bowel loops or motor dysfunction due to protein deposition.¹² We also theorise that eliminating SIBO can lessen MCAS and subsequent POTS by reducing intestinal permeability, thus reducing MC recruitment as well as T-cell activity and cytokines which activate MC.

In the present case, severe symptoms of MCAS preceded onset of POTS, thus, two driving forces are theorised to be important: mast cell activation adjacent to autonomic nerves and/or persistent recruitment and/or activation of MC due to bacterial overgrowth.^{5 7 13} It is less likely that an autoimmune neuropathic process is operative. However, we could not measure investigative adrenergic active autoantibodies and muscarinic

acetylcholinesterase autoantibodies in order to include or exclude POTS-specific active autoantibodies (S Vernino, personal communication, 2017).¹⁴

One of the authors (BG) who reported successful treatment of POTS associated with Sjogren's syndrome in 2017 has successfully treated over 50 subsequent patients.¹⁰ One of our GI clinic patients with POTS and MCAS treated with IVIg had improvement in cardiovascular symptoms and a dramatic cessation of the abdominal pain and diarrhoea which had triggered 250 emergency room visits over the past 15 years. Another GI clinic patient with POTS and SIBO but not MCAS was treated with IVIg had improvement in cardiovascular symptoms and later in GI symptoms after repeating antibiotic therapy. The change in this patient suggested that autoantibodies were operative.

One common mechanism for high-dose IVIg to work in autoimmune disease is binding the Fc portion of autoantibodies.⁹ MC are most commonly known to have IgE receptors, but they also have IgG receptors.¹⁵ When these are activated by IgG, histamine is released.¹⁵ Theoretically, IVIg could overload these receptors and ultimately reduce MC mediator release. IVIg could also bind to histamine and block histamine activation of MC as seen in rats.¹⁶ An additional trigger for MC activation includes T-cell activity and release of microparticles and cytokines.¹⁷ IVIg increases regulatory T-cells which could reduce T-cell activity and thereby reduce MC activity.¹⁸ Finally, IgG has been found to downregulate IgE bound to MC and thus binding IgG by IVIg could play an additional role.¹⁹

Beneficial effects of LDN on MCAS may include regulating overall T-lymphocyte production and decreasing cytokine mediators from T cells which directly cause MC activation, blocking Toll receptors which stimulate MC activity and reducing

Patient's perspective

After decades of declining health, despite trying every conventional treatment with 100% compliance, I was pretty discouraged. I used to be such a high achiever and now I couldn't even stand or sit up. I'd seen numerous top specialists and tried everything they recommended. I started seeing doctors for these complaints in 1997, and first received diagnoses of rosacea and restless leg syndrome. Rosacea was treated with antibiotics and numerous laser treatments. RLS was treated unsuccessfully with iron supplements and trials of various drugs (like ropinerole, which made me pass out). My face flushes got better, but other POTS/MCAD/RLS symptoms continued to get worse. Cardiologists didn't find anything, but referred me to a neurologist for dizziness and presyncope. The neurologist thought I had Lambert Eaton Myasthenic Syndrome, and referred me to the Mayo Clinic in 2006. They determined I did not have LEMS, but did have 'excessive venous compliance', and prescribed compression stockings. After that, the original neurologist was out of ideas and suggested I get a psych evaluation, which I declined. Still getting worse, I got diagnoses of Hashimoto's thyroid in 2007 (treated with synthroid) and 'severe' chronic venous insufficiency of the deep venous system in 2010 (measured three different times by Doppler ultrasound and treated with tighter compression stockings, elevating legs and more activity). That was a bit mysterious at the time because my valves were intact, so they didn't know why my blood was flowing backwards (later they measured some of my veins at much wider diameters than expected, so that probably explains it). I saw a gastroenterologist for my 'potty issues' in 2012, but she didn't seem to think they were a big deal. In 2013, I realised Claritin helped, and that led me to figure out I may have POTS and MCAD. I referred myself to Mayo AZ, who confirmed it, and they started treatment with all the many drugs listed above. I was also diagnosed with 'delayed pressure urticaria / angioedema', DPU which is a mast cell problem where physical pressure leads to localised pain and swelling for days after. It's a comically cruel problem to have along with POTS because one keeps you from being upright while the other keeps you from being able to lie down comfortably more than a few minutes ... so you writhe on the ground mostly. But I'm grateful I have it because it's the diagnosis that allowed me to receive IVIg!

I feel like I won the lottery last year by discovering LDN, IVIg and SIBO treatment. LDN made me feel noticeably happier, more energetic, in less pain and with better digestion (and these things got better with each dose increase). IVIg was an absolute miracle and within a week gave me a life back, with a huge improvement of numerous symptoms, most importantly fainting, nerve pain and delayed pressure angioedema. But I still had daily crippling stomach aches and more gas than a field of Holsteins until I took the rifaximin. I can't believe I went decades feeling so bad when I only needed 2 weeks of antibiotics and a low-sulfur diet! Now I'm back to standing, eating, sleeping, working, living and feeling exceptionally lucky. I give permission to Leonard Weinstock, his associates, and any medical journals to use my uncensored photographs in medical presentations or publications.

Learning points

- ▶ Patients with postural orthostatic tachycardia syndrome (POTS) and mast cell activation syndrome (MCAS) have a wide array of symptoms and require an open mind to entertain the diagnoses.
- ▶ POTS can imitate severe gastrointestinal motility disorders, irritable bowel syndrome (IBS), or frequent 'IBS' or small intestinal bacterial overgrowth (SIBO) relapses after antibiotic therapy.
- ▶ Treatments for hyperadrenergic POTS have had limited in efficacy but treatment directed at MCAS can help.
- ▶ Combined therapy with intravenous immunoglobulin and low-dose naltrexone led to significant improvement in a severely affected patient.
- ▶ Antibiotic therapy for SIBO contributed to clinical improvement in the case presentation and others in our practice for both GI symptoms and POTS/MCAS symptoms.

neuroinflammatory pain via microglia.^{12 20–22} Endorphins produced by LDN may improve intestinal dysmotility in POTS by directly increasing the migrating motor complex which prevents small intestinal stasis and subsequent bacterial overgrowth.²³ We theorise that neuropathic POTS with an immune mechanism may also be improved by LDN via reduction of auto-immune antibody production by B-lymphocyte regulation.²⁰

In a chart review of 33 additional patients with POTS in our GI clinic, 27 had lactulose breath testing (26 women, 1 men, mean age 35 years). These patients had MCAS in 27% and EDS in 42%. GI symptoms were present in all patients: mid/lower abdominal pain (96%), bloating (92%), nausea (85%), constipation (73%), diarrhoea (58%) and heartburn (58%). LBT was abnormal in 69% versus abnormal testing in 10% of volunteers in a prior control study.²⁴ EDS did not increase the risk of having a positive breath test in our clinic patients. When methane was present, neomycin was added to rifaximin for 2 weeks since methane producing-bacteria respond best to dual antibiotics.²⁵ Naltrexone was used by 11 patients and 7 had improvement in GI symptoms. Five had improvement in the other syndromes: two MCAS, one POTS and two with both. Antibiotics were administered to 15 patients: 10 had improvement in GI symptoms and 4 had improvement in POTS symptoms. One of these patients with POTS and MCAS improved dramatically to LDN and antibiotics, but after several months decided to stop LDN. Orthostatic symptoms, body pain, pruritus, alopecia, GI symptoms and fatigue returned and then later improved on resumption of LDN.

IVIg appeared to be effective for multiple manifestations of POTS but this treatment is expensive and has potential significant side effects. In contrast, LDN is inexpensive, safe and appeared to provide effective, adjunctive therapy in both MCAS and POTS. Recognition that small bowel dysfunction in POTS can lead to SIBO is important since antibiotic treatment can lead to significant GI relief.

Contributors LBW: treating physician diagnosed and treated POTS, MCAS and SIBO; wrote majority of manuscript. JBB: tabulated table 1 and contributed to case report writing, references and critically reviewed manuscript. TLM: acquired and contributed to references, wrote part of introduction and critically reviewed manuscript. BG: treating physician diagnosed and treated POTS and MCAS, wrote part of discussion and critically reviewed manuscript.

Competing interests None declared.

Patient consent Obtained.

Provenance and peer review Not commissioned; externally peer reviewed.

Open Access This is an Open Access article distributed in accordance with the Creative Commons Attribution Non Commercial (CC BY-NC 4.0) license, which permits others to distribute, remix, adapt, build upon this work non-commercially, and license their derivative works on different terms, provided the original work is properly cited and the use is non-commercial. See: <http://creativecommons.org/licenses/by-nc/4.0/>

© BMJ Publishing Group Ltd (unless otherwise stated in the text of the article) 2018. All rights reserved. No commercial use is permitted unless otherwise expressly granted.

REFERENCES

- Dahan S, Tomljenovic L, Shoenfeld Y. Postural orthostatic tachycardia syndrome (POTS). A novel member of the autoimmune family. *Lupus* 2016;25:339–42.
- Afrin LB, Self S, Menk J, et al. Characterization of mast cell activation syndrome. *Am J Med Sci* 2017;353:207–15.
- Benarroch EE. Postural tachycardia syndrome: a heterogeneous and multifactorial disorder. *Mayo Clin Proc* 2012;87:1214–25.
- Deb A, Morgenshtern K, Culbertson CJ, et al. A survey-based analysis of symptoms in patients with postural orthostatic tachycardia syndrome. *Proc* 2015;28:157–9.
- Shibao C, Arzubiaga C, Roberts LJ, et al. Hyperadrenergic postural tachycardia syndrome in mast cell activation disorders. *Hypertension* 2005;45:385–90.
- Loavenbruck A, Singer W, Sletten D, et al. Gastrointestinal dysmotility in postural tachycardia syndrome. *Neurogastroenterol Motil* 2015;27:92–8.
- Kanjwal K, Saeed B, Karabin B, et al. Clinical presentation and management of patients with hyperadrenergic postural orthostatic tachycardia syndrome. A single center experience. *Cardiol J* 2011;18:527–31.
- Rezaie A, Buresi M, Lembo A, et al. Hydrogen and methane-based breath testing in gastrointestinal disorders: the North American Consensus. *Am J Gastroenterol* 2017;112:775–84.
- Berger M, McCallus DE, Lin CS-Y. Rapid and reversible responses to IVIG in autoimmune neuromuscular diseases suggest mechanisms of action involving competition with functionally important autoantibodies. *Journal of the Peripheral Nervous System* 2013;18:275–96.
- Goodman BP. Immunoresponse autonomic neuropathy in sjögren syndrome—case series and literature review. *Am J Ther* 2017;1.
- Huang RJ, Chun CL, Friday K, et al. Manometric abnormalities in the postural orthostatic tachycardia syndrome: a case series. *Dig Dis Sci* 2013;58:3207–11.
- Weinstock LB, Myers TL, Walters AS, et al. Identification and treatment of new inflammatory triggers for complex regional pain syndrome: small intestinal bacterial overgrowth and obstructive sleep apnea. *A A Case Rep* 2016;6:272–6.
- Afrin LB, Khoruts A. Mast cell activation disease and microbiotic interactions. *Clin Ther* 2015;37:941–53.
- Li H, Yu X, Liles C, et al. Autoimmune basis for postural tachycardia syndrome. *J Am Heart Assoc* 2014;3:e000755.
- Moodley I, Mongar JL. IgG receptors on the mast cell. *Agents Actions* 1981;11:77–83.
- Ishikawa T, Shimada T, Kessoku N, et al. Inhibition of rat mast cell degranulation and histamine release by histamine-rat gammaglobulin conjugate. *Int Arch Allergy Appl Immunol* 1979;59:403–7.
- Salamon P, Sheffer I, Hershko AY, et al. The Involvement of Protein Kinase D in T Cell-Induced Mast Cell Activation. *Int Arch Allergy Immunol* 2016;171:203–8.
- Maddur MS, Kaveri SV, Bayry J. Circulatory normal IgG as a stimulator of regulatory T cells. Lessons from intravenous immunoglobulin. *Trends Immunol* 2017;38:789–92.
- Uermösi C, Zabel F, Manolova V, et al. IgG-mediated down-regulation of IgE bound to mast cells: a potential novel mechanism of allergen-specific desensitization. *Allergy* 2014;69:338–47.
- McLaughlin PJ, McHugh DP, Magister MJ, et al. Endogenous opioid inhibition of proliferation of T and B cell subpopulations in response to immunization for experimental autoimmune encephalomyelitis. *BMC Immunol* 2015;16:16–24.
- Parkitny L, Younger J. Reduced pro-inflammatory cytokines after eight weeks of low-dose naltrexone for fibromyalgia. *Biomedicine* 2017;5:16.
- Younger J, Parkitny L, McLain D. The use of low-dose naltrexone (LDN) as a novel anti-inflammatory treatment for chronic pain. *Clin Rheumatol* 2014;33:451–9.
- Jian R, Janssens J, Vantrappen G, et al. Influence of metenkephalin analogue on motor activity of the gastrointestinal tract. *Gastroenterology* 1987;93:114–20.
- Walters AS, Weinstock LB. Restless legs syndrome is associated with an increased prevalence of small intestinal bacterial overgrowth and irritable bowel syndrome. *Sleep Med* 2011;12:610–3.
- Triantafyllou K, Chang C, Pimentel M. Methanogens, methane and gastrointestinal motility. *J Neurogastroenterol Motil* 2014;20:31–40.

Copyright 2017 BMJ Publishing Group. All rights reserved. For permission to reuse any of this content visit <http://group.bmj.com/group/rights-licensing/permissions>.
BMJ Case Report Fellows may re-use this article for personal use and teaching without any further permission.

Become a Fellow of BMJ Case Reports today and you can:

- Submit as many cases as you like
- Enjoy fast sympathetic peer review and rapid publication of accepted articles
- Access all the published articles
- Re-use any of the published material for personal use and teaching without further permission

For information on Institutional Fellowships contact consortiasales@bmjgroup.com

Visit casereports.bmj.com for more articles like this and to become a Fellow