

# Patient with ESRD with vascular calcifications and ischaemic complications

Olanrewaju A Olaoye, Abhilash Koratala

Department of Nephrology,  
College of Medicine, University  
of Florida, Gainesville, Florida,  
USA

**Correspondence to**  
Dr Abhilash Koratala,  
akoratsla@ufl.edu

Accepted 21 September 2017

## DESCRIPTION

The prevalence of vascular calcification in patients with advanced chronic kidney disease (CKD) is very high.<sup>1</sup> It is thought that calciphylaxis and vascular calcification are a continuum of extraskeletal osteogenesis and the clinical manifestations depend on the location of the affected artery.<sup>2,3</sup> Calciphylaxis is associated with high morbidity and mortality. It commonly involves legs, abdomen and gluteal region, and rarely locations such as breast<sup>4</sup> and penis. Sodium thiosulfate therapy is frequently used for the treatment of calciphylaxis. However, the response rate is relatively low with only about 27% of patients showing complete resolution, and 1 year mortality remaining high at ~35% despite treatment.<sup>5</sup>

We recently cared for a 58-year-old man with CKD stage 5 secondary to diabetic nephropathy, who was admitted to the hospital for sepsis and gangrenous lesions of left ring finger, great toe, scrotum and penis. He was recommended to start dialysis a year ago, at which time he refused. His labs at presentation were significant for blood urea nitrogen of 174 mg/dL (7–25), serum creatinine 11.4 mg/dL (0.7–1.2), potassium 5.4 mmol/L (3.4–5.2), bicarbonate 16 mmol/L (22–27), calcium 8 mg/dL (8.6–10.3), phosphate 12 mg/dL (2.5–5.5), albumin 2.1 g/dL (3.6–5.1), and parathyroid hormone 576 pg/mL (150–300 for end stage renal disease). Plain radiographs and CT scan showed extensive arterial calcifications in the affected areas, suggestive of evolving calciphylaxis (figure 1). Protein C and S deficiency was excluded by appropriate lab

## Learning points

- ▶ There is a high prevalence of vascular calcification in patients with advanced chronic kidney disease (CKD), and it is thought to be in continuum with extraskeletal osteogenesis and calciphylaxis.
- ▶ High calcium-phosphate product, elevated parathyroid hormone, hypoalbuminaemia, diabetes, obesity, warfarin use, female sex and protein C or S deficiency are among the risk factors for calciphylaxis.
- ▶ Calciphylaxis is associated with high morbidity and mortality despite treatment, mainly from sepsis. Early nephrology referral of patients with CKD and aggressive management of CKD-mineral and bone disorder and other risk factors in addition to timely dialysis-related education may decrease the incidence of this complication.

tests. His body mass index was 34 and he was not on systemic anticoagulation. While the definitive diagnosis of calciphylaxis is skin biopsy, it is not recommended for penoscrotal lesions because of the risk for progression of necrosis. His extremity lesions were grossly necrotic and the yield of biopsy would be low. Therefore, we empirically started him on intravenous sodium thiosulfate therapy along with initiation of haemodialysis. He was also treated with intravenous antibiotics, wound care and appropriate medical management of CKD-mineral and bone disorder. However, his lesions did not improve after 3 months, at which time he was rehospitalised for sepsis and eventually transitioned to palliative care.

**Contributors** OAO authored the initial draft; AK was the attending physician on the case, revised the manuscript for critically important intellectual content and approved for final submission.

**Competing interests** None declared.

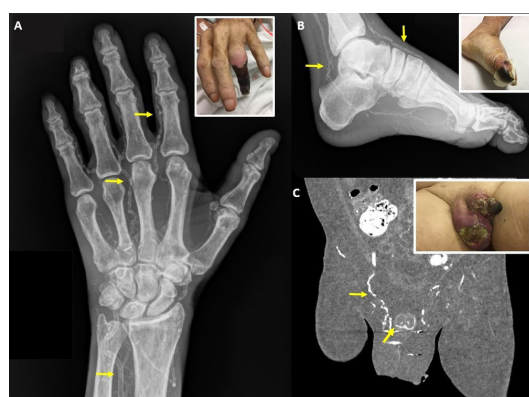
**Patient consent** Obtained.

**Provenance and peer review** Not commissioned; externally peer reviewed.

© BMJ Publishing Group Ltd (unless otherwise stated in the text of the article) 2017. All rights reserved. No commercial use is permitted unless otherwise expressly granted.

## REFERENCES

- 1 Goldsmith DJ, Covic A, Sambrook PA, et al. Vascular calcification in long-term haemodialysis patients in a single unit: a retrospective analysis. *Nephron* 1997;77:37–43.



**Figure 1** (A) Extensive arterial calcifications of the left hand (arrows). Corresponding finger lesion is shown in the inset. (B) Arterial calcifications in the left foot (arrows), with corresponding toe lesion in the inset. (C) Calcification of the gonadal and penile arteries (arrows) with extensive penoscrotal ulcerations.



CrossMark

**To cite:** Olaoye OA, Koratala A. *BMJ Case Rep* Published Online First: [please include Day Month Year]. doi:10.1136/bcr-2017-222674

- 2 Moe SM, Chen NX. Calciphylaxis and vascular calcification: a continuum of extra-skeletal osteogenesis. *Pediatr Nephrol* 2003;18:969–75.
- 3 Qadri SI, Koratala A. Calciphylaxis with extensive arterial calcification. *Clin Case Rep* 2017;5:1418–9.
- 4 Koratala A, Ejaz AA, Mohandas R. Calciphylaxis of the breast: a rare metabolic complication of kidney disease. *BMJ Case Rep* 2016;2016:bcr2016216665.
- 5 Nigwekar SU, Brunelli SM, Meade D, *et al*. Sodium thiosulfate therapy for calcific uremic arteriopathy. *Clin J Am Soc Nephrol* 2013;8:1162–70.

Copyright 2017 BMJ Publishing Group. All rights reserved. For permission to reuse any of this content visit <http://group.bmj.com/group/rights-licensing/permissions>.  
BMJ Case Report Fellows may re-use this article for personal use and teaching without any further permission.

Become a Fellow of BMJ Case Reports today and you can:

- ▶ Submit as many cases as you like
- ▶ Enjoy fast sympathetic peer review and rapid publication of accepted articles
- ▶ Access all the published articles
- ▶ Re-use any of the published material for personal use and teaching without further permission

For information on Institutional Fellowships contact [consortiasales@bmjgroup.com](mailto:consortiasales@bmjgroup.com)

Visit [casereports.bmj.com](http://casereports.bmj.com) for more articles like this and to become a Fellow