

# Mitral valve prosthesis implanted in the atrial position in a patient with extensive calcification extending from epicardium to mitral annulus

Sana Ghafoor Rahman, Atiq Rehman

Department of Cardiovascular Surgery, Our Lady of Lourdes Medical Center, Camden, New Jersey, USA

**Correspondence to**  
Dr Atiq Rehman,  
atiqmd@aol.com

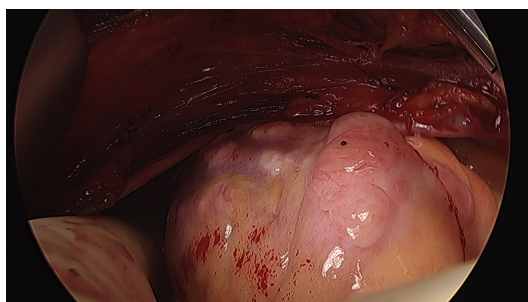
Accepted 25 September 2017

## DESCRIPTION

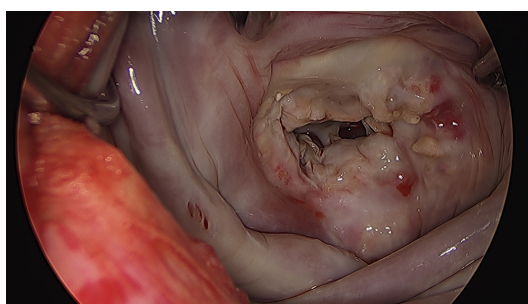
A 72-year-old woman with progressive dyspnoea underwent transoesophageal echocardiography demonstrating mixed mitral stenosis and regurgitation, extensive mitral annular calcification (MAC), left atrial appendage clot and mass on aortic valve. Laboratory work-up revealed normal serum calcium. Left heart catheterisation did not reveal any significant coronary artery disease. Right heart catheterisation

## Learning points

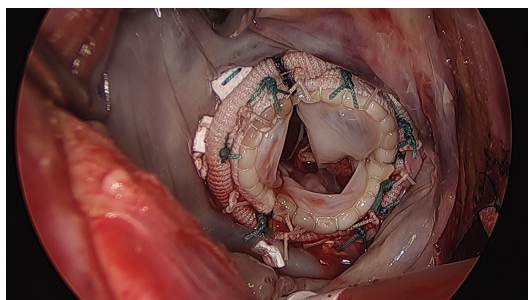
- ▶ Mitral valve replacement can be performed without extensive posterior mitral annular debridement of heavy posterior mitral annular calcification.<sup>1</sup>
- ▶ Multimodality testing including CT scan,<sup>2</sup> transoesophageal echocardiography and cardiac catheterisation can help in preplanning for surgery.



**Figure 1** Intraoperative view of calcification extending to the left ventricular epicardium.



**Figure 2** Extensive mitral annular calcification extending into the posterior left atrial wall.



**Figure 3** Mitral prosthesis sutured posteriorly to CorMatrix patch and anteriorly to mitral annulus.

demonstrated severe pulmonary artery hypertension. Chest CT scan showed extensive calcification extending from left ventricular epicardium to mitral annulus (see online supplementary video 1).<sup>1</sup> Median sternotomy revealed epicardial calcification but none on pericardial (figure 1). Aortic right coronary cusp mass was identified and excised through aortotomy. Left atrial appendage clot was evacuated and AtriClip (AtriCure, Cincinnati, Ohio, USA) 45 mm was applied. Mitral valve was exposed through the left atriotomy. Extensive MAC extending to the atrial wall was observed (figure 2). Anterior mitral leaflet was excised and the posterior leaflet was debrided. A 2 cm wide patch (CorMatrix Cardiovascular, Roswell, Georgia, USA) was sutured to the atrial wall next to the posterior mitral annulus. St Jude Epic tissue 25 mm valve (St Jude, Minneapolis, Minnesota, USA) was secured with 2–0 ethibond (Ethicon, Somerville, New Jersey, USA) sutures inserted through the CorMatrix posteriorly and the annulus anteriorly (figure 3).<sup>2</sup> One-year postoperative (POP) transthoracic echocardiography demonstrated normal-functioning mitral prosthesis and no paravalvular leak (see online supplementary video 2). Differential diagnoses include extensive calcifications secondary to renal failure, malignancy, autoimmune disorder, viral syndromes, radiation therapy, rheumatic heart and congenital heart disease; in the absence of such history, they were possibly idiopathic or degenerative in nature. Pathology of aortic mass revealed papillary fibroelastoma. POP course was complicated by atrial fibrillation, pulmonary embolism and empyema requiring decortication. The patient was discharged to a rehabilitation unit in stable condition on POP day 36.

**Contributors** AR performed the surgery on the listed patient, and SGR formulated the case report after collection of patient data.



CrossMark

**To cite:** Rahman SG, Rehman A. *BMJ Case Rep* Published Online First: [please include Day Month Year]. doi:10.1136/bcr-2017-222142

**Patient consent** Obtained.

**Provenance and peer review** Not commissioned; externally peer reviewed.

© BMJ Publishing Group Ltd (unless otherwise stated in the text of the article) 2017. All rights reserved. No commercial use is permitted unless otherwise expressly granted.

## REFERENCES

- 1 Mejean S, Bouvier E, Bataille V, *et al*. Mitral annular calcium and mitral stenosis determined by multidetector computed tomography in patients referred for aortic stenosis. *Am J Cardiol* 2016;118:1251–7.
- 2 Yoshikai M, Ohnishi H, Fumoto H, *et al*. Mitral valve replacement for a severely calcified mitral annulus. *J Card Surg* 2007;22:502–4.

Copyright 2017 BMJ Publishing Group. All rights reserved. For permission to reuse any of this content visit <http://group.bmj.com/group/rights-licensing/permissions>.  
BMJ Case Report Fellows may re-use this article for personal use and teaching without any further permission.

Become a Fellow of BMJ Case Reports today and you can:

- ▶ Submit as many cases as you like
- ▶ Enjoy fast sympathetic peer review and rapid publication of accepted articles
- ▶ Access all the published articles
- ▶ Re-use any of the published material for personal use and teaching without further permission

For information on Institutional Fellowships contact [consortiasales@bmjgroup.com](mailto:consortiasales@bmjgroup.com)

Visit [casereports.bmj.com](http://casereports.bmj.com) for more articles like this and to become a Fellow