

# CT and PET/CT fusion for lung cancer biopsy planning

Mikhail Cherkashin, Mikhail Aniskhin, Natalia Berezina, Denis Puchkov

► Additional material is published online only. To view please visit the journal online (<http://dx.doi.org/10.1136/bcr-2017-221972>).

Oncology Department, Medical institute n.a. Berezin Sergey, Saint-Petersburg, Russia

## Correspondence to

Dr Mikhail Cherkashin, [mikhail.a.cherkashin@gmail.com](mailto:mikhail.a.cherkashin@gmail.com)

Accepted 18 August 2017

## DESCRIPTION

A 79-year-old man presented with colorectal cancer T4aN0M0 (surgery at 2016) and a newly diagnosed (by chest CT scan) left lung tumour (77×35×51 mm) with hydrothorax in March 2017. Initially, case was suspected as metastatic and 18-fluorodeoxyglucose whole body positron emission tomography (PET)/CT for staging was performed. Multiple mediastinal, bone and brain metastases were found. For tumour biology, verification core needle (18G) lung biopsy was planned. Due to atelectasis, which was detected with metabolic active focus in its caudal part, we decided to fuse PET/CT and biopsy native CT images on the scanner console for clear target visualisation (figure 1A,B). Biopsy was performed without any complications (figure 1C, see online supplementary video), and unfortunately lung adenocarcinoma was verified (immunohistotype thyroid transcription factor (+), cytokeratin (CK) 7 (+), CK20 (–), CDX2 (–), Villin (–)). By molecular genetics test, ex19del mutation in epidermal growth factor receptor gene was identified. In May 2017, gefitinib target therapy was started. Currently, the patient is continuing the target therapy and has achieved good disease control. A CT scan on 11 July 2017 showed a tumour mass with dimensions 26×46×50 mm (regression by Response Evaluation Criteria In Solid Tumours criteria), and no hydrothorax recurrence signs were found. Brain metastases were radiated by Gamma knife.

PET/CT–CT fusion is usually suitable for lung cancer radiotherapy planning.<sup>1</sup> But image fusion for biopsy, in our view, is not a common technique. In our case, image fusion allows to obtain specific tissue samples for clear pathology verification and genetic testing, which helps to develop personalised treatment approach. For the future, if we will have disease control deterioration, the next possible therapeutic option for this patient is anti-programmed death-ligands immunotherapy.<sup>2</sup>

## Learning points

- In case of lung atelectasis around tumour mass, positron emission tomography/CT is a possible option to identify a target for biopsy.
- Cognitive fusion on the CT console during biopsy allows to precision needle placement into metabolic active tumour.

**Acknowledgements** Authors would like to acknowledge Nikita Berezin for video and images processing

**Contributors** MC, concept, design, biopsy performing, supervision, processing, writing manuscript and critical analysis. MA, concept, design, patient care, writing manuscript and critical analysis. NB, supervision, writing manuscript and critical analysis. DP, concept, imaging support, writing manuscript and critical analysis.

**Funding** None declared

**Competing interests** None declared.

**Patient consent** Obtained.

**Provenance and peer review** Not commissioned; externally peer reviewed.

© BMJ Publishing Group Ltd (unless otherwise stated in the text of the article) 2017. All rights reserved. No commercial use is permitted unless otherwise expressly granted.

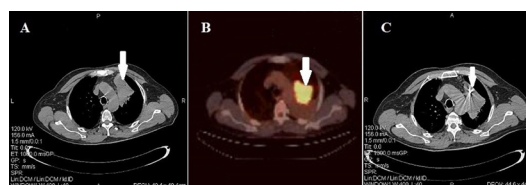
## REFERENCES

- Bradley J, Bae K, Choi N, *et al.* A phase II comparative study of gross tumor volume definition with or without PET/CT fusion in dosimetric planning for non-small-cell lung cancer (NSCLC): primary analysis of Radiation Therapy Oncology Group (RTOG) 0515. *Int J Radiat Oncol Biol Phys* 2012;82:435–41.
- Masters GA, Temin S, Azzoli CG, *et al.* Systemic therapy for stage IV non-small-cell lung cancer: American Society of Clinical Oncology Clinical practice guideline update. *J Clin Oncol* 2015;33:3488–515.



CrossMark

**To cite:** Cherkashin M, Aniskhin M, Berezina N, *et al.* *BMJ Case Rep* Published Online First: [please include Day Month Year]. doi:10.1136/bcr-2017-221972



**Figure 1** (A) Chest CT scan. Tumour mass within atelectasis (arrow). (B) Positron emission tomography/CT scan. Metabolic active focus within atelectasis (arrow). (C) Chest CT scan. Biopsy needle placed into metabolic active area (arrow).

Copyright 2017 BMJ Publishing Group. All rights reserved. For permission to reuse any of this content visit <http://group.bmj.com/group/rights-licensing/permissions>.  
BMJ Case Report Fellows may re-use this article for personal use and teaching without any further permission.

Become a Fellow of BMJ Case Reports today and you can:

- ▶ Submit as many cases as you like
- ▶ Enjoy fast sympathetic peer review and rapid publication of accepted articles
- ▶ Access all the published articles
- ▶ Re-use any of the published material for personal use and teaching without further permission

For information on Institutional Fellowships contact [consortiasales@bmjgroup.com](mailto:consortiasales@bmjgroup.com)

Visit [casereports.bmj.com](http://casereports.bmj.com) for more articles like this and to become a Fellow