



OPEN ACCESS

## CASE REPORT

## Paraneoplastic mucous membrane pemphigoid with ocular and laryngeal involvement

Silvia Lambiel,<sup>1</sup> Pavel Dulguerov,<sup>2</sup> Emmanuel Laffitte,<sup>3</sup> Igor Leuchter<sup>4</sup>

<sup>1</sup>Département des Neurosciences Cliniques, Hôpitaux Universitaires de Genève, Geneva, Switzerland

<sup>2</sup>Département des Neurosciences Cliniques, Hôpitaux Universitaires de Genève, Geneva, Switzerland

<sup>3</sup>Département des Spécialités de Médecine, Hôpitaux Universitaires de Genève, Geneva, Switzerland

<sup>4</sup>Département des Neurosciences Cliniques, Hôpitaux Universitaires de Genève, Geneva, Switzerland

**Correspondence to**

Silvia Lambiel,  
silvialambiel@gmail.com

Accepted 4 August 2017

**SUMMARY**

A 73-year-old woman was treated 8 years previously for synchronous breast and uterine neoplasms. She presented with a severe sore throat, odynophagia, dysphonia, dyspnoea, ocular irritation and weight loss over the last 3 months. Physical examination revealed ulcerations in the oral cavity, posterior pharyngeal wall and supraglottic larynx, nasal crusting, bilateral conjunctivitis and three cutaneous blisters. A diagnosis of anti-laminin 5 mucous membrane pemphigoid was retained, based on skin biopsy, direct immunofluorescence and immunoprecipitation. A positron emission tomography (PET)-CT detected multiple adenopathies. Cytology revealed adenocarcinoma with an immunocytology compatible with a breast origin and this was considered as a late metastatic recurrence of her previous breast cancer. A treatment of prednisone, dapsons and hormone therapy was introduced, but intravenous immunoglobulin and rituximab were added due to new mucosal lesions. Despite treatment, a posterior laryngeal scar and bilateral symblepharon were developed. After 3 years, the patient is still alive and reports a satisfactory quality of life.

**BACKGROUND**

Mucous membrane pemphigoid (MMP), also referred to as cicatricial pemphigoid, is a rare bullous disease affecting predominantly mucosal sites and occasionally the skin in about 25% of cases.<sup>1</sup> Unfortunately, most specialists in oral pathology or otolaryngology are unfamiliar with this disease. The most commonly affected sites include the oral cavity and eye, followed by the nasal, anogenital and pharyngeal mucosa and, less frequently, the oesophagus and larynx.<sup>2</sup> The protean phenotypical manifestations are related to the sites involved, age of the lesions and severity of the disease. The natural course of untreated lesions is irreversible scarring, which can result in airway obstruction and blindness in the case of laryngeal and ocular involvement, respectively. Some studies have evoked the possible association between MMP and malignant neoplasms when autoantibodies to laminin 5 are present,<sup>3–7</sup> arguing that anti-laminin 5 MMP could be a paraneoplastic manifestation, but this notion remains controversial.<sup>8</sup>

Herein, we report a rare case of MMP where several mucosal sites were involved, leading to cicatricial lesions despite adequate treatment. The association between anti-laminin 5 autoantibodies and metastatic breast carcinoma is discussed, as well

as the challenging multidisciplinary management of paraneoplastic MMP.

**CASE PRESENTATION**

A 73-year-old Caucasian woman presented to the ear–nose–throat clinic with a diffuse oral burning sensation and disabling pharyngodynia over the last 3 months. She reported weight loss with asthenia, cough when lying down, hoarseness and dyspnoea. Previous treatments included topical and systemic antifungal agents because of *Candida*-positive oral swabs, antibiotics and antiviral therapy. Two previous oral biopsies revealed fibrin deposits with leucocytes without malignant cells. She had been treated during the previous month for bilateral ocular irritation and nail inflammation of the right index finger by topical antibiotic drops and partial nail avulsion, respectively.

Her past medical history was marked by two simultaneous cancers: a breast carcinoma and an endometrial adenocarcinoma. These had been treated successfully 8 years previously by right mastectomy, axillary dissection, adjuvant radiotherapy and hormone therapy, and by adnexectomy and hysterectomy, respectively. At the last gynaecological examination, there was no sign of recurrence.

Clinical examination revealed bilateral conjunctival inflammation and three blister-type skin lesions on the arms and legs. Inspection of the oral cavity showed mucosal ulcerations of the ventral tongue (figure 1), cheeks, soft palate (figure 2), uvula and posterior oropharyngeal wall. A flexible transnasal endoscopy revealed crusts on the right middle turbinate and nasopharynx, as well as diffuse whitish pseudomembrane-covered erosions of almost all the supraglottic area and posterior hypopharyngeal wall (figure 3).

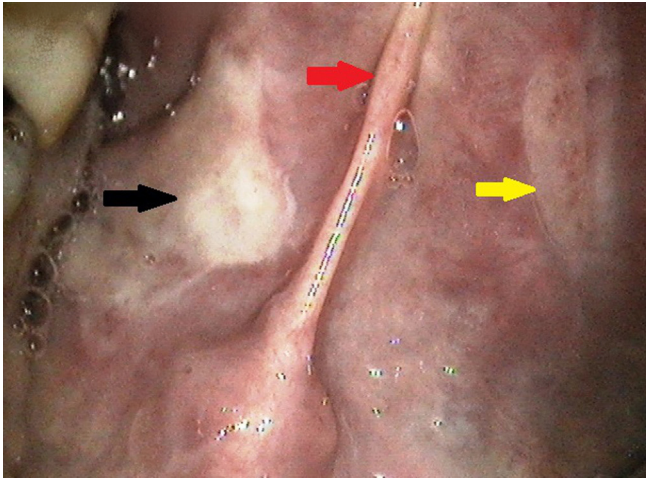
**INVESTIGATIONS**

Full blood tests were unremarkable. A perilesional skin biopsy of a bullous lesion on the left leg revealed subepithelial cleavage with a rare eosinophilic infiltrate on routine histopathological haematoxylin and eosin staining (figure 4). Direct immunofluorescence analysis revealed a linear deposit of IgG and C3 at the dermo-epidermal junction (figures 5 and 6). Indirect immunofluorescence analysis was negative. Immunoblotting studies demonstrated circulating autoantibodies to bullous pemphigoid (BP)180 and laminin 5 (ELISA-BP 180 +: 26.99 U/mL; ELISA-BP 230: –).



CrossMark

**To cite:** Lambiel S, Dulguerov P, Laffitte E, et al. *BMJ Case Rep* Published Online First: [please include Day Month Year]. doi:10.1136/bcr-2017-220887



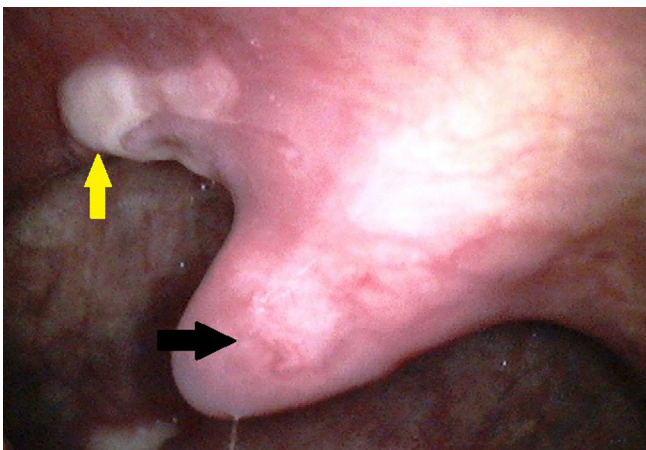
**Figure 1** Intra-oral view of a right sublingual erosion covered with fibrin (black arrow) and a left healing ulcer (yellow arrow). Tongue frenulum (red arrow).

A diagnosis of MMP on clinical and immunohistological criteria was made, including diffuse oral, ocular, nasal, cutaneous, pharyngeal and laryngeal involvement. Given the past oncological history and the presence of anti-laminin 5 antibodies, a PET-CT scan was performed and revealed a left supraclavicular and multiple retroperitoneal adenopathies. Ultrasound-guided and CT-guided fine-needle biopsies were compatible with metastatic adenocarcinoma of breast origin, were hormone dependent and were considered as a late metastatic recurrence of the previous breast tumour, without locoregional relapse.

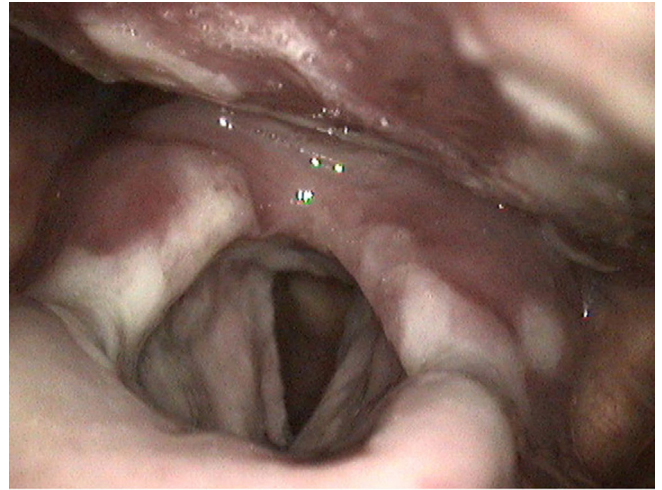
#### DIFFERENTIAL DIAGNOSIS

Diagnosis of MMP is based on clinical features, routine histopathological study (subepithelial split), immunohistological examination (linear deposition of IgG, IgA or C3 along the basement membrane zone on direct immunofluorescence) and serum antibody analysis (indirect immunofluorescence; detection of autoantigens including BP antigen 1 (BPAg1 or BP230), BP antigen 2 (BPAg2 or BP180), integrin subunits alpha-6/beta-4, laminin 5, laminin 6 and type VII collagen by immunoblotting and immunoprecipitation techniques).<sup>1</sup>

Although BP has similar direct immunofluorescence features, the skin is predominantly affected and the differential diagnosis



**Figure 2** View of the oropharynx showing an ulcer with fibrin deposit of the right soft palate (yellow arrow); uvula (black arrow).



**Figure 3** Laryngoscopy showing diffuse whitish pseudomembranes covering the epiglottis and both aryepiglottic folds and arytenoids.

between these entities relies on clinical criteria. Pemphigus disease is distinguished from MMP by clinically flaccid blisters and suprabasal acantholysis on histopathology.

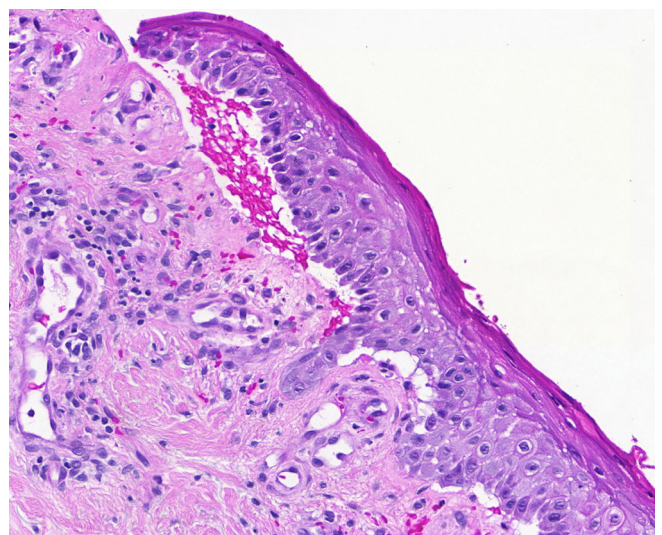
In oral lichen planus, fibrinogen deposition is encountered in the basement membrane zone, but neither IgG, IgA nor C3 is present.

#### TREATMENT

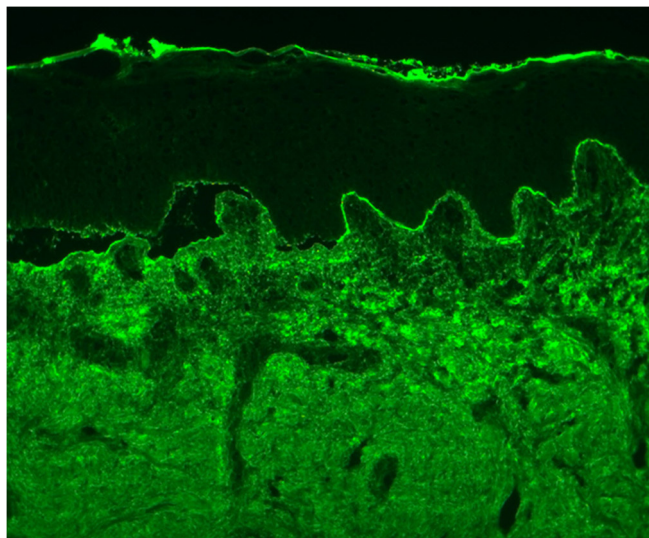
The patient was treated initially with intravenous dexamethasone 4 mg three times daily for 3 days, followed by oral prednisone (30 mg/day) in conjunction with dapsone at increasing doses: 50 mg/day during the first week; 75 mg/day during the second week; and 100 mg/day thereafter. Hormonal therapy with letrozole 2.5 mg/day was also started. A nasogastric feeding tube was initially necessary, but a rapid clinical improvement in the pharynx and larynx allowed the patient to resume oral intake.

#### OUTCOME AND FOLLOW-UP

The active oral lesions completely disappeared initially. However, after 2 months, a transnasal endoscopy revealed an



**Figure 4** Haematoxylin and eosin stain: subepithelial split on a perilesional skin biopsy.

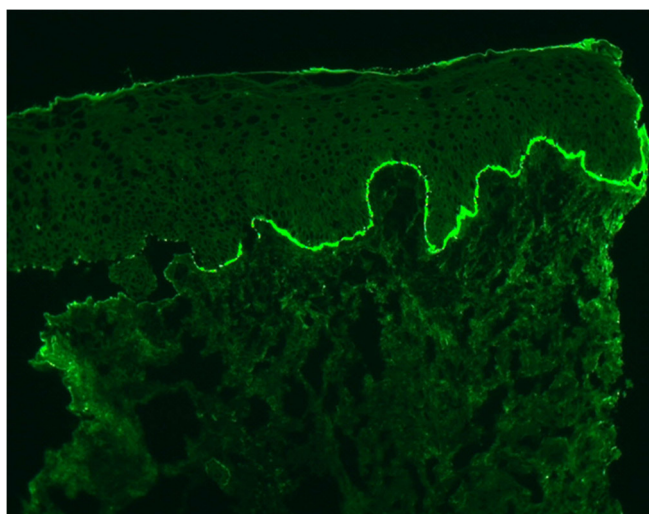


**Figure 5** Direct immunofluorescence of a bullous skin lesion. Linear IgG deposition at the basement membrane.

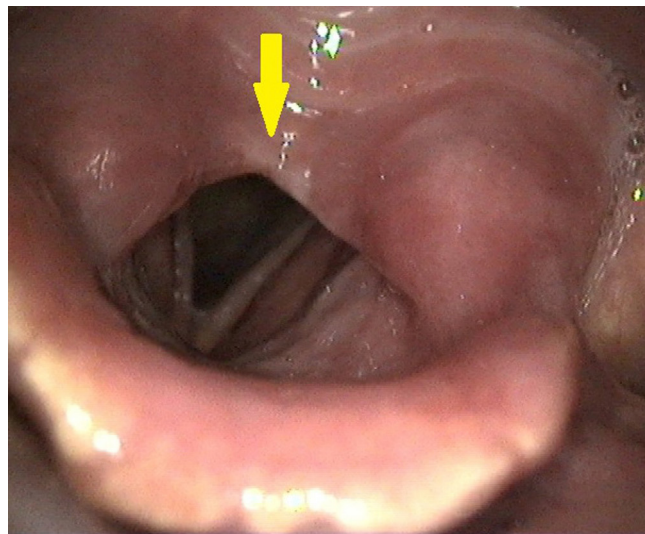
interarytenoid synechia with a somewhat decreased laryngeal patency (figure 7), while the ophthalmic examination showed bilateral moderate symblepharon without active inflammation. Due to a mild haemolysis and general ill feeling when taking dapsone, intravenous immunoglobulin was introduced (every 6 weeks) at a dose of 2 g/kg over 2 days and prednisone and dapsone doses were slowly tapered to 7.5 and 50 mg/day, respectively.

The patient remained in partial remission during the first 12 months with few transient cutaneous lesions, but without mucosal involvement. At 18 months, she suffered from a laryngeal relapse, requiring the introduction of rituximab and a transitory increase of prednisone and dapsone doses, with a good clinical response.

After 3 years, the cicatricial supraglottic scar and symblepharon have remained stable under regular immunoglobulin therapy, dapsone 100 mg/day and prednisone 12.5 mg/day. The metastatic breast adenocarcinoma has stayed under control, and the patient reports an entirely satisfactory quality of life.



**Figure 6** Direct immunofluorescence of a bullous skin lesion. Linear C3 deposition at the basement membrane.



**Figure 7** Laryngoscopy showing interarytenoid synechia (arrow).

## DISCUSSION

MMP is a rare autoimmune subepithelial bullous disease characterised by the linear deposition of IgG, IgA or C3 along the epithelial basement membrane zone and affecting predominantly mucous membranes.<sup>2</sup> The true incidence remains unknown, but it has been estimated to be 1.3–2.0 per million inhabitants per year in France and Germany.<sup>9 10</sup> MMP still remains relatively unknown to dentists, otolaryngologists, gastroenterologists and gynaecologists. Oral mucosa is often involved (85%), followed in decreasing frequency by ocular (65%), nasal (20%–40%), pharyngeal (20%–40%), cutaneous (25%–30%), anogenital (20%), oesophageal (5%–15%) and laryngeal (5%–10%) sites.<sup>1</sup> Different organs can be affected concomitantly with a wide range of symptoms: burning mouth; ocular dryness and irritation; nasal obstruction; rhinorrhoea; odynophagia; dysuria; sexual dysfunction; dysphagia; hoarseness; and breathing difficulty. Active lesions can take the form of erosions, ulcerations, vesicles, blisters, crusts and pseudomembranes. The clinical hallmark of MMP is its propensity to heal without appropriate treatment by irreversible scarring, which can lead to severe complications, such as blindness, airway obstruction, aphagia and death. A prompt diagnosis with a precise clinical examination by different specialists and an appropriate management remain crucial to prevent these complications. Hence, different medical disciplines should be aware of this disease.

A diagnosis of MMP was made in our patient by the clinical and immunohistological criteria obtained by a cutaneous biopsy, which revealed diffuse oral, ocular, nasal, cutaneous, pharyngeal and laryngeal involvement. Two prior oral biopsies were not conclusive, probably because they were taken in the middle of the lesions. The first international consensus conference on MMP<sup>2</sup> recommended that the biopsy specimen should be performed on tissue adjacent to an inflamed non-ocular mucosal site or perilesional skin to improve the sensitivity of histopathological and immunopathologic studies. In this report, cutaneous lesions appeared 10 weeks after the beginning of oropharyngolaryngeal symptoms, thus illustrating the diagnostic challenge in this patient.

Only one randomised controlled study has investigated treatment for MMP, probably because of the rarity of the disease and its large phenotypic expression.<sup>11</sup> Consensus-based recommendations on the medical management proposed to classify patients

## Rare disease

into 'low risk' (oral mucosa or cutaneous involvement) and 'high risk' (ocular, anogenital, nasopharyngeal, oesophageal or laryngeal mucosa involvement).<sup>2</sup> While the initial recommended treatment for low-risk patients is topical corticosteroids, the latter should be managed from the outset more aggressively with systemic corticosteroids or dapsone in conjunction with immunosuppressive therapies in the case of an incomplete response (cyclophosphamide, azathioprine, mycophenolate mofetil). With refractory disease, biological agents can be introduced, such as intravenous immunoglobulin and rituximab. In our case, immunosuppressive drugs were initially avoided because of the metastatic breast adenopathies and two biological therapies (intravenous immunoglobulin and rituximab) were preferred. However, two scarring lesions developed in the eyes (symblepharon) and larynx (interarytenoid synechia). Whether cyclophosphamide might have prevented these cicatricial lesions is debatable. At present, the patient is still alive with stable oncological disease and a self-reported satisfactory quality of life.

Anti-laminin 5 antibodies, also named anti-laminin 332 and anti-epiligrin, are significantly associated with pharyngolaryngeal and oropharyngolaryngeal involvement.<sup>12</sup> Cutaneous lesions are more likely to be associated with BP180 MMP,<sup>13</sup> although they have been described with paraneoplastic anti-laminin 5 MMP.<sup>14</sup> In a cohort of 35 patients, Egan *et al*<sup>5</sup> reported a positive association between antibodies to anti-laminin 5 and an underlying solid neoplasm in 29% of cases. There is some evidence that laminin 5 expression in cancer cells may play a role in cancer biology.<sup>7</sup> Other reports<sup>3 4 6</sup> have discussed a possible link between anti-laminin 5 MMP and cancer, arguing that in such cases MMP should be considered as a paraneoplastic manifestation, as in our patient. Indeed, without an active search by PET-CT, the metastatic breast adenocarcinoma would not have been detected and treated. This raises the question of whether a systematic extensive search for a neoplasm should be performed

in the presence of anti-laminin 5 MMP. In contrast, a retrospective multicentric study by Bernard *et al*<sup>8</sup> did not find any association of anti-laminin 5 with cancer. Thus, additional studies are required to investigate this association.

**Acknowledgements** The authors would like to acknowledge Pr G Kaya for figure 4 and Dr L Fontao for figures 5 and 6.

**Contributors** SL and PD wrote the manuscript. SL, PD, EL and IL revised the manuscript critically. SL, EL and IL participated in the treatment of the patient. All authors approved the final version of the manuscript.

**Competing interests** None declared.

**Patient consent** Obtained.

**Provenance and peer review** Not commissioned; externally peer reviewed.

**Open Access** This is an Open Access article distributed in accordance with the Creative Commons Attribution Non Commercial (CC BY-NC 4.0) license, which permits others to distribute, remix, adapt, build upon this work non-commercially, and license their derivative works on different terms, provided the original work is properly cited and the use is non-commercial. See: <http://creativecommons.org/licenses/by-nc/4.0/>

© BMJ Publishing Group Ltd (unless otherwise stated in the text of the article) 2017. All rights reserved. No commercial use is permitted unless otherwise expressly granted.

## REFERENCES

- Xu HH, Werth VP, Parisi E, *et al*. Mucous membrane pemphigoid. *Dent Clin North Am* 2013;57:611–30.
- Chan LS, Ahmed AR, Anhalt GJ, *et al*. The first international consensus on mucous membrane pemphigoid: definition, diagnostic criteria, pathogenic factors, medical treatment, and prognostic indicators. *Arch Dermatol* 2002;138:370–9.
- Taniuchi K, Takata M, Matsui C, *et al*. Anti-epiligrin (laminin 5) cicatricial pemphigoid associated with an underlying gastric carcinoma producing laminin 5. *Br J Dermatol* 1999;140:696–700.
- Setterfield J, Shirlaw PJ, Lazarova Z, *et al*. Paraneoplastic cicatricial pemphigoid. *Br J Dermatol* 1999;141:127–31.
- Egan CA, Lazarova Z, Darling TN, *et al*. Anti-epiligrin cicatricial pemphigoid and relative risk for cancer. *Lancet* 2001;357:1850–1.
- Matsushima S, Horiguchi Y, Honda T, *et al*. A case of anti-epiligrin cicatricial pemphigoid associated with lung carcinoma and severe laryngeal stenosis: review of Japanese cases and evaluation of risk for internal malignancy. *J Dermatol* 2004;31:10–15.
- Sadler E, Lazarova Z, Sarasombath P, *et al*. A widening perspective regarding the relationship between anti-epiligrin cicatricial pemphigoid and cancer. *J Dermatol Sci* 2007;47:1–7.
- Bernard P, Antonicelli F, Bedane C, *et al*. Prevalence and clinical significance of anti-laminin 332 autoantibodies detected by a novel enzyme-linked immunosorbent assay in mucous membrane pemphigoid. *JAMA Dermatol* 2013;149:533–40.
- Bernard P, Vaillant L, Labeille B, *et al*. Incidence and distribution of subepidermal autoimmune bullous skin diseases in three French regions. Bullous Diseases French Study Group. *Arch Dermatol* 1995;131:48–52.
- Bertram F, Bröcker EB, Zillikens D, *et al*. Prospective analysis of the incidence of autoimmune bullous disorders in Lower Franconia, Germany. *J Dtsch Dermatol Ges* 2009;7:434–9.
- Taylor J, McMillan R, Shephard M, *et al*. World workshop on oral medicine VI: a systematic review of the treatment of mucous membrane pemphigoid. *Oral Surg Oral Med Oral Pathol Oral Radiol* 2015;120:161–71.
- Amber KT, Bloom R, Hertl M. A systematic review with pooled analysis of clinical presentation and immunodiagnostic testing in mucous membrane pemphigoid: association of anti-laminin-332 IgG with oropharyngeal involvement and the usefulness of ELISA. *J Eur Acad Dermatol Venereol* 2016;30:72–7.
- Cozzani E, Di Zenzo G, Calabresi V, *et al*. Autoantibody profile of a cohort of 78 Italian patients with mucous membrane pemphigoid: correlation between reactivity profile and clinical involvement. *Acta Derm Venereol* 2016;96:768–73.
- Fukuchi O, Suko A, Matsuzaki H, *et al*. Anti-laminin-332 mucous membrane pemphigoid with autoantibodies to  $\alpha 3$ ,  $\beta 3$  and  $\gamma 2$  subunits of laminin-332 as well as to BP230 and periplakin associated with adenocarcinoma from an unknown primary site. *J Dermatol* 2013;40:61–2.

## Learning points

- ▶ Mucous membrane pemphigoid (MMP) is a rare autoimmune bullous disease with diverse phenotypical expressions.
- ▶ The natural evolution of lesions may lead to irreversible scarring and a rapid diagnosis is crucial to prevent airway obstruction and blindness.
- ▶ Patients can be divided into 'low risk' (oral mucosa, skin) and 'high risk' (eye, anogenital, oesophagus, larynx), with a more aggressive medical management required for the latter.
- ▶ MMP can be a paraneoplastic manifestation, especially in the presence of autoantibodies directed against laminin 5, thus raising the issue of a systematic search for a neoplasm in such cases.
- ▶ A multidisciplinary (primary care physician, oral medicine expert, dermatologist, ophthalmologist, otolaryngologist, gastroenterologist, immunologist, oncologist, gynaecologist) medical follow-up is crucial for optimal management.

Copyright 2017 BMJ Publishing Group. All rights reserved. For permission to reuse any of this content visit <http://group.bmj.com/group/rights-licensing/permissions>.  
BMJ Case Report Fellows may re-use this article for personal use and teaching without any further permission.

Become a Fellow of BMJ Case Reports today and you can:

- ▶ Submit as many cases as you like
- ▶ Enjoy fast sympathetic peer review and rapid publication of accepted articles
- ▶ Access all the published articles
- ▶ Re-use any of the published material for personal use and teaching without further permission

For information on Institutional Fellowships contact [consortiasales@bmjgroup.com](mailto:consortiasales@bmjgroup.com)

Visit [casereports.bmj.com](http://casereports.bmj.com) for more articles like this and to become a Fellow