

Resistant hypertension after kidney transplantation

Roberta Callus,^{1,2} Maria Bugeja,¹ Lara Delicata,¹ Adrian Mizzi³

¹Department of Medicine, Mater Dei Hospital, Msida, Malta

²Faculty of Health and Science, Institute of Learning and Teaching University of Liverpool, Liverpool, UK

³Department of Radiology, Mater Dei Hospital, Msida, Malta

Correspondence to

Dr Roberta Callus, robertacallus@yahoo.co.uk

Accepted 5 May 2017

DESCRIPTION

A 50-year-old man with known hypertension, diabetes controlled on diet and end-stage kidney disease of unknown aetiology received a donor after brain death renal allograft from an extended criteria donor. There was initial delayed graft function, followed by a reduction in serum creatinine to a nadir of 115 $\mu\text{mol/L}$. Maintenance immunosuppression included tacrolimus, mycophenolic acid and corticosteroids.

Four months following transplantation, he presented with worsening blood pressure control and bilateral lower limb oedema. This occurred despite escalation of antihypertensive medication, which included a calcium channel blocker, loop diuretic, beta-blocker and alpha-blocker. Compliance to treatment was ensured. Ambulatory blood pressure monitoring recorded a mean blood pressure of 168/98 mm Hg with no nocturnal dipping. Serum creatinine at this stage was 130 $\mu\text{mol/L}$. On introduction of an ACE inhibitor, creatinine rose by approximately 30% to 179 $\mu\text{mol/L}$. A faint bruit was audible over the allograft. In view of this, CT renal angiography was performed (figure 1).

Percutaneous angioplasty and stenting was undertaken (figure 2). Serum creatinine fell to 120 $\mu\text{mol/L}$

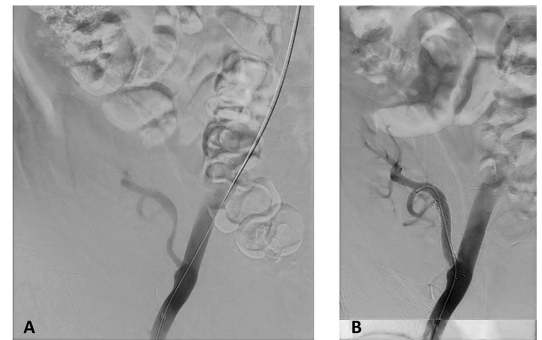


Figure 2 Transplant renal artery stenosis as visualised on angiography (A) was subsequently ballooned and stented successfully via a percutaneous approach through the right femoral artery (B).

after 6 months. Repeat ambulatory blood pressure monitoring gave a mean blood pressure reading of 130/85 mm Hg, although he continued on the same antihypertensive therapy.

Transplant renal artery stenosis (TRAS) is a recognised cause of post-transplant refractory hypertension, renal dysfunction and allograft loss. The reported incidence varies from 1% to 23%.^{1,2} Presentation most commonly occurs in the first 6 months following transplantation but may present at a later stage.¹ Hypertension and fluid retention secondary to activation of the renin-angiotensin-aldosterone system are characteristic findings. Prompt diagnosis is crucial since it is potentially curable.

Comorbidities associated with TRAS include diabetes mellitus, hypertension, hyperlipidaemia and smoking.³ Proposed causes include donor or recipient artery atheroma, arterial trauma during procurement or transplantation, different suture techniques with end-to-end anastomosis being more liable to error, immune-mediated vascular damage, prolonged cold ischaemia time and rarely extrinsic mechanical compression.¹ Cytomegalovirus infection and delayed graft function are considered to be risk factors.²⁻⁴

Duplex ultrasonography is a useful non-invasive screening tool for TRAS; however, it remains operator-dependent and transplant vessels may be difficult to visualise. Indeed, our patient was initially screened with Doppler ultrasound of the allograft; however, it was non-diagnostic in this case. More accurate tools for diagnosis include CT or magnetic resonance angiography.

Treatment includes conservative medical therapy, percutaneous transluminal angioplasty (PTA) or surgical therapy. In cases with uncontrolled hypertension, deteriorating renal function or worsening stenosis, revascularisation is advised.¹ PTA with stent

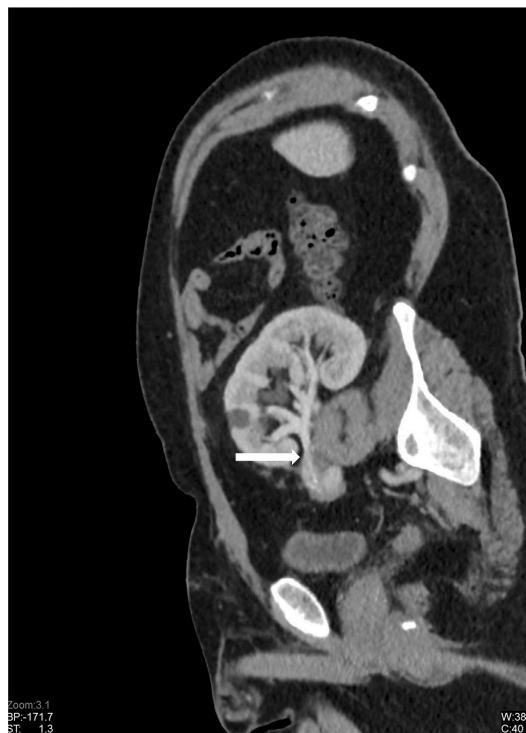

Figure 1 Multiplanar oblique reconstruction of the CT renal angiography confirmed a tight focal stenosis approximately 2.5 cm distal to the anastomosis of the transplant artery to the right external iliac artery (arrow).



CrossMark

To cite: Callus R, Bugeja M, Delicata L, et al. *BMJ Case Rep* Published Online First: [please include Day Month Year]. doi:10.1136/bcr-2017-220307

placement remains the treatment of choice despite no randomised trial comparing its efficiency and safety with other treatment options.^{1,2} Potential complications include renal artery dissection, stent restenosis, thromboembolism, haematoma, stent migration, pseudoaneurysms, nephrotoxicity and rarely allograft loss.³ Surgical correction is technically challenging and is considered a rescue therapy when PTA fails or if severe kinking is present.²

Learning points

- ▶ Transplant renal artery stenosis should be suspected in all patients with resistant hypertension following renal transplantation.
- ▶ Early recognition and prompt intervention in selected cases will lead to improved outcomes.
- ▶ Percutaneous transluminal angioplasty is the preferred treatment, but surgical correction may be required for technically challenging cases.

Contributors RC and MB contributed to the patient's work-up, diagnosis, management and write-up of the report. LD contributed to the literature review and write-up of the report. AM performed all radiological interventions, provided all radiological images and contributed to the write-up of the report.

Competing interests None declared.

Patient consent Obtained.

Provenance and peer review Not commissioned; externally peer reviewed.

© BMJ Publishing Group Ltd (unless otherwise stated in the text of the article) 2017. All rights reserved. No commercial use is permitted unless otherwise expressly granted.

REFERENCES

- 1 Chen W, Kayler LK, Zand MS, *et al.* Transplant renal artery stenosis: clinical manifestations, diagnosis and therapy. *Clin Kidney J* 2015;8:71–8.
- 2 Henning BF, Kuchlbauer S, Böger CA, *et al.* Percutaneous transluminal angioplasty as first-line treatment of transplant renal artery Stenosis. *Clin Nephrol* 2009;71:543–9.
- 3 Ngo AT, Markar SR, De Lijster MS, *et al.* A systematic review of outcomes following percutaneous transluminal angioplasty and stenting in the treatment of transplant renal artery Stenosis. *Cardiovasc Intervent Radiol* 2015;38:1573–88.
- 4 Audard V, Maignon M, Hemery F, *et al.* Risk factors and long-term outcome of transplant renal artery stenosis in adult recipients after treatment by percutaneous transluminal angioplasty. *Am J Transplant* 2006;6:95–9.

Copyright 2017 BMJ Publishing Group. All rights reserved. For permission to reuse any of this content visit <http://group.bmj.com/group/rights-licensing/permissions>.
BMJ Case Report Fellows may re-use this article for personal use and teaching without any further permission.

Become a Fellow of BMJ Case Reports today and you can:

- ▶ Submit as many cases as you like
- ▶ Enjoy fast sympathetic peer review and rapid publication of accepted articles
- ▶ Access all the published articles
- ▶ Re-use any of the published material for personal use and teaching without further permission

For information on Institutional Fellowships contact consortiasales@bmjgroup.com

Visit casereports.bmj.com for more articles like this and to become a Fellow