

Floppy eyelid syndrome: delayed diagnosis is not desired

Amar Pujari, Mandeep S Bajaj, Srikant Kumar Padhy, Divya Agarwal

Department of Ophthalmology,
Dr Rajendra Prasad Centre for
Ophthalmic Sciences, AIIMS,
New Delhi, Delhi, India

Correspondence to
Dr Amar Pujari,
dramarpujari@gmail.com

Accepted 23 February 2017

DESCRIPTION

A 52-year-old obese man presented with the history of redness, watering, photophobia and decreased vision in the left eye (hand movement close to face in the left eye and 20/40 in the right eye) for the past 6 months. History revealed that the patient had undergone surgical intervention twice for the left upper eyelid (surgical details not available) without successful outcome. Examination showed bilateral lax upper and lower eyelids, palpebral conjunctival congestion and papillary reaction (figure 1A–C). Right side cornea was normal, but left side cornea showed perforated central cornea with shallow anterior chamber along with normal corneal sensations. Ultrasonography of the left eye posterior segment was anechoic; therefore for the

left eye, the patient underwent glue application with bandage contact lens under topical anaesthesia followed by left-sided upper eyelid lateral tarsal strip under local anaesthesia in the same setting along with tightening of lower eyelid (figure 2A, B). At the end of 1 week, there was sufficient tightening of the eyelids after the removal of skin sutures (figure 3). Subsequently, the redundancy of the eyelid reduced without any eversion of the eyelid

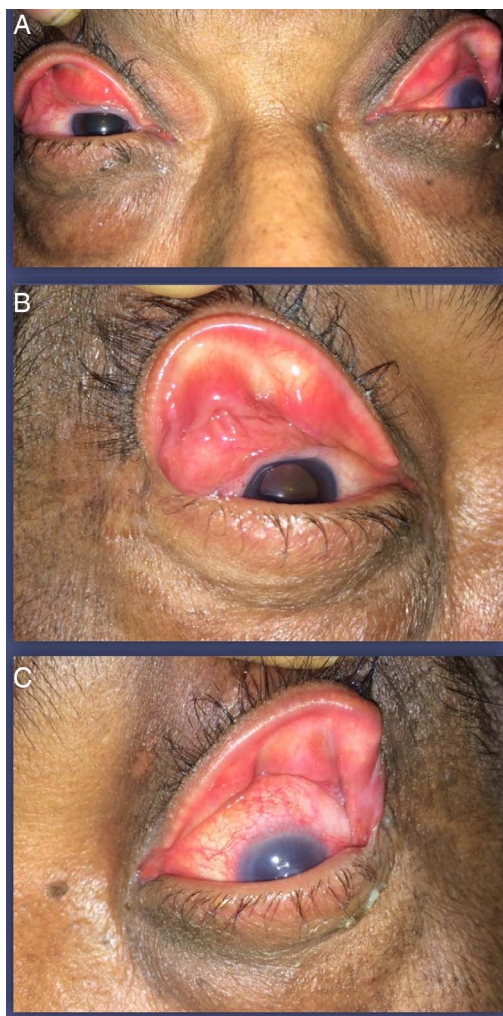


Figure 1 (A) Bilateral severe upper eyelid laxity. (B) Significant right upper eyelid laxity. (C) Significant left upper eyelid laxity along with the visible scar over the lateral part of the eyelid.

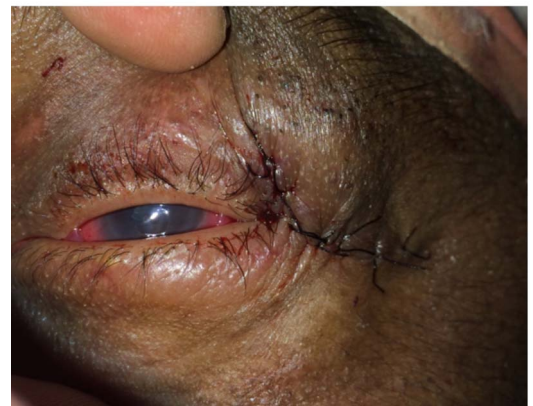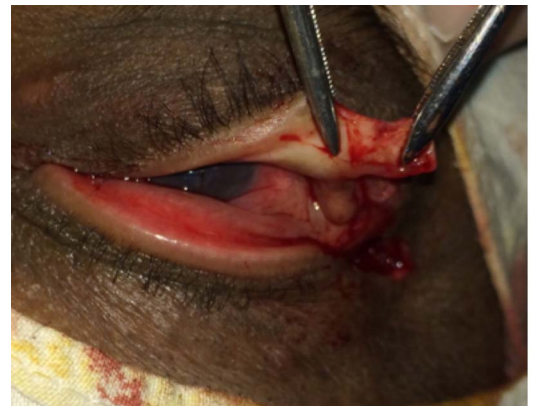


Figure 2 (A) Intraoperatively a strip of 5 mm was formed from the upper eyelid tarsus. (B) Intraoperative finding showing sufficient tightening of both eyelids.

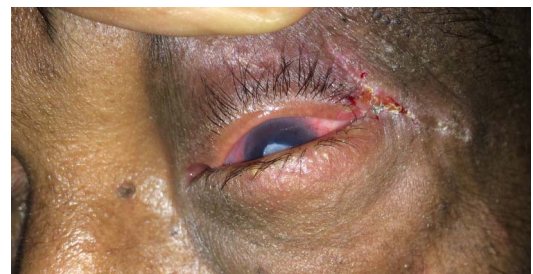

Figure 3 At the end of 1 week, both eyelids having significantly reduced laxity with well-formed lateral canthus.



To cite: Pujari A, Bajaj MS, Padhy SK, et al. *BMJ Case Rep* Published online: [please include Day Month Year] doi:10.1136/bcr-2017-219828

during sleep or on active pulling of the eyelid. The central perforation healed with formation of leucomatous corneal opacity for which a corneal procedure was planned later; similarly right eyelid horizontal shortening was performed after 6 weeks.

Floppy eyelid syndrome was first described by Culbertson and Osler in 1981. These cases are typically associated with middle-aged overweight male patients with obstructive sleep apnoea syndrome, and the eyelids show excessive laxity which could be easily everted on minimal traction. In patients with such scenario during sleep, the eyelids easily evert leading to exposure of the palpebral conjunctiva and irritation of the ocular surface leading to significant papillary conjunctivitis and corneal damage. Similarly, the history of lid eversion during sleep was present in this case too because of patient's preference to sleep more on the left side, which the patient changed after counselling. The exact pathogenesis is not known, but there is evidence that there was a quantitative decrease in elastin content within the tarsus along with laxity of medial and lateral canthal tendon. Treatment involves conservative measures in patients with minimal symptoms using ocular lubrication, night-time patching along with the measures to improvement systemic condition. Surgical intervention is indicated when the amount of lid laxity is significant leading to corneal complications, which can be corrected by either medial canthopexy combined with lateral tarsal strip or lateral tarsal strip alone.¹⁻³ As the previous surgical interventions were not beneficial, we performed a lateral tarsal strip procedure in this patient, which provided excellent visual and cosmetic outcomes.

Learning points

- ▶ The diagnosis of floppy eyelid syndrome can be easily missed, which may lead to delay in diagnosis and significant ocular surface complications.
- ▶ The learning point from the current case is to optimise clinical observation in diagnosing this condition at appropriate time and with the help of a simple technique using lateral tarsal strip excellent anatomical and cosmetic results can be obtained.

Contributors AP, MSB and SKP diagnosed this case and managed accordingly with acceptable results. After reviewing the literature and assessing the educational value, DA along with the above three authors wrote this report.

Competing interests None declared.

Patient consent Obtained.

Provenance and peer review Not commissioned; externally peer reviewed.

REFERENCES

- 1 Hashemi H, Rastad H, Emamian MH, *et al.* Floppy eyelid syndrome and its determinants in Iranian adults: a population-based study. *Eye Contact Lens* 2016.
- 2 Dhillon PS, Lewis G. Floppy eyelid syndrome. *BMJ Case Rep* 2015;2015.
- 3 Compton CJ, Melson AT, Clark JD, *et al.* Combined medial canthopexy and lateral tarsal strip for floppy eyelid syndrome. *Am J Otolaryngol* 2016;37:240-4.

Copyright 2017 BMJ Publishing Group. All rights reserved. For permission to reuse any of this content visit <http://group.bmj.com/group/rights-licensing/permissions>.
BMJ Case Report Fellows may re-use this article for personal use and teaching without any further permission.

Become a Fellow of BMJ Case Reports today and you can:

- ▶ Submit as many cases as you like
- ▶ Enjoy fast sympathetic peer review and rapid publication of accepted articles
- ▶ Access all the published articles
- ▶ Re-use any of the published material for personal use and teaching without further permission

For information on Institutional Fellowships contact consortiasales@bmjgroup.com

Visit casereports.bmj.com for more articles like this and to become a Fellow