

# Mechanical thrombectomy of embolised native aortic valve post-TAVI

John Joseph Coughlan,<sup>1</sup> Rob Fleck,<sup>2</sup> Cormac O'Connor,<sup>2</sup> Peter Crean<sup>2</sup>

<sup>1</sup>Department of Cardiology, University Hospital Limerick, Limerick, Ireland  
<sup>2</sup>St James Hospital, Dublin, Ireland

**Correspondence to**  
Dr John Joseph Coughlan,  
jjcoughl@gmail.com

Accepted 29 January 2017

## DESCRIPTION

A man aged 80 years with severe aortic stenosis underwent transcatheter aortic valve implantation (TAVI).

TAVI was performed using a 29 mm Edwards Sapien III valve. The valve was implanted directly, without predilation.

Immediately postvalve deployment, the patient became hypertensive and developed right-sided hemiplegia and aphasia.

The Prostar femoral closure device was used to close the femoral access site and the patient had an immediate CT brain, CT cerebral angiogram and stroke team consult.

CT cerebral angiogram demonstrated near total occlusion of the M2 segment of the left middle cerebral artery (figure 1).

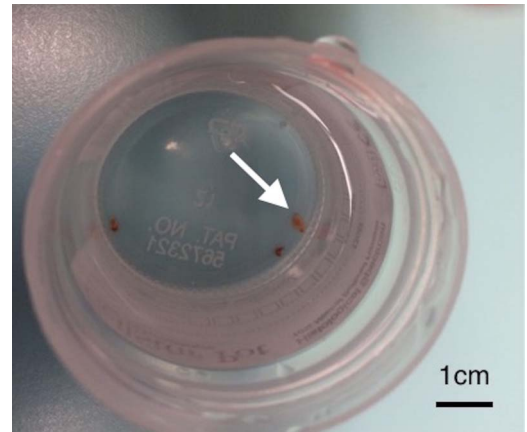
His National Institute of Health Stroke Score (NIHSS) was 19 indicating a severe stroke.

Our patient proceeded to mechanical thrombectomy for his left middle cerebral artery infarction.

Thrombolysis in cerebral infarction (TICI) flow prethrombectomy was 0. Four passes were made using the Trevo device and TICI flow post-thrombectomy was 3.

Material retrieved via the thrombectomy catheter is demonstrated in figure 2.

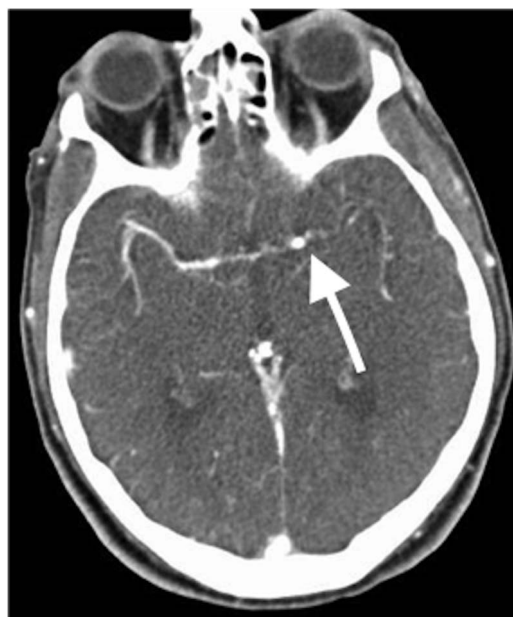Histological analysis confirmed this to be thrombus and a fragment of calcified aortic valve.



**Figure 2** Thrombus and a fragment of calcified aortic valve (arrowed) were retrieved via the thrombectomy catheter.

Post-thrombectomy, his NIHSS was 5 and he returned to our centre and underwent an uneventful postoperative recovery. On review in clinic 3 months postprocedure, he has regained full use of his arm and leg and only a mild intermittent expressive dysphasia persists.

This case demonstrates that mechanical thrombectomy is an effective means of treating this potentially devastating complication of TAVI.



**Figure 1** CT cerebral angiogram demonstrating near total occlusion of the M2 segment of the left middle cerebral artery (arrowed).

## Learning points

- ▶ Transcatheter aortic valve implantation (TAVI) is an increasingly used treatment modality for high and intermediate surgical risk patients with aortic stenosis.<sup>1 2</sup>
- ▶ Stroke is a potentially devastating complication of this procedure.<sup>3</sup>
- ▶ Mechanical thrombectomy is an effective means of treating embolic stroke during the TAVI procedure.

**Twitter** Follow John Coughlan @jjcoughl

**Contributors** JJC was primarily responsible for drafting the manuscript. COC, RF provided assistance with the drafting of the manuscript. PC provided guidance and editorial feedback on the manuscript.

**Competing interests** None declared.

**Patient consent** Obtained.

**Provenance and peer review** Not commissioned; externally peer reviewed.



**To cite:** Coughlan JJ, Fleck R, O'Connor C, et al. *BMJ Case Rep* Published online: [please include Day Month Year] doi:10.1136/bcr-2016-218787

## REFERENCES

- 1 Smith CR, Leon MB, Mack MJ, *et al.*, for the PARTNER Trial Investigators. Transcatheter versus surgical aortic-valve replacement in high-risk patients. *N Engl J Med* 2011;364:2187–98.
- 2 Leon MB, Smith CR, Mack MJ, *et al.*, for the PARTNER 2 Investigators. Transcatheter or surgical aortic-valve replacement in intermediate-risk patients. *N Engl J Med* 2016;374:1609–20.
- 3 Eggebrecht H, Schmermund A, Voigtländer T, *et al.* Risk of stroke after transcatheter aortic valve implantation (TAVI): a meta-analysis of 10,037 published patients. *EuroIntervention* 2012;8:129–38.

Copyright 2017 BMJ Publishing Group. All rights reserved. For permission to reuse any of this content visit <http://group.bmj.com/group/rights-licensing/permissions>.  
BMJ Case Report Fellows may re-use this article for personal use and teaching without any further permission.

Become a Fellow of BMJ Case Reports today and you can:

- ▶ Submit as many cases as you like
- ▶ Enjoy fast sympathetic peer review and rapid publication of accepted articles
- ▶ Access all the published articles
- ▶ Re-use any of the published material for personal use and teaching without further permission

For information on Institutional Fellowships contact [consortiasales@bmjgroup.com](mailto:consortiasales@bmjgroup.com)

Visit [casereports.bmj.com](http://casereports.bmj.com) for more articles like this and to become a Fellow