

Striae gravidarum leukaemia cutis: a rare manifestation of acute myeloid leukaemia

Mahmoud H Ayesh (Haj Yousef),¹ M Untaser M Omari,¹ Mo'ath M Rjoub,² Sohaib M Al-Khatib²

¹Department of Medicine, Jordan University of Science and Technology, Irbid, Jordan
²Department of Pathology, Jordan University of Science and Technology, Irbid, Jordan

Correspondence to

Dr Mahmoud H Ayesh (Haj Yousef), ayeshmahmoud@hotmail.com

Accepted 4 February 2017

DESCRIPTION

A multiparous woman aged 33 years presented to the haematology clinic with an abdominal skin rash and an abnormal full blood count. Physical examination revealed violaceous discolouration and hypertrophy of the striae gravidarum (SG) (figure 1A, B), sparing the surrounding skin. The patient denied taking steroids.

At the time of presentation, her white cell count was 66 000/mm³, her haemoglobin level was 6.7 g/dL and her platelet count was 32 000/mm³. A blood film revealed monoblasts and the bone marrow biopsy showed hypercellular bone marrow due to infiltration by sheets of immature cells (monoblasts and promonocytes). The monoblasts were folded nuclei, with delicate chromatin and occasional vacuolated cytoplasm. The promonocytes

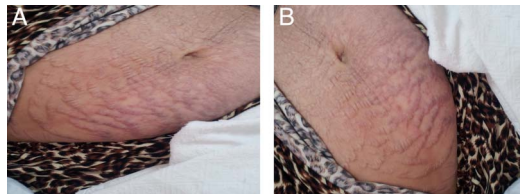


Figure 1 (A and B) Striae gravidarum hypertrophy with violaceous discolouration.

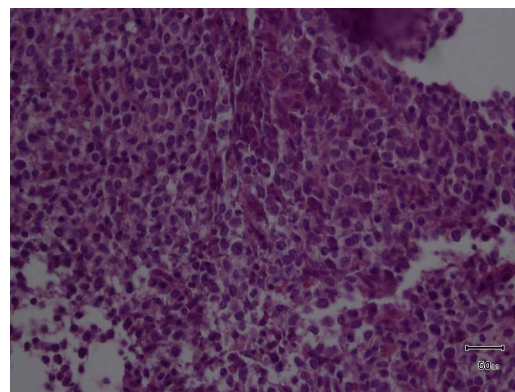


Figure 2 The marrow is hypercellular 100% due to infiltration by sheets of irregular twisted and widely spaced blasts. Normal haematopoietic elements are markedly decreased.

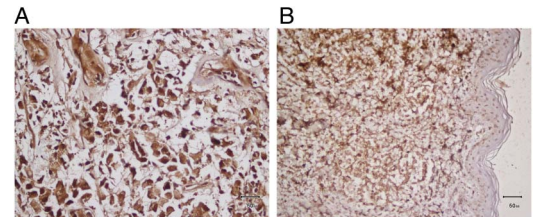


Figure 4 (A and B) The blasts are strongly immunoreactive for CD43 (A) and focally for MPO (B).

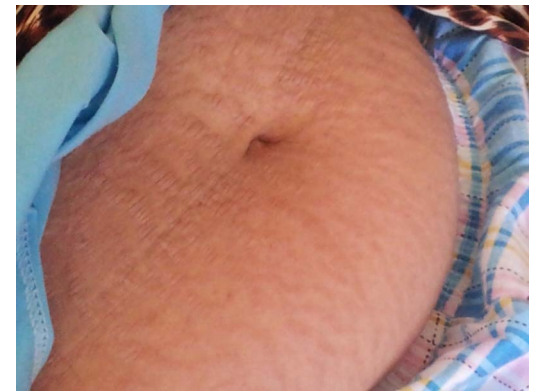

Figure 5 Striae gravidarum after the first course of induction chemotherapy with regression of the hypertrophy and disappearance of the violaceous colour.

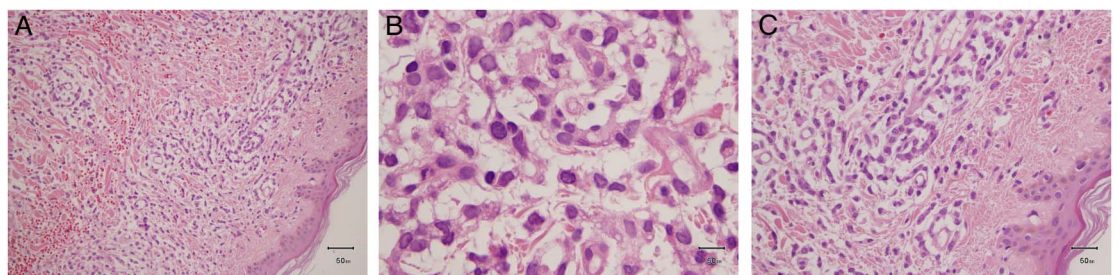


Figure 3 (A–C) The tumour infiltrates the dermis. The tumour composed of blasts having large occasionally cleaved nuclei, and dispersed chromatin.



To cite: Ayesh (Haj Yousef) MH, Omari MUM, Rjoub MM, *et al.* *BMJ Case Rep* Published online: [please include Day Month Year] doi:10.1136/bcr-2016-218428

were having less basophilic cytoplasm and occasionally granulated cytoplasm (figure 2). Flow cytometry analysis of a corresponding marrow sample revealed that ~66% of the cells were immature monocytes/monoblasts, which were positive for HLA-DR, CD33, CD15, CD64, CD13 and CD14. The karyotype was normal.

A diagnosis of acute myeloid leukaemia (AML) was considered; therefore, a skin punch biopsy was taken from the SG revealed heavily infiltrated dermis by sheets of immature mononuclear cells (blasts). Those immature cells were prominent nucleoli and clear chromatin. Admixed with the blasts is an eosinophilic precursor (figure 3A–C). Immunostaining showed that the blasts were strongly positive for CD43 and focally positive for MPO (figure 4A, B) consistent with the diagnosis of leukaemia cutis (LC).

Chemotherapy was initiated for AML, resulting in bone marrow remission and regression of the LC in the SG (figure 5). However, the patient died during the second cycle of induction chemotherapy due to Gram-negative sepsis.

LC is a rare form of extramedullary leukaemia involving the skin, diagnosed clinically by filtration of the epidermis, dermis or subcutis by leukaemia cells.¹

LC may appear at the time of diagnosis of systemic leukaemia or thereafter. Aleukaemic LC is a rare form leukaemia characterised by the infiltration of skin by leukaemia cells that occur prior to appearance in peripheral blood and bone marrow.²

SG are bands of atrophic skin that occur mainly on the abdomen related to pregnancy. SG LC has been rarely reported.³

Learning points

- ▶ Leukaemia cutis (LC) is a form of extramedullary leukaemia involving the skin and is associated with a poor prognosis.
- ▶ LC may present with wide range of cutaneous manifestations including striae gravidarum that may occur before, during or after the disease process.
- ▶ Punch skin biopsy should be performed in patients with acute myeloid leukaemia who develop suspicious skin lesion.

Contributors MHA (HY) was involved in writing the manuscript. MUMO was involved in patient care. SMA-K and MMR was involved in interpretation of skin histology. All the authors were involved in critical review of the manuscript.

Competing interests None declared.

Patient consent Obtained.

Provenance and peer review Not commissioned; externally peer reviewed.

REFERENCES

- 1 Bakst RL, Tallman MS, Douer D, *et al*. How I treat extramedullary acute myeloid leukemia. *Blood* 2011;3785–93.
- 2 Su WP. Clinical, histopathologic, and immunohistochemical correlations in leukemia cutis. *Semin Dermatol* 1994;13:223–2303.
- 3 Liu CI, Hsu CH. Leukaemia cutis at the site of striae distensae: an isotopic response? *Acta Derm Venereol* 2010;90:422–3.

Copyright 2017 BMJ Publishing Group. All rights reserved. For permission to reuse any of this content visit <http://group.bmj.com/group/rights-licensing/permissions>.
BMJ Case Report Fellows may re-use this article for personal use and teaching without any further permission.

Become a Fellow of BMJ Case Reports today and you can:

- ▶ Submit as many cases as you like
- ▶ Enjoy fast sympathetic peer review and rapid publication of accepted articles
- ▶ Access all the published articles
- ▶ Re-use any of the published material for personal use and teaching without further permission

For information on Institutional Fellowships contact consortiasales@bmjgroup.com

Visit casereports.bmj.com for more articles like this and to become a Fellow