

Correction

Bose A, Chandran J, Cherian R. Multiple lesions on CT brain scan: tuberculosis or neurocysticercosis? *BMJ Case Reports* 2009; doi:10.1136/bcr.06.2008.0155

During the publication process, *BMJ Case Reports* have inserted the wrong image into the article. The correct [figure 1](#) should be:

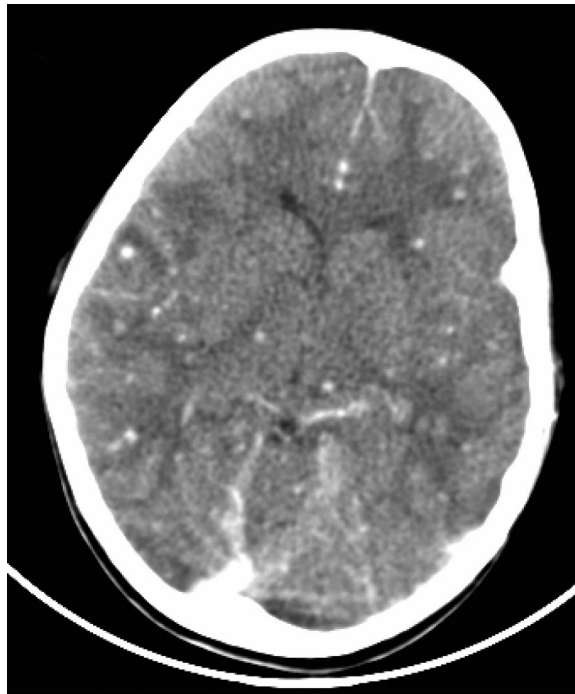


Figure 1 Contrast enhanced computed tomography (CT) brain scan showing numerous, subcentimetre, nodular enhancing lesions.

BMJ Case Rep 2016. doi:10.1136/bcr.06.2008.0155corr1

